Check for updates

Received: 8 September 2023 | Revised: 24 October 2023 | Accepted: 27 October 2023

DOI: 10.1002/ccr3.8248

CASE REPORT

Clinical Case Reports Open Access WILEY

A simple method for culturing *Acanthamoeba* from soft contact lens at a clinical laboratory of a hospital: Case report of *Acanthamoeba* keratitis

Toshihiko Matsuo[1,2] | **Motoko Nose**[3]

[1]Graduate School of Interdisciplinary Science and Engineering in Health Systems, Okayama University, Okayama City, Japan

[2]Department of Ophthalmology, Okayama University Hospital, Okayama City, Japan

[3]Department of Clinical Laboratory, Okayama University Hospital, Okayama City, Japan

Correspondence
Toshihiko Matsuo, Regenerative and Reconstructive Medicine (Ophthalmology), Graduate School of Interdisciplinary Science and Engineering in Health Systems, Okayama University, Shikata-cho 2-5-1, Okayama City 700-8558, Japan.
Email: matsuot@cc.okayama-u.ac.jp

Key Clinical Message

A simple culturing method for *Acanthamoeba* available at a clinical laboratory is a key for making timely diagnosis and starting treatment with topical 0.02% chlorhexidine gluconate eye drops, together with 0.1% miconazole or fluconazole eye drops.

Abstract

A 19-year-old woman with pain and injection in the right eye showed spotty corneal infiltration and radiating linear opacity. Suspicious of *Acanthamoeba* keratitis, corneal scraping, and the soft contact lens were sent to in-house clinical laboratory to culture successfully *Acanthamoeba* on Sabouraud dextrose agar plate painted with heat-treated dead bacilli.

KEYWORDS

Acanthamoeba keratitis, clinical laboratory, culture, Sabouraud dextrose agar plate, soft contact lens

1 | INTRODUCTION

The cornea which constitutes the ocular surface is a transparent tissue without blood vessels, in contrast to the conjunctiva with blood vessels. Trauma to the cornea is a main cause for corneal infection with bacteria, fungi, and amoebae.[1] Long-term use of corticosteroid eye drops would be a risk factor for developing corneal infection.[1] Among amoebae as pathogens in humans, *Entamoeba histolytica* is most well-known as a causative agent for amoebiasis or amebic dysentery. As a pathogen in the second place, corneal infection has been described to be caused by *Acanthamoeba* which is a free living single-cell organism or so-called parasite in water and soil.[2–5] *Acanthamoeba* has been also known to cause endophthalmitis[6] and encephalitis[7] via bloodstream infection.

Successful culture of *Acanthamoeba* is a key for making the timely diagnosis of *Acanthamoeba* keratitis.[8–10] In this study, we presented a patient with *Acanthamoeba* keratitis which was attributed to the use of a soft contact lens. The aim of this study is to review a culturing method for *Acanthamoeba* which can be done at a clinical laboratory with no special equipment in a hospital. We experienced this patient in the former half of the year 2009, and we feel that the number of *Acanthamoeba* keratitis in Japan has decreased or has become to be absent since then in the next decade of 2010s until now. In contrast, the growing number of the literature regarding *Acanthamoeba* keratitis has accumulated worldwide

This is an open access article under the terms of the Creative Commons Attribution-NonCommercial License, which permits use, distribution and reproduction in any medium, provided the original work is properly cited and is not used for commercial purposes.
© 2023 The Authors. *Clinical Case Reports* published by John Wiley & Sons Ltd.

even in the recent years. Under the circumstances, it would be worthwhile to report the simple and easy culturing method for *Acanthamoeba*.

2 | CASE REPORT

A 19-year-old woman had pain and injection in the right eye and visited a local eye doctor. She was given 0.5% levofloxacin eye drop four times daily without effect and was thus referred to Okayama University Hospital. At the initial visit of the referral, the best-corrected visual acuity in decimals was 0.06 in the right eye and 1.5 in the left eye. She used monthly renewed soft contact lenses (Menicon, Nagoya, Japan). The bulbar conjunctiva in the right eye was markedly injected (Figure 1A) and the cornea had two spotty opaque lesions with fluorescein stain at 9 o'clock and 11 o'clock meridian (Figure 1C,D) in association with linear opacity (Figure 1B) probably along branches of the trigeminal nerve. The cornea in the left eye was clear. Neither keratic precipitates nor aqueous cells were found in both eyes. The fundus examinations in both eyes detected no particular findings. Physical examinations also revealed no particular findings. Blood screening tests were all in the normal range and serological tests for syphilis were negative. She had no current medication and no past history including ocular trauma. There was nothing to be noted in family history.

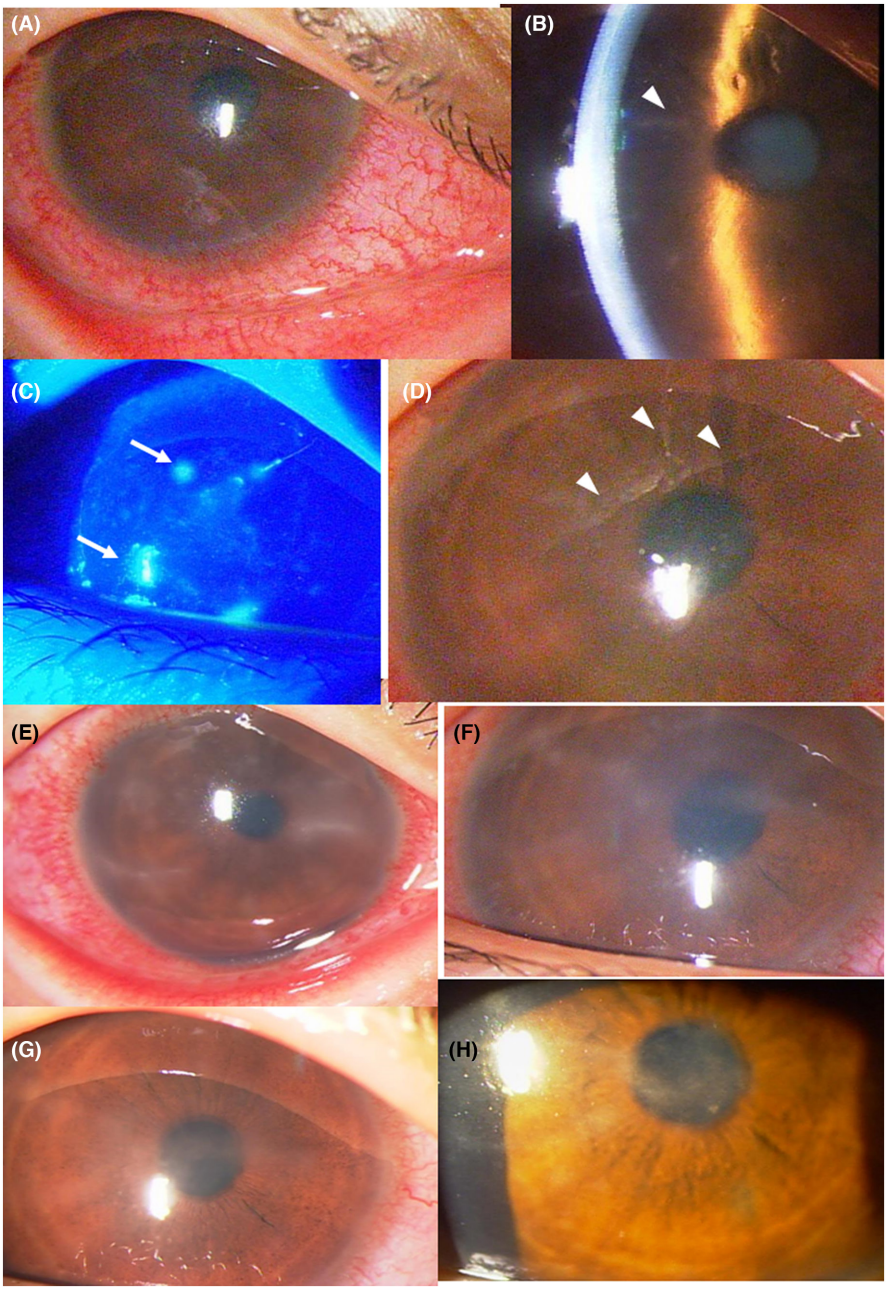

FIGURE 1 Slit-lamp images on the right eye. (A–D), at initial visit, showing marked bulbar conjunctival injection (A), horizontal linear opacity by slit lamp (arrowhead in B), surface ulcers stained by fluorescein (arrows in C), and radiating star-figured opacity (arrowheads in D: a magnified image of A). (E) 4 days after initial visit, showing apparent linear opacities with marked ciliary injection. (F) 2 weeks after initial visit, showing the decreasing opacity. (G) 3 weeks after initial visit, showing the residual opacity. (H) 2 months after initial visit, showing the residual opacity. A bright spot at the corneal center in A, D–G and at the corneal periphery in H is an artifact caused by the reflection of light source.

20500904, 2023, 11, Downloaded from https://onlinelibrary.wiley.com/doi/10.1002/ccr3.8248 by Okayama University, Wiley Online Library on [23/11/2023]. See the Terms and Conditions (https://onlinelibrary.wiley.com/terms-and-conditions) on Wiley Online Library for rules of use; OA articles are governed by the applicable Creative Commons License

With a clinical diagnosis of *Acanthamoeba* keratitis, corneal surface scraping was sent to a clinical laboratory to detect amoeboid cyst-like structure with Giemsa stain. The patient was hospitalized for intensive treatment: intravenous miconazole 200 mg daily for 2 days which was then switched to intravenous fosfluconazole 400 mg daily for 7 days; seven times daily topical administration of 0.1% fluconazole (injection solution), 0.1% miconazole (10 times saline-diluted injection solution), and 0.02% chlorhexidine gluconate for mucosal disinfection. In a few days, she became less painful but had persistent ciliary injection in the right eye (Figure 1E). In a week from the initial visit, *Acanthamoeba* was cultured from the soft contact lens (Figure 2) and topical administration was limited to 0.1% miconazole every 2 h and 0.02% chlorhexidine gluconate every 1 h. In 2 weeks from the initial visit, the corneal opacity became less apparent (Figure 2F) and the best-corrected visual acuity was 0.2 in the right eye. She had no eye pain. In 3 weeks from the initial visit, the corneal opacity almost subsided (Figure 2G) and the best-corrected visual acuity was 0.7 in the right eye. She used only 0.02% chlorhexidine gluconate every 1 h and discontinued topical 0.1% miconazole. In 4 weeks from the initial visit, the best-corrected visual acuity was 0.9 in the right eye and she used 0.02% chlorhexidine gluconate every 2 h. In 2 months from the initial visit, she showed residual corneal opacity (Figure 1H). She continued 0.02% chlorhexidine gluconate four times daily until the last visit in 4 months from the initial visit when the best-corrected visual acuity was 1.5 in the right eye.

3 | DISCUSSION

Tap water has been known as the source of *Acanthamoeba* which develops corneal infection.

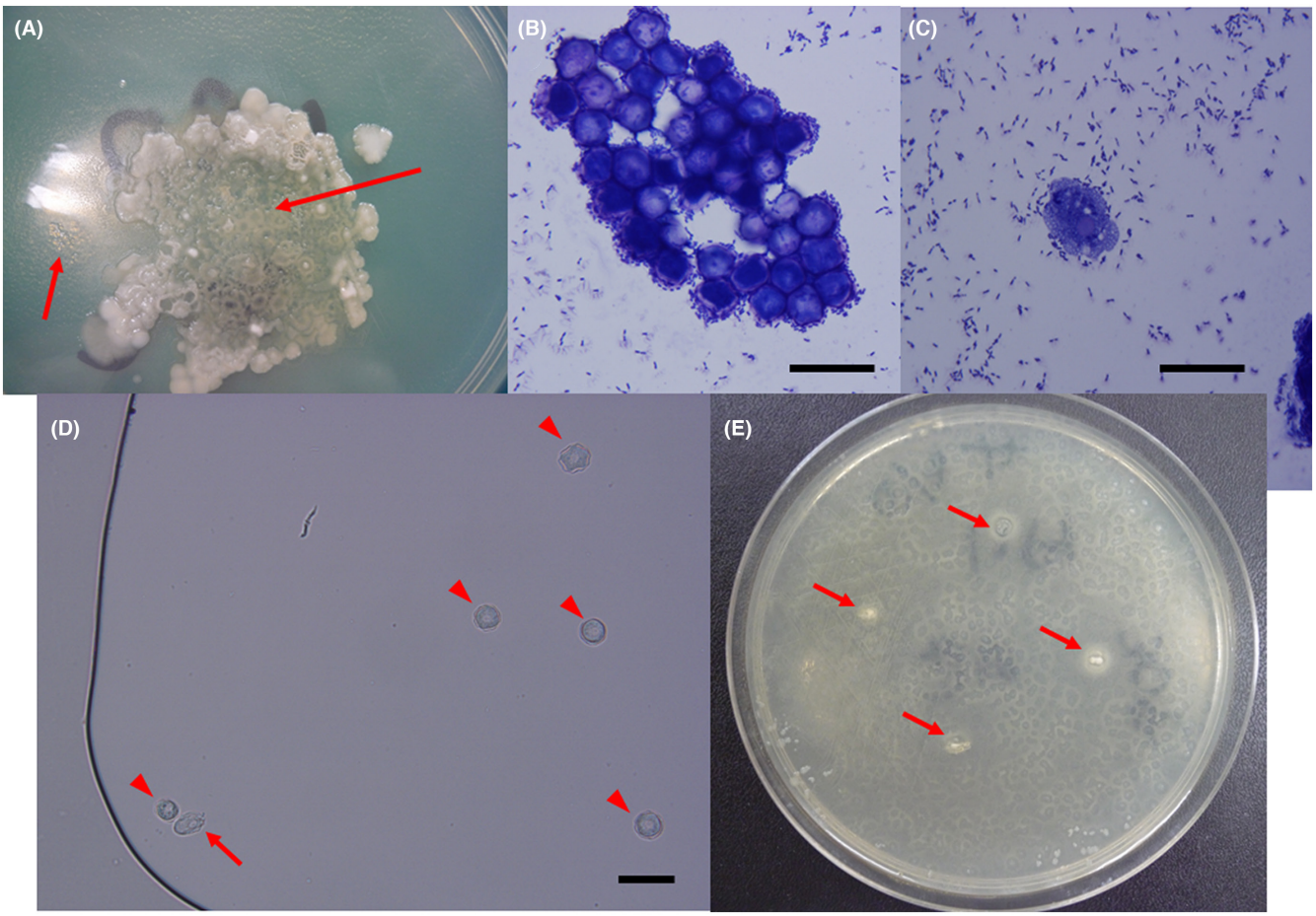

FIGURE 2 Culturing method for *Acanthamoeba*. (A) Translucent plaques (arrows) at the edge of bacterial white plaques as well as the inside after incubation for 4 days at 30°C on Sabouraud dextrose agar plate painted with heat-treated (at 60°C for 15 min) *Escherichia coli*. Saline washed with the contact lens was inoculated at the center of the dish. Parallel incubation at 23°C resulted in less growth while incubation at 37°C resulted in no growth. (B and C), cysts (B) and trophozoite (C) by Giemsa stain (×1000) in the background of dead bacilli (*E. coli*). (D) Cysts (arrowheads) and trophozoite (arrow) dispersed in saline (×400). (E) Many plaques of cysts in second isolation culture after incubation for 3 days at 30°C on Sabouraud dextrose agar plate painted with heat-treated *E. coli*. Arrows indicate sites of inoculation of the initial plaques (E). Bar = 20 μm in B, C, and D.

20500904, 2023, 11, Downloaded from https://onlinelibrary.wiley.com/doi/10.1002/ccr3.8248 by Okayama University, Wiley Online Library on [23/11/2023]. See the Terms and Conditions (https://onlinelibrary.wiley.com/terms-and-conditions) on Wiley Online Library for rules of use; OA articles are governed by the applicable Creative Commons License

Outbreak of *Acanthamoeba* keratitis was related with tap water contamination.[11–15] In Japan, residual chlorine concentration of the tap water has been set at 0.1 mg/L, based on the Water Supply Act which was enacted in 1957. Since then, no change has been made according to the Waterworks Bureau of Okayama City Government. The increase in the number of reports for *Acanthamoeba* keratitis in 1990s to 2000s would be related with increased use of soft contact lenses in Japan. In those years, the main type of soft contact lenses was repeated use for 1 month or 2 weeks. In addition, disinfectant solution for soft contact lenses commercially available was not effective to kill *Acanthamoeba*.[10,16] In contrast, the presumed decrease of *Acanthamoeba* keratitis in 2010s up until now would be attributed to the predominance of one-day disposable soft contact lenses in the market. *Acanthamoeba* keratitis is still in association with the use of contact lenses in other countries.[17] As shown in tap water contamination with *Legionella* species,[12,13] *Acanthamoeba* species play a role as a carrier of bacteria.[10] The intracellular endosymbiosis of bacteria in *Acanthamoeba* species would be an underlying factor for the aggressive nature of infection in the cornea.[18]

The main strategy for treatment of *Acanthamoeba* keratitis is to use topical 0.02% or 0.05% chlorhexidine gluconate which is approved as a mucosal disinfectant in Japan.[19] Frequent topical application of 0.02% or 0.05% chlorhexidine gluconate as eye drops every 1 h would not cause irritant symptoms or signs on the ocular surface. Topical administration of antifungals such as miconazole or fluconazole at the concentration of 0.1% which is prepared from the injection solution are usually combined in parallel with topical 0.02% or 0.05% chlorhexidine gluconate to expect a better therapeutic effect.[19,20]

A key point in culturing *Acanthamoeba* in this study was to paint heat-treated dead bacteria *Escherichia coli* on the surface of Sabouraud dextrose agar plate for fungal culture (Figure 2), based on the fact that *Acanthamoeba* ingests bacteria as food. In the first culture, plaques of *Acanthamoeba* were observed together with bacterial plaques (Figure 2A) which were derived from the soft contact lens. From this first culture, plaques of *Acanthamoeba* were picked up and inoculated on the second plate for isolation culture (Figure 2E). The sequence of culturing procedures can be done with no special equipment at a clinical laboratory. *Acanthamoeba* cysts and trophozoites can be observed with Giemsa stain (Figure 2B,C) or in unstained natural condition (Figure 2D). Giemsa stain is known to be better detecting the cysts than the trophozoites. The temperature of the incubation at 30°C appeared to be best for the growth of *Acanthamoeba* in culture. We simply chose Sabouraud dextrose agar plate to prepare the pre-killed bacterial lawn since the plate is for the fungal culture. A previous study used the non-nutrient agar plate as well as the Sabouraud dextrose agar plate.[10]

In summary, *Acanthamoeba* keratitis is an example where delayed diagnosis, topical corticosteroid use, topical treatment for herpes simplex virus keratitis prior to anti-amoebic therapy have been linked to inflammatory complications and adverse outcomes including devastating results which might lead to the extirpation of eye ball.[3,20] To avoid such adverse events, challenging culture of *Acanthamoeba* must be accomplished and timely diagnosis of *Acanthamoeba* keratitis is made. The culturing method for *Acanthamoeba*, as shown in this study, would aid in reaching the timely diagnosis, and hence, in starting the timely topical treatment.

AUTHOR CONTRIBUTIONS

Toshihiko Matsuo: Conceptualization; data curation; formal analysis; investigation; validation; visualization; writing – original draft. **Motoko Nose:** Data curation; investigation; methodology; resources; writing – review and editing.

FUNDING INFORMATION

The authors receive no financial support for the research, authorship, and/or publication of this article.

CONFLICT OF INTEREST STATEMENT

The authors declare no potential conflicts of interest with respect to the research, authorship, and/or publication of this article.

DATA AVAILABILITY STATEMENT

Additional data are available upon reasonable request to the corresponding author.

ETHICS STATEMENT

Ethics committee review was not applicable due to the case report design, based on the Ethical Guidelines for Medical and Health Research Involving Human Subjects, issued by the Government of Japan.

CONSENT

Written consent was obtained from the patient for her anonymized information to be published in this article.

ORCID

Toshihiko Matsuo https://orcid.org/0000-0001-6570-0030

20500904, 2023, 11, Downloaded from https://onlinelibrary.wiley.com/doi/10.1002/ccr3.8248 by Okayama University, Wiley Online Library on [23/11/2023]. See the Terms and Conditions (https://onlinelibrary.wiley.com/terms-and-conditions) on Wiley Online Library for rules of use; OA articles are governed by the applicable Creative Commons License

REFERENCES

1. Cabrera-Aguas M, Khoo P, Watson SL. Infectious keratitis: a review. *Clin Exp Ophthalmol*. 2022;50:543-562.
2. Lorenzo-Morales J, Khan NA, Walochnik J. An update on *Acanthamoeba* keratitis: diagnosis, pathogenesis and treatment. *Parasite*. 2015;22:10.
3. Rayamajhee WMDP, Henriquez FL, Petsoglou C, Carnt N. *Acanthamoeba* keratitis: an increasingly common infectious disease of the cornea. *Lancet Microbe*. 2021;2:e345-e346.
4. Fanselow N, Sirajuddin N, Yin XT, Huang AJW, Stuart PM. *Acanthamoeba* keratitis, pathology, diagnosis and treatment. *Pathogens*. 2021;10:323.
5. Kaufman AR, Tu EY. Advances in the management of *Acanthamoeba* keratitis: a review of the literature and synthesized algorithmic approach. *Ocul Surf*. 2022;25:26-36.
6. Matsuo T, Notohara K, Shiraga F, Yumiyama S. Endogenous amoebic endophthalmitis. *Arch Ophthalmol*. 2001;119:125-128.
7. Hara T, Yagita K, Sugita Y. Pathogenic free-living amoebic encephalitis in Japan. *Neuropathology*. 2019;39:251-258.
8. Yera H, Ok V, Kuet FLK, et al. PCR and culture for diagnosis of *Acanthamoeba* keratitis. *Br J Ophthalmol*. 2021;105:1302-1306.
9. Wankhade AB, Patro P, Mishra N, Das P. Successful culture of *Acanthamoeba* remains a key towards diagnosis of unusual clinical presentation of keratitis: a first case report from Chhattisgarh. *J Family Med Prim Care*. 2021;10:3904-3907.
10. Rayamajhee B, Sharma S, Willcox M, et al. Assessment of genotypes, endosymbionts and clinical characteristics of *Acanthamoeba* recovered from ocular infection. *BMC Infect Dis*. 2022;22:757.
11. Kilvington S, Gray T, Dart J, et al. *Acanthamoeba* keratitis: the role of domestic tap water contamination in the United Kingdom. *Invest Ophthalmol Vis Sci*. 2004;45:165-169.
12. Magnet A, Peralta RHS, Gomes TS, et al. Vectorial role of *Acanthamoeba* in legionella propagation in water for human use. *Sci Total Environ*. 2015;505:889-895.
13. Gomes TS, Vaccaro L, Magnet A, et al. Presence and interaction of free-living amoebae and amoeba-resisting bacteria in water from drinking water treatment plants. *Sci Total Environ*. 2020;719:137080.
14. Carnt NA, Subedi D, Connor S, Kilvington S. The relationship between environmental sources and the susceptibility of *Acanthamoeba* keratitis in the United Kingdom. *PloS One*. 2020;15:e0229681.
15. Rayamajhee B, Subedi D, Won S, et al. Investigating domestic shower settings as a risk factor for *Acanthamoeba* keratitis. *Water*. 2020;12:3493.
16. Kobayashi T, Gibbon L, Mito T, Shiraishi A, Uno T, Ohashi Y. Efficacy of commercial soft contact lens disinfectant solutions against *Acanthamoeba*. *Jpn J Ophthalmol*. 2011;55:547-557.
17. Li w, Wang Z, Qu J, Zhang Y, Sun X. *Acanthamoeba* keratitis related to contact lens use in a tertiary hospital in China. *BMC Ophthalmol*. 2019;19:202.
18. Rayamajhee B, Willcox MDP, Henriquez FL, Petsoglou C, Subedi D, Carnt N. *Acanthamoeba*, an environmental phagocyte enhancing survival and transmission of human pathogens. *Trends Parasitol*. 2022;38:975-990.
19. Yamazoe K, Yamamoto Y, Shimazaki-Den S, Shimazaki J. Visual outcome in Japanese patients with *Acanthamoeba* keratitis. *Eye*. 2012;26:517-522.
20. Shing B, Balen M, McKerrow JH, Debnath A. *Acanthamoeba* Keratitis: an update on amebicidal and cysticidal drug screening methodologies and potential treatment with azole drugs. *Expert Rev Anti-Infect Ther*. 2021;19:1427-1441.

How to cite this article: Matsuo T, Nose M. A simple method for culturing *Acanthamoeba* from soft contact lens at a clinical laboratory of a hospital: Case report of *Acanthamoeba* keratitis. *Clin Case Rep*. 2023;11:e8248. doi:10.1002/ccr3.8248

20500904, 2023, 11, Downloaded from https://onlinelibrary.wiley.com/doi/10.1002/ccr3.8248 by Okayama University, Wiley Online Library on [23/11/2023]. See the Terms and Conditions (https://onlinelibrary.wiley.com/terms-and-conditions) on Wiley Online Library for rules of use; OA articles are governed by the applicable Creative Commons License