

## BRIEF COMMUNICATION

# Novel animal model of combined generalized and focal epilepsy

Iori Ohmori<sup>1,2</sup>  | Mamoru Ouchida<sup>3</sup> | Masakazu Shinohara<sup>4,5</sup> | Kiyoka Kobayashi<sup>6</sup> | Saeko Ishida<sup>7</sup> | Tomoji Mashimo<sup>7</sup>

<sup>1</sup>Section of Developmental Physiology and Pathology, Faculty of Education, Okayama University, Okayama, Japan

<sup>2</sup>Department of Child Neurology, Graduate School of Medicine, Dentistry, and Pharmaceutical Sciences, Okayama University, Okayama, Japan

<sup>3</sup>Department of Molecular Oncology, Graduate School of Medicine, Dentistry, and Pharmaceutical Sciences, Okayama University, Okayama, Japan

<sup>4</sup>Division of Epidemiology, Kobe University Graduate School of Medicine, Kobe, Japan

<sup>5</sup>Integrated Center for Mass Spectrometry, Kobe University Graduate School of Medicine, Kobe, Japan

<sup>6</sup>Otsuka Pharmaceutical, Tokushima, Japan

<sup>7</sup>Division of Animal Genetics, Laboratory Animal Research Center, Institute of Medical Science, University of Tokyo, Tokyo, Japan

## Correspondence

Iori Ohmori, Section of Developmental Physiology and Pathology, Faculty of Education, Okayama University, Tsushima 3-chome 1-1, Kita-ku, Okayama 700-8530, Japan.  
Email: [iori@md.okayama-u.ac.jp](mailto:iori@md.okayama-u.ac.jp)

## Funding information

This work was supported by Grants-in-Aid for Scientific Research (16H05354), and Grant-in-Aid for epilepsy research from the Japan Epilepsy Research Foundation, JSPS KAKENHI (JP16H06276; AdAMS).

## Abstract

Thioredoxin, encoded by *Txn1*, is a critical antioxidant that protects against oxidative damage by regulating the dithiol/disulfide balance of interacting proteins. We recently discovered the *Adem* rat, an epileptic rat harboring the *Txn1*-F54L mutation, characterized by wild running and vacuolar degeneration in the midbrain. This study aimed to characterize the classification of epilepsy in *Adem* rats. We performed simultaneous video-electroencephalographic recordings, magnetic resonance imaging, neurotransmitter measurements using gas chromatography–mass spectrometry (GC-MS), and immunohistochemistry. *Adem* rats exhibited absence, tonic, and focal seizures. The type of epilepsy was classified as combined generalized and focal epilepsy. Neurotransmitters in the midbrain and cortex were measured at 3 weeks of age, when neuronal cell death occurs in the midbrain. The results of GC-MS ruled out the dominance of the excitatory system in the midbrain and cortex of *Adem* rats. Activation of astrocytes and microglia was more pronounced at 5 weeks of age, at which time epileptic seizures occurred frequently. The underlying pathology in *Adem* rats remains unknown. However, glial cell activation and inflammation may play a significant role in the occurrence of epilepsy.

## KEYWORDS

animal model, combined generalized and focal epilepsy, oxidative stress, thioredoxin

This is an open access article under the terms of the [Creative Commons Attribution-NonCommercial-NoDerivs](https://creativecommons.org/licenses/by-nc-nd/4.0/) License, which permits use and distribution in any medium, provided the original work is properly cited, the use is non-commercial and no modifications or adaptations are made.

© 2022 The Authors. *Epilepsia* published by Wiley Periodicals LLC on behalf of International League Against Epilepsy.

## 1 | INTRODUCTION

There is a long history of using rodents as models for epilepsy, with epileptiform activity produced using chemicals such as pilocarpine, kainic acid, pentylenetetrazol, and tetrodotoxin, and by electrical stimulation of brain regions.<sup>1,2</sup> The number of genetically modified animals with mutations in human epilepsy-related genes has grown with the ongoing development of genetic technologies<sup>3,4</sup>; the models have been classified as either generalized or focal epilepsy.<sup>1</sup> However, no animal model of combined generalized and focal epilepsy has been reported to date.

Wild running and tonic/tonic-clonic seizures following wild running are known as audiogenic seizures, which can be evoked in genetically susceptible rodents by intense sound stimulation or induced in normal rodents by repeated stimulation of auditory nuclei.<sup>5</sup> We recently discovered a *Txn1* mutant rat with wild running by using forward genetic screening in an archive of ethyl nitrosourea-mutated rats.<sup>6</sup> This rat strain, named *Adem* (age-dependent mitochondrial cytopathy), develops wild running spontaneously without auditory stimulation. Thioredoxin, encoded by the *Txn1* gene, plays an essential role in defense against oxidative stress by reacting with thioredoxin reductase 1 (*Txnrd1*) and peroxiredoxin 1.<sup>7</sup> *Adem* rats were found to have a midbrain lesion affecting the inferior colliculus, superior colliculus, and thalamus, where neuronal cell death was induced by excessive oxidative stress at 3 weeks of age.<sup>6</sup> Frequent episodes of wild running started at 5 weeks of age.<sup>6</sup> The aim of this study was to clarify the epileptic seizure type of wild running associated with the midbrain lesion. We hypothesized that epilepsy is caused by an imbalance of the excitatory and inhibitory nervous systems in the midbrain.

## 2 | MATERIALS AND METHODS

Additional details of the methods are described in Appendix S1.

### 2.1 | Animals

We used both sexes of *Adem* rats in this study, because there were no differences in the occurrence of wild running between sexes.<sup>6</sup> Although *Txn1*<sup>F54L/F54</sup> (homozygous) rats exhibited more severe vacuolar degeneration in the midbrain than *Txn1*<sup>F54L/+</sup> (heterozygous) rats, both genotypes showed a similar seizure frequency at 5 weeks.<sup>6</sup> In this study, we used both *Txn1*<sup>F54L/+</sup> and *Txn1*<sup>F54L/F54L</sup> rats for electroencephalographic (EEG) analysis.

### 2.2 | Magnetic resonance imaging

*Txn1*<sup>F54L/F54L</sup> ( $n = 2$ ) and wild-type (WT;  $n = 2$ ) rats were examined at 3 weeks of age by using a 4.7-T preclinical magnetic resonance scanner (BioSpec 47/16 USR, Bruker BioSpin MRI) as described in our previous study.<sup>6</sup>

### 2.3 | Video-EEG simultaneous recordings

Stainless steel screw electrodes were implanted into the bilateral frontal cortex and occipital cortex under isoflurane inhalation. A reference electrode was implanted at the posterior end of the skull. Five- to 7-week-old rats (*Txn1*<sup>F54L/+</sup>,  $n = 4-5$ ; *Txn1*<sup>F54L/F54L</sup>,  $n = 4-5$ , and WT,  $n = 2$ ) were tethered, and video-EEG was recorded for 8–9 h, from approximately 8:00 a.m. to 5:00 p.m., every week.

### 2.4 | Histology and immunohistochemistry

Brains were fixed with 10% formalin neutral buffer solution. Tissue sections were cut from paraffin-embedded brain samples for *Txn1*<sup>F54L/F54L</sup> and WT rats euthanized at 3, 5, and 9 weeks of age. Sections were subjected to hematoxylin and eosin (HE) staining using standard protocols. Brain tissue samples were stained using a standard immunohistochemistry (IHC) protocol as described previously.<sup>6</sup>

### 2.5 | Metabolome analysis by gas chromatography–mass spectrometry

Gas chromatography–mass spectrometry (GC-MS) analysis of the thalamus and cortex samples of WT and *Txn1*<sup>F54L/F54L</sup> rats (each group,  $n = 3$ ) at 3 weeks of age was conducted using a GCMS-QP2010 Ultra (Shimadzu Co) according to a previous report.<sup>8,9</sup> Metabolome analysis was performed at 3 weeks of age to minimize the impact of neurotransmitter metabolism in astrocytes, as the IHC results showed that significant activation of astrocytes occurs at 5 weeks of age.

### 2.6 | Statistical analysis

All data were analyzed using EZR.<sup>10</sup> Results are expressed as mean  $\pm$  SEM. One-way analysis of variance followed by Bonferroni adjustment was used to determine the statistical differences between the groups. Statistical significance was set at  $p < .05$ .

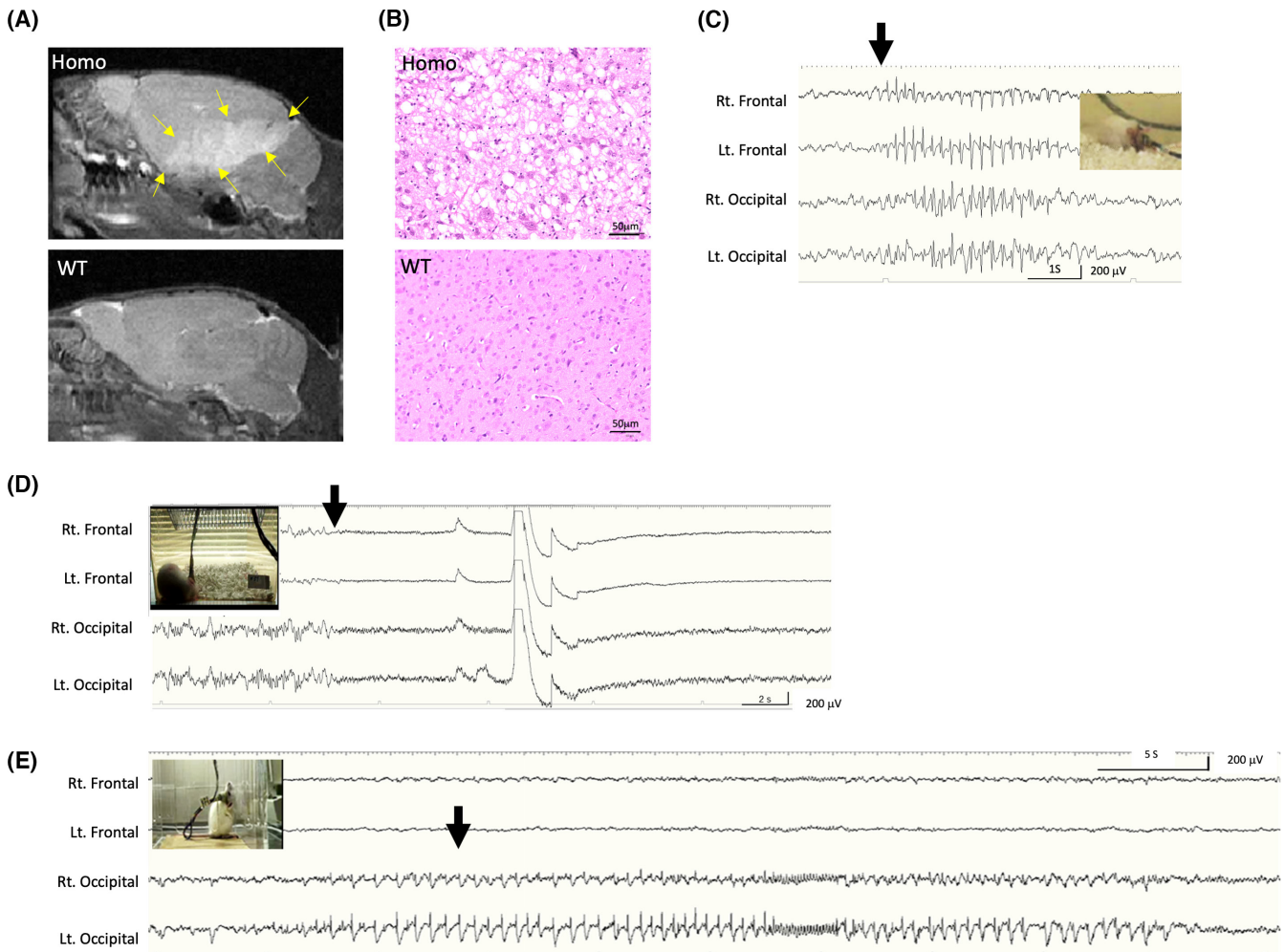
### 3 | RESULTS

Sagittal magnetic resonance imaging (MRI) sections showed high signals of T2-weighted images (T2WIs) including the inferior colliculus and thalamus (Figure 1A). These images were spread over 6–8-mm slices in  $Txn1^{F54L/F54L}$  and  $Txn1^{F54L/+}$  rats. The areas of high signal intensity on T2WIs correlated with vacuolar degeneration on HE staining (Figure 1B).

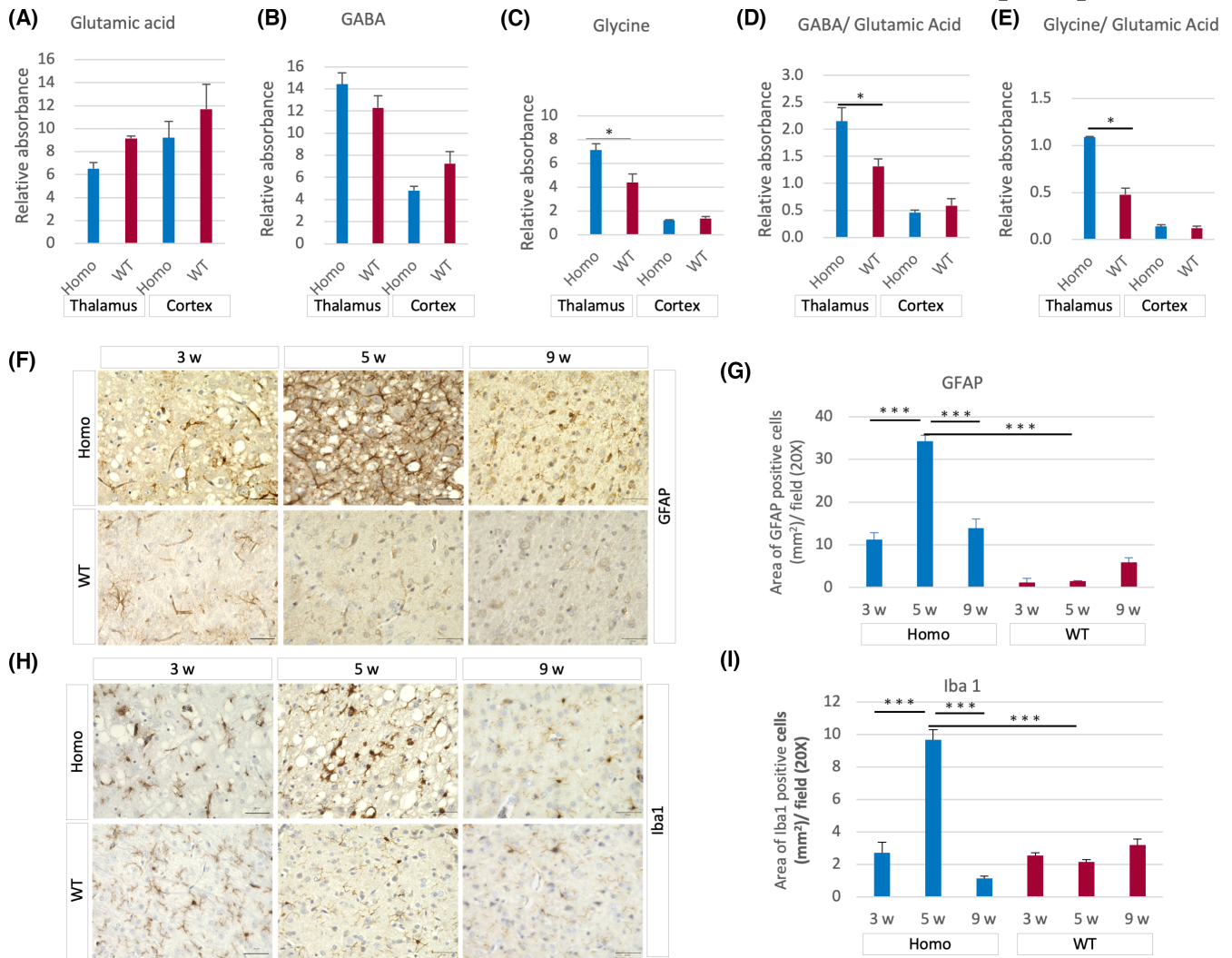
Unfortunately, wild running could not be captured by video-EEG recording. However, various types of epileptic seizures were detected. They comprised an absence seizure (Figure 1C, Video S1), an asymmetric brief toniclike

seizure (Figure 1D, Video S2), and a focal seizure originating from the occipital region (Figure 1E, Video S3). The frequency of each epileptic seizure is shown in Table S1. *Adem* rats are thus a model of combined generalized and focal epilepsy.

A possible cause of epilepsy is an imbalance between excitatory and inhibitory neurons arising from neuronal cell death. Therefore, we measured neurotransmitters in the thalamus and cortex without lesions using GC-MS. There were no statistically significant differences in glutamate (Figure 2A) and  $\gamma$ -aminobutyric acid (GABA; Figure 2B) levels. In contrast, glycine levels in the thalamus in  $Txn1^{F54L/F54L}$  rats were significantly higher than that of



**FIGURE 1** *Adem* rats represent a model of combined generalized and focal epilepsy. (A) Representative magnetic resonance image (MRI) of  $Txn1^{F54L/F54L}$  and wild-type (WT) rats at 3 weeks. The MRI shows the T2 high-signal-intensity lesion in the midbrain. Yellow arrows indicate the lesion. (B) Hematoxylin and eosin stain of  $Txn1^{F54L/F54L}$  and WT rats in the midbrain shows vacuolar degeneration in the midbrain. (C) An absence seizure in a  $Txn1^{F54L/F54L}$  rat. The rat suddenly stopped grooming (arrow point) and hung his head. The electroencephalographic (EEG) trace showed diffuse 6–7-Hz spike-and-wave bursts. When the epileptic seizures on the EEG disappeared, he began to move. (D) An asymmetric toniclike seizure in a  $Txn1^{F54L/+}$  rat. Due to backlighting, seizure symptoms were somewhat blurred; the rat suddenly became tonic and turned his head to the left. The EEG trace became a diffuse low-voltage pattern at the point of his tonic posture. (E) A focal seizure in a  $Txn1^{F54L/+}$  rat. Spike-wave discharges appeared from the left occipital region, and epileptic discharges spread over to the right occipital region. The rat became restless and walked around in the cage at the point marked by the arrow. The rat became calm after the epileptic wave disappeared. Homo,  $Txn1^{F54L/F54L}$  rat; Lt., left; Rt., right.



**FIGURE 2** Astrocytes and microglia were activated during the epileptic period. (A–E) Gas chromatography-mass spectrometry analysis shows the relative absorbance of glutamic acid (A),  $\gamma$ -aminobutyric acid (GABA; B), glycine (C), GABA/glutamic acid (D), and glycine/ glutamic acid (E). The midbrain is dominated by the inhibitory system in comparison to the cerebral cortex. The ratio of the inhibitory/ excitatory system in the thalamus for  $Txn1^{F54L/F54L}$  rats was higher than that for wild type (WT). (F–I) Representative immunohistochemistry images of anti-gial fibrillary acidic protein (GFAP; F) and anti-ionized calcium-binding adapter molecule 1 (Iba1; H) for  $Txn1^{F54L/F54L}$  and WT rats at 3, 5, and 9 weeks of age. (G, I) Quantification of GFAP-positive cells (G) and Iba1-positive cells (I). Both of peaks occurred in rats at 5 weeks of age. Homo,  $Txn1^{F54L/F54L}$  rat. Scale bars = 50  $\mu$ m. \* $p < .05$ , \*\*\* $p < .001$ .

WT rats (Figure 2C). Regarding an imbalance of the inhibitory/excitatory system, the ratio of GABA/glutamic acid and glycine/glutamic acid was higher in the thalamus of  $Txn1^{F54L/F54L}$  rats than in WT (Figure 2D,E). The inhibitory systems in the  $Txn1^{F54L/F54L}$  lesion were more dominant than in the WT.

IHC analysis showed a considerably higher activation of astrocytes in  $Txn1^{F54L/F54L}$  rats than in WT at 3, 5, and 9 weeks of age. The peak point of activation was at 5 weeks (Figure 2F,G). In IHC of microglia, there was no significant difference in activation between WT and  $Txn1^{F54L/F54L}$  rats at 3 weeks. A morphological change in microglia from a ramified to an amoeboid phenotype was observed at 5 weeks in  $Txn1^{F54L/F54L}$  rats (Figure

2H). The peak point of microglial activation was at 5 weeks (Figure 2I).

## 4 | DISCUSSION

Previous animal models of epilepsy have been classified as either generalized or focal epilepsy.<sup>1</sup> To the best of our knowledge, this is the first report of an animal model of combined generalized and focal epilepsy. In humans, Dravet syndrome and Lennox–Gastaut syndrome (LGS) fall into the category of combined generalized and focal epilepsy. Both are intractable epilepsies. *SCN1A* mutations have been detected in approximately 80% of patients

with Dravet syndrome, whereas LGS has a broader genetic heterogeneity than Dravet syndrome.<sup>11</sup> Patients with LGS have a variety of seizure types, including tonic seizures, absence seizures, drop attacks, and focal seizures. The epileptic seizure network of LGS is thought to involve the thalamus, brainstem, and cerebral cortex.<sup>12</sup>

Based on the EEG analysis, *Adem* rats exhibited some similarities with LGS in humans. The seizure types were toniclike seizures, absence seizures, and focal seizures. At the onset of the brief toniclike seizure, ictal EEG showed a generalized low-voltage pattern. Absence seizures are also a common seizure type in patients with LGS. Taken together with the various seizure types and thalamus lesions in *Adem* rats, this model may share a pathology similar to that of LGS in humans. Experiments using depth electrodes into the vacuolar degenerative lesions and brainstem could provide more detailed information on epileptic activity in the future.

There are some features of *Adem* rats that are not typical of LGS in humans. Epileptic discharges have never been observed on background EEG during the period without epileptic seizures. Mutation of *TXN* has not been reported to cause epilepsy in humans. However, mutation of *TXNRD1*, a component of the thioredoxin system,<sup>7</sup> has been linked to juvenile myoclonic epilepsy.<sup>13</sup> Patients with a homozygous mutation of *TXNRD1* were reported to have absence, myoclonic, and tonic-clonic seizures. In the future, we anticipate a group of genes comprising the thioredoxin system may be identified in patients with generalized epilepsy or combined generalized and focal epilepsy.

In our previous study, we showed that cells isolated from *Adem* rats are sensitive to H<sub>2</sub>O<sub>2</sub>.<sup>6</sup> However, there is no report that H<sub>2</sub>O<sub>2</sub> per se directly induces epileptic seizures. Therefore, we hypothesized that an imbalance between excitatory and inhibitory systems causes epilepsy. The GC-MS results of neurotransmitters ruled out that *Adem* rats had a dominance of glutamic acid in the midbrain compared to WT rats. Some compensatory mechanisms might be at work, but the reason for this was not clarified in this study. The raphe nuclei in the brainstem seemed to be outside the degenerative vacuolar lesions. The involvement of the serotonin nervous system remains unclear and should be investigated in future studies.

Activation of glial cells might play a critical role in the occurrence of seizures in *Adem* rats. IHC revealed that significant activation of astrocytes and microglia occurred at 5 weeks of age, rather than at the time of neuronal death at 3 weeks of age. The damaged brain initiates the repair process by activating astrocytes.<sup>14</sup> Microglia that are activated in synchrony with astrocytes remove debris and dead neurons by phagocytosis.<sup>15</sup> Activated microglia release proinflammatory cytokines such as tumor necrosis

factor  $\alpha$ , interleukin (IL)-1 $\beta$ , and IL-6, leading to neurodegeneration and inflammatory responses in the central nervous system.<sup>15</sup> These cytokines are known to cause epileptic seizures.<sup>16</sup> Neuronal death in ischemia–reperfusion injury due to stroke<sup>17</sup> and hypoxic–ischemic encephalopathy in newborns<sup>18</sup> are well-known conditions induced by oxidative stress. In these pathological conditions, intractable epilepsy often develops months to years after an acute injury.

*Adem* rats inform basic research on epilepsy in the following two aspects: first, they offer a new model of combined generalized and focal epilepsy; second, they suggest an epileptogenic mechanism after neuronal death caused by oxidative stress.

## AUTHOR CONTRIBUTIONS

I.O. and M.O. performed MRI examination of this strain; I.O., K.K., and S.I. performed EEG analysis. M.S. performed metabolome analysis. I.O. examined IHC of the brain. Conceptualization: I.O., M.O., and T.M. Writing–original draft: I.O. Writing–review & editing: M.O. M.S., K.K., S.I., and T.M. Project administration: I.O. Funding acquisition: M.O., I.O., and T.M. All authors approved the final manuscript.

## ACKNOWLEDGMENTS

This work was supported by the Grants-in-Aid for Scientific Research (16H05354); the Grant-in-Aid for epilepsy research from the Japan Epilepsy Research Foundation, JSPS KAKENHI (JP16H06276); and the International Joint Usage/Research Center, Institute of Medical Science, University of Tokyo. The authors thank Yumiko Morishita, Mika Monobe, and Miki Kajino of Okayama University for their technical assistance with IHC; and Editage ([www.editage.com](http://www.editage.com)) for English language editing.

## CONFLICT OF INTEREST

None of the authors has any conflict of interest to disclose. We confirm that we have read the Journal's position on issues involved in ethical publication and affirm that this report is consistent with those guidelines.

## DATA AVAILABILITY STATEMENT

Data are available on request from the authors.

## ORCID

Iori Ohmori  <https://orcid.org/0000-0001-6823-2762>

## REFERENCES

1. Löscher W. Critical review of current animal models of seizures and epilepsy used in the discovery and development of new antiepileptic drugs. *Seizure*. 2011;20:359–68.

2. Grone BP, Baraban SC. Animal models in epilepsy research: legacies and new directions. *Nat Neurosci*. 2015;18:339–43.
3. Baraban SC. Emerging epilepsy models: insights from mice, flies, worms and fish. *Curr Opin Neurol*. 2007;20:164–8.
4. Griffin A, Krasniak C, Baraban SC. Advancing epilepsy treatment through personalized genetic zebrafish models. *Prog Brain Res*. 2016;226:195–207.
5. Kandratavicius L, Balista PA, Lopes-Aguiar C, Ruggiero RN, Umeoka EH, Garcia-Cairasco N, et al. Animal models of epilepsy: use and limitations. *Neuropsychiatr Dis Treat*. 2014;10:1693–705.
6. Ohmori I, Ouchida M, Imai H, Ishida S, Toyokuni S, Mashimo T. Txn1 mutation causes epilepsy associated with vacuolar degeneration in the midbrain. *bioRxiv*. 2021. <https://doi.org/10.1101/2021.10.07.463470v1>
7. Lu J, Holmgren A. The thioredoxin antioxidant system. *Free Radic Biol Med*. 2014;66:75–87.
8. Irino Y, Toh R, Nagao M, Mori T, Honjo T, Shinohara M, et al. 2-Aminobutyric acid modulates glutathione homeostasis in the myocardium. *Sci Rep*. 2016;6:36749.
9. Lai Z, Tsugawa H, Wohlgemuth G, Mehta S, Mueller M, Zheng Y, et al. Identifying metabolites by integrating metabolome databases with mass spectrometry cheminformatics. *Nat Methods*. 2018;15:53–6.
10. Kanda Y. Investigation of the freely available easy-to-use software 'EZ' for medical statistics. *Bone Marrow Transplant*. 2013;48:452–8.
11. Verrotti A, Striano P, Iapadre G, Zagaroli L, Bonanni P, Coppola G, et al. The pharmacological management of Lennox-Gastaut syndrome and critical literature review. *Seizure*. 2018;63:17–25.
12. Warren AEL, Harvey AS, Vogrin SJ, Bailey C, Davidson A, Jackson GD, et al. The epileptic network of Lennox-Gastaut syndrome: cortically driven and reproducible across age. *Neurology*. 2019;93:e215–26.
13. Kudin AP, Baron G, Zsurka G, Hampel KG, Elger CE, Grote A, et al. Homozygous mutation in TXNRD1 is associated with genetic generalized epilepsy. *Free Radic Biol Med*. 2017;106:270–7.
14. Burda JE, Sofroniew MV. Reactive gliosis and the multicellular response to CNS damage and disease. *Neuron*. 2014;81:229–48.
15. Vainchtein ID, Molofsky AV. Astrocytes and microglia: in sickness and in health. *Trends Neurosci*. 2020;43:144–54.
16. Vezzani A, French J, Bartfai T, Baram TZ. The role of inflammation in epilepsy. *Nat Rev Neurol*. 2011;7:31–40.
17. Eastman CL, D'Ambrosio R, Ganesh T. Modulating neuroinflammation and oxidative stress to prevent epilepsy and improve outcomes after traumatic brain injury. *Neuropharmacology*. 2020;172:107907.
18. Qin X, Cheng J, Zhong Y, Mahgoub OK, Akter F, Fan Y, et al. Mechanism and treatment related to oxidative stress in neonatal hypoxic-ischemic encephalopathy. *Front Mol Neurosci*. 2019;12:88.

## SUPPORTING INFORMATION

Additional supporting information may be found in the online version of the article at the publisher's website.

**How to cite this article:** Ohmori I, Ouchida M, Shinohara M, Kobayashi K, Ishida S, Mashimo T. Novel animal model of combined generalized and focal epilepsy. *Epilepsia*. 2022;63:e80–e85. <https://doi.org/10.1111/epi.17295>