

[ORIGINAL ARTICLE]

Clinicopathological Characteristics of Superficial Barrett's Adenocarcinoma in a Japanese Population: A Retrospective, Multicenter Study

Kenta Hamada¹, Hiromitsu Kanzaki¹, Koji Miyahara², Masahiro Nakagawa², Hirokazu Mouri³, Motowo Mizuno³, Sakuma Takahashi⁴, Shinichiro Hori⁵, Junichiro Nasu⁶, Takao Tsuzuki⁷, Jiro Miyaike⁸, Ryuta Takenaka⁹, Kenji Yamauchi¹⁰, Sayo Kobayashi¹¹, Tatsuya Toyokawa¹², Masafumi Inoue¹³, Mamoru Nishimura¹⁴, Minoru Matsubara¹⁵, Jun Tomoda¹⁶, Yasushi Yamasaki¹, Takehiro Tanaka¹⁷, Yasuhiro Shirakawa¹⁸, Yoshiro Kawahara¹⁹, Toshiyoshi Fujiwara¹⁸ and Hiroyuki Okada¹; Okayama Gut Study Group

Abstract:

Objective Although Barrett's adenocarcinoma (BA) remains a minor disease in Japan, its incidence has been gradually increasing. We analyzed the characteristics of BA in Japanese populations.

Methods We retrospectively reviewed medical records and analyzed the clinicopathological differences between short-segment Barrett's esophagus (SSBE) and long-segment Barrett's esophagus (LSBE), as well as metastasis. Local recurrence and metachronous lesions were analyzed only in patients who underwent endoscopic resection (ER).

Patients Consecutive patients who had pathological T1 BAs resected by ER or surgery from January 2003 to December 2017.

Results A total of 168 patients were analyzed, including 139 with SSBE and 29 with LSBE. In total, 67% of the SSBE lesions and 32% of the LSBE lesions were located between 0 and 3 o'clock ($p=0.0014$). No patients who achieved pathological margin-free resection (pR0) and 17% of patients who did not achieve pR0 experienced local recurrence ($p=0.0131$). None of the patients without lymphovascular involvement, a poorly differentiated component, lesion size of >30 mm, and submucosal invasion of >500 μ m experienced metastasis. The 5-year cumulative incidence rate of metachronous BA after ER was 0% in patients with SSBE and 40% in patients with LSBE ($p=0.0005$).

Conclusion Superficial BA was likely to be detected at the right anterior wall of SSBE in the Japanese population. The risk for metachronous BA after ER was high in Japanese patients with LSBE, as in Western patients.

Key words: Barrett's adenocarcinoma, endoscopic resection, long-segment Barrett's esophagus, metachronous lesion, short-segment Barrett's esophagus, surgery

(Intern Med 61: 1115-1123, 2022)

(DOI: 10.2169/internalmedicine.6942-20)

¹Department of Gastroenterology and Hepatology, Okayama University Graduate School of Medicine, Dentistry and Pharmaceutical Sciences, Japan, ²Department of Internal Medicine, Hiroshima City Hospital, Japan, ³Department of Gastroenterology and Hepatology, Kurashiki Central Hospital, Japan, ⁴Department of Gastroenterology, Kagawa Prefectural Central Hospital, Japan, ⁵Department of Endoscopy, National Hospital Organization Shikoku Cancer Center, Japan, ⁶Department of Internal Medicine, Okayama Saiseikai General Hospital, Japan, ⁷Department of Internal Medicine, Japanese Red Cross Society Himeji Hospital, Japan, ⁸Department of Internal Medicine, Saiseikai Imabari Hospital, Japan, ⁹Department of Internal Medicine, Tsuyama Chuo Hospital, Japan, ¹⁰Department of Gastroenterology, Mitoyo General Hospital, Japan, ¹¹Department of Internal Medicine, Fukuyama City Hospital, Japan, ¹²Department of Gastroenterology, National Hospital Organization Fukuyama Medical Center, Japan, ¹³Department of Gastroenterology, Japanese Red Cross Okayama Hospital, Japan, ¹⁴Department of Internal Medicine, Okayama City Hospital, Japan, ¹⁵Department of Internal Medicine, Sumitomo Besshi Hospital, Japan, ¹⁶Department of Internal Medicine, Akaiwa Medical Association Hospital, Japan, ¹⁷Department of Pathology, Okayama University Graduate School of Medicine, Dentistry and Pharmaceutical Sciences, Japan, ¹⁸Department of Gastroenterological Surgery, Okayama University Graduate School of Medicine, Dentistry and Pharmaceutical Sciences, Japan and ¹⁹Department of Practical Gastrointestinal Endoscopy, Okayama University Graduate School of Medicine, Dentistry and Pharmaceutical Sciences, Japan

Received for publication December 16, 2020; Accepted for publication August 11, 2021

Correspondence to Dr. Kenta Hamada, paosishou@yahoo.co.jp

Introduction

The incidence of Barrett's adenocarcinoma (BA) has increased dramatically over the past few decades in Western countries and accounts for more than 50% of all esophageal malignancies in the United States (1). Among esophageal carcinomas in Japan, the incidence of BA increased from 3.1% in 2005 to 7.2% in 2015 (2, 3). Thus, even though BA remains a minor disease in Japan, close attention should be paid to it.

BA arises from Barrett's esophagus, which is classified as long-segment Barrett's esophagus (LSBE; circumferential Barrett's mucosa ≥ 3 cm) and short-segment Barrett's esophagus (SSBE; circumferential Barrett's mucosa < 3 cm or non-circumferential Barrett's mucosa), according to the criteria proposed by the Japan Esophageal Society (4). In Japan, the ratio of SSBE to LSBE (25-104 times) is higher than that in Western countries (2-4 times) (5-8); therefore, BA is usually detected in patients with SSBE (9, 10).

In terms of endoscopic treatment, ablation therapy is usually applied to the remaining non-neoplastic Barrett's epithelium after endoscopic mucosal resection (EMR) of primary lesion in Western countries, as LSBE has a high risk of metachronous BA (11, 12). However, this approach has not been adopted in Japan, as most cases are from SSBE, and Japanese medical insurance does not cover the cost of treatment. Hence, endoscopic en bloc resection using endoscopic submucosal dissection (ESD) is performed for curable cases, and surveillance esophagogastroduodenoscopy (EGD) is usually performed after resection. However, the risk of metachronous BA, particularly in patients with LSBE, has not been fully investigated in Japan, and no specific follow-up method after endoscopic resection (ER) has been established (13).

Given the differences in the patient background between Western countries and Japan, we assessed the clinicopathological characteristics of superficial BA in a Japanese population.

Materials and Methods

Participants

This was a multicenter, retrospective, observational study conducted at 16 institutes (Okayama Gut Study Group) in Japan, comprising 1 university hospital, 1 cancer center, and 14 general hospitals. Records for all patients who underwent ER or surgery for esophageal adenocarcinoma, from January 2003 to December 2017, were extracted from the pathology database and reviewed. Patients were included in the study if they met the following criteria: (i) histologically diagnosed adenocarcinoma, (ii) histologically diagnosed mucosal (M) or submucosal (SM) cancer, (iii) endoscopically confirmed lesion arising within or adjacent to an area of Barrett's esophagus, (iv) center of the lesion in the esophagus,

and (v) age ≥ 20 years old at the time of treatment.

Barrett's esophagus was endoscopically defined as columnar-lined distal esophagus between the squamocolumnar junction and esophagogastric junction (EGJ). EGJ was endoscopically defined as the lower margin of palisading small vessels, according to the criteria proposed by the Japan Esophageal Society (4). If the palisading small vessels were unclear, EGJ was defined as the oral margin of the longitudinal folds of the greater curvature of the stomach folds. The endoscopic diagnosis was made by the endoscopic specialists at the individual facilities. Patients were excluded if they had a history of chemotherapy or radiation before ER or surgery.

As only anonymous retrospective data were used in the present study, the opt-out method was used for obtaining informed consent. The study protocol was first approved by the ethics committee of Okayama University Graduate School of Medicine, Dentistry, and Pharmaceutical Sciences and Okayama University Hospital and subsequently by each institutional review board. The ethics committee that approved the present study waived the need for written informed consent as part of the study approval. The study was performed in accordance with the Declaration of Helsinki.

Standard handling of resected specimens

Pathological examinations were performed according to the standard methods proposed by the Japan Esophageal Society (4). Resected specimens were stretched and fixed on boards and fixed in formalin solution. After fixation, all resected specimens were cut into 2- to 3-mm-wide longitudinal slices for ER specimens and 5-mm-wide slices for surgical specimens. The slices were embedded in paraffin, and all the sections were stained with hematoxylin and eosin.

The macroscopic appearance was classified as the protruding type (Type 0-I or 0-I + other types) or the flat type (Type 0-IIa, 0-IIb or 0-IIc). The cancer invasion depth was classified according to the Japanese Classification of Esophageal Cancer (4). Barrett's esophagus may include new muscularis mucosae just under the columnar epithelium. The primary muscularis mucosae is called the deep muscularis mucosae (DMM), and the new muscularis mucosae is called the superficial muscularis mucosae (SMM). However, the identification of SMM and DMM is occasionally difficult due to the fusion of both layers, the thickness of the layer, or the presence of irregularities. Therefore, in the present study, cancer extending beyond the basement membrane into the SMM or lamina propria mucosae (LPM) was classified as LPM cancer, regardless of SMM presence, and cancer with invasion into the deepest muscularis mucosae was defined as DMM cancer.

Cancer differentiation was determined, and lesions were judged positive for a poorly differentiated component if it was identified in the part invading the DMM or SM (9). An infiltrative growth pattern was defined as follows: type a, expansive growth of tumor nests with a well-demarcated border from surrounding tissue; type b, intermediate growth

pattern, between type a and c; type c, infiltrative growth of tumor nests with an ill-defined border relative to the surrounding tissue (4). Cancer differentiation and an infiltrative growth pattern were evaluated only in DMM and SM cancers. The resection margin was defined as follows: pR0, no cancer was pathologically recognized in any resection margin; pR1, the cancer was pathologically recognized in any resection margin; and pRX, whether or not there was residual cancer in any resection margin could not be pathologically assessed (4). The pathological diagnosis was made by the pathologists at the individual facilities.

Data collection

The patient, lesion, and treatment characteristics were obtained from the database or medical records and included the age at the time of treatment, sex, Barrett's esophagus type (LSBE or SSBE), maximum length and circumference of Barrett's mucosa, synchronous BA (BA detected before or during treatment), tumor location from EGJ, tumor direction, and treatment method (ER, ER followed by surgery, or surgery). In the last 15 years, ESD has become the mainstay for ER, and thoracoscopic surgery is performed in addition to open thoracotomy. However, regardless of the details of the procedure, ER remains local resection aimed at pR0, while surgery remains resection including lymph node dissection. Therefore, data were collected as ER and surgery, as the outcome of this study was not the difference in the survival or complications according to treatment modality but the assessment of recurrence risk based on the pathological findings. The histological features of the lesions were obtained from the pathology reports and included tumor size, macroscopic appearance, invasion depth, histological type, infiltrative growth pattern, lymphovascular involvement, and resection margin. In cases with synchronous BA, only the deepest lesion was assessed, and only the largest lesion was included when their invasion depth was the same. Follow-up patient data were obtained from medical records and evaluated based on the data collected until January 1, 2018, and they included local recurrence or residual tumor after ER, metastasis, and metachronous BA. Local recurrence or residual tumor after ER was evaluated in patients who first underwent ER. Local recurrence or residual tumor after ER was defined as an adenocarcinoma arising on or adjacent to the scar caused by ER and was considered positive if one of the following criteria was met: (i) histologically confirmed local recurrence during follow-up after ER or (ii) histologically confirmed residual tumor in additional surgical specimens. Local recurrence or residual tumor after ER was considered negative if (i) no local recurrence was identified during follow-up for ≥ 1 year after ER, or (ii) no residual tumor was identified in additional surgical specimens. Metastasis was considered positive if one of the following criteria was met: (i) histologically confirmed metastasis in surgical specimen or (ii) clinically confirmed metastasis during follow-up after surgery or ER. Metastasis was considered negative if (i) no metastasis was identified in resected specimens and

during follow-up for ≥ 3 years for patients treated by surgery, or (ii) no metastasis was identified during follow-up for ≥ 5 years for patients treated by ER alone. Based on a previous study conducted at high-volume Japanese centers (9), patients with lesions without lymphovascular involvement, a poorly differentiated component, and a lesion size of >30 mm were defined as low-risk patients, and those with lesions with any of these factors were defined as high-risk patients. Metachronous BA was evaluated only in patients who underwent ER alone, defined as an adenocarcinoma newly detected within or adjacent to an area of remnant Barrett's esophagus after ER. Local recurrence as defined above was excluded from metachronous BA. A lesion that was newly detected within six months after ER was defined as synchronous BA missed at the time of ER.

Statistical analyses

A comparison of clinicopathological characteristics was made between the LSBE and SSBE groups. Subgroup analyses were conducted to identify differences in local recurrence or residual tumor risk between the pR0 and pR1/pRX groups and those in metastasis risk between the low- and high-risk groups. All continuous variables were expressed as the median with range. Statistical analyses were conducted using Mann-Whitney's U test for numerical data and Fisher's exact test or chi-square test for categorical outcomes. The cumulative metachronous BA incidence rates between the LSBE and SSBE groups were estimated using the Kaplan-Meier method, and the log-rank test was used to analyze the difference between the two curves. The computer software program JMP version 14 (SAS Institute, Cary, USA) was used for the data analysis. Significance was set at $p < 0.05$.

Results

Participant flow (Fig. 1)

In the present study, 168 consecutive patients with superficial BA treated with ER or surgery were included. There were no missing data related to the analyses performed in the present study. A total of 79 patients underwent ER alone (ESD: 76 patients, EMR: 3 patients), and none received additional ablation therapy. Meanwhile, 17 patients underwent additional surgery after ER (all patients had undergone ESD) according to the physician's discretion (SM cancer: 13 patients, DMM or LPM cancer with lymphovascular involvement: 4 patients). Finally, 72 patients underwent surgery as the first intervention, mainly because their lesions were endoscopically diagnosed as SM cancers. In all 168 patients studied, the characteristics of patients, lesions, and treatments were analyzed. Using follow-up data, local recurrence was analyzed in 73 patients who first received ER. The metastatic lesion was analyzed in 73 patients. The metachronous lesion was analyzed in 58 patients who underwent ER alone.

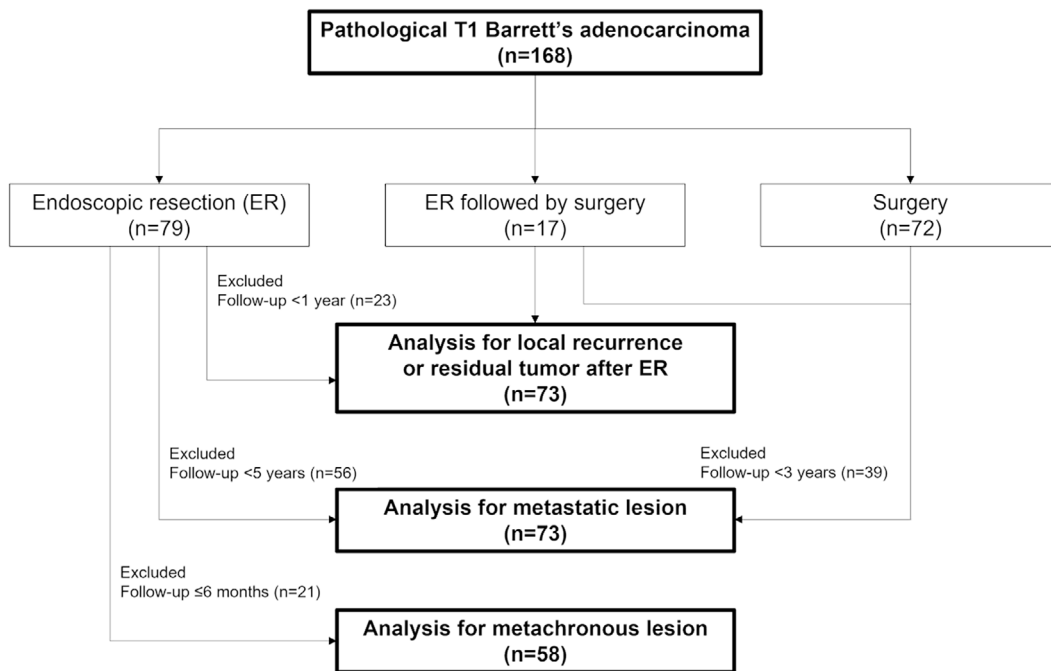


Figure 1. Participant flow. ER: endoscopic resection

Characteristics of patients, lesions, and treatment

The median age was 67 (41-89) years old, and 87% were men. The median tumor size was 19 (3-112) mm, and 71% were flat-type lesions; this study cohort did not include Type 0-III lesions. A total of 27% were DMM cancers, and 46% were SM cancers. A poorly differentiated component was positive in 16%, and lymphovascular involvement was positive in 30%. A total of 93% achieved pR0 resection: 100% in patients who underwent surgery and 85% in patients who underwent ER alone. A total of 29 patients (17%) had LSBE, and 139 patients (83%) had SSBE. A total of 86% of the patients had a maximum length of Barrett's mucosa <3 cm in the SSBE group. A total of 47% of the patients had circumferential Barrett's mucosa in the SSBE group. The median ages were 73 (50-89) years old in the LSBE group and 66 (41-87) years old in the SSBE group ($p=0.0035$). The median tumor sizes were 28 (7-100) mm in the LSBE group and 17 (3-112) mm in the SSBE group ($p=0.0033$). A total of 66% of the tumors were located in the area >2 cm from the EGJ in the LSBE group, and 70% were located in the area <1 cm from the EGJ in the SSBE group ($p<0.0001$). Tumors in the SSBE group were typically located between 0 and 3 o'clock (67%), and the rate was significantly higher than that in the LSBE group (32%) ($p=0.0014$, Fig. 2). Representative cases are shown in Figs. 3 and 4. No significant difference was observed in the other variables, including synchronous BA, between the groups (Table 1).

A subgroup analysis of local recurrence or residual tumor after ER

A total of 3 in 73 patients experienced local recurrence: none of the 55 patients in the pR0 group and 3 of the 18

patients in the pR1/pRX group ($p=0.0131$). No residual tumor was detected in additional surgical specimens. The three cases of local recurrence were detected four, six, and seven months after ER for the SSBE group. The mean follow-up periods were 53 (12-142) months in 53 patients who underwent ER alone and did not experience local recurrence.

A subgroup analysis of metastasis

The low-risk group included 31 patients with 20 M and 11 SM cancers. The high-risk group included 42 patients: 12 lesions with lymphovascular involvement alone, 1 lesion with a poorly differentiated component alone, 14 lesions with a lesion size of >30 mm alone, 6 lesions with lymphovascular involvement and a poorly differentiated component, 6 lesions with lymphovascular involvement and a lesion size of >30 mm, 1 lesion with a poorly differentiated component and a lesion size of >30 mm, and 2 lesions with all of the factors. The high-risk group included 13 M and 29 SM cancers. Overall, metastases were identified in 15 patients (21%) during the study period: 1 of 31 patients (3%) in the low-risk group and 14 of 42 patients (33%) in the high-risk group ($p=0.0024$). The patient who experienced metastasis in the low-risk group had an SM cancer with invasion depths of >500 μm . The initial sites of metastases were the lymph nodes in 14 patients and the lymph nodes and lung in 1 patient. Metastases were confirmed in surgical specimens from 13 patients, including 1 patient who received additional surgery after ER. The mean follow-up periods were 63 (36-174) months in 37 patients who underwent surgery resulting in no metastases in surgical specimens and 80 (60-142) months in 23 patients who underwent ER alone. Metastases developed during the follow-up period in four patients who underwent surgery.

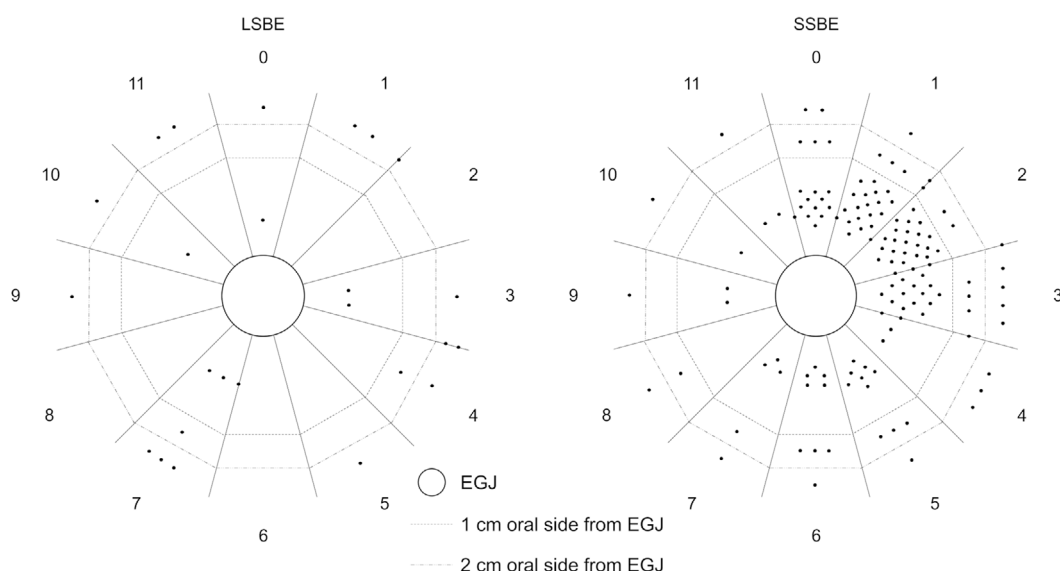


Figure 2. Tumor distribution between the LSBE and SSBE groups. Factors are evaluated in 160 non-circumferential cancers. LSBE: long-segment Barrett's esophagus, SSBE: short-segment Barrett's esophagus, EGJ: esophagogastric junction

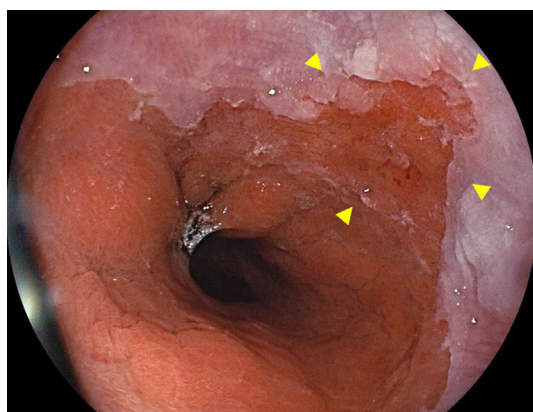


Figure 3. Representative endoscopic image of Barrett's adenocarcinoma in short-segment Barrett's esophagus.

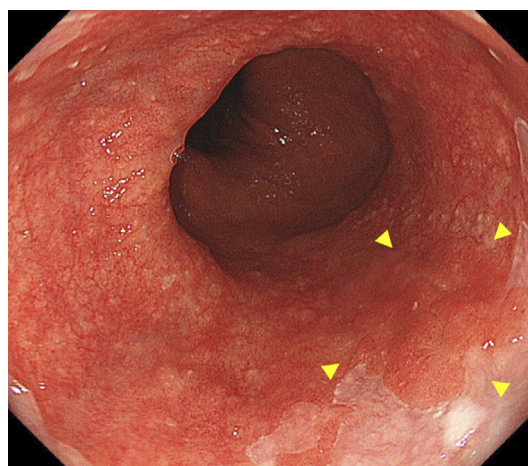


Figure 4. Representative endoscopic image of Barrett's adenocarcinoma in long-segment Barrett's esophagus.

A subgroup analysis of metachronous BA

Mean follow-up periods were 48 (7-142) months. A total of 4 of 58 patients experienced metachronous BAs: 1 of 48 patients in the SSBE group and 3 of 10 patients in the LSBE group. The cumulative metachronous BA incidence rate curve showed a significant difference between the 2 groups ($p=0.0005$, Fig. 5). The 5-year cumulative incidence rate was 0% in the SSBE group, while the 1-, 3-, and 5-year cumulative incidence rates were 10%, 20%, and 40%, respectively, in the LSBE group. In addition, in the LSBE group, a patient experienced another metachronous BA 12 months after the initial metachronous BA incidence. All five metachronous BAs were M cancers (three LPM and two DMM cancers) with a low metastasis risk and were managed using ER. In the LSBE group, the endoscopic findings of the esophagus were compared between patients with and without metachronous BAs, and no marked differences were

observed (Table 2).

Discussion

This retrospective, multicenter study demonstrated that in Japan, superficial BAs were more likely to be detected in SSBE than in LSBE and were frequently located between the 0 and 3 o'clock positions. Local recurrence after ER was likely to occur in patients in the pR1/pRX group, and metastasis was likely to be identified in high-risk patients. The patients with LSBE had a significantly higher risk for metachronous BAs after ER than those with SSBE.

It is important to be aware of the likely sites of superficial BA in order to detect it in its early stage. Many studies have demonstrated that most superficial BAs are found between 0 and 3 o'clock (10, 14-17). However, this rule may

Table 1. Characteristics of Patients, Lesions, and Treatments.

	Total n=168	LSBE n=29	SSBE n=139	p value
Maximum length of Barrett's mucosa				<0.0001
<1 cm	45 (27)	0 (0)	45 (32)	
1 to <3 cm	75 (44)	0 (0)	75 (55)	
3 to <6 cm	28 (17)	13 (45)	15 (11)	
6 to <9 cm	5 (3)	3 (10)	2 (1)	
≥9 cm	15 (9)	13 (45)	2 (1)	
Circumference of Barrett's mucosa				<0.0001
<1/4	8 (5)	0 (0)	8 (6)	
1/4 to <1/2	23 (14)	0 (0)	23 (17)	
1/2 to <3/4	12 (7)	0 (0)	12 (9)	
3/4 to <1	29 (17)	0 (0)	29 (21)	
1	96 (57)	29 (100)	67 (47)	
Age, years	67 (41-89)	73 (50-89)	66 (41-87)	0.0035
Sex				0.22
Male	146 (87)	23 (79)	123 (88)	
Female	22 (13)	6 (21)	16 (12)	
Tumor size, mm	19 (3-112)	28 (7-100)	17 (3-112)	0.0033
Macroscopic appearance				0.37
Protruding type	48 (29)	6 (21)	42 (30)	
Flat type	120 (71)	23 (79)	97 (70)	
Tumor location from EGJ				<0.0001
<1 cm	104 (62)	7 (24)	97 (70)	
1-2 cm	27 (16)	3 (10)	24 (17)	
>2 cm	37 (22)	19 (66)	18 (13)	
Tumor direction ^a				0.0014
0-3 o'clock	99 (62)	8 (32)	91 (67)	
Other directions	61 (38)	17 (68)	44 (33)	
Treatment				0.054
ER	79 (47)	12 (41)	67 (48)	
ER followed by surgery	17 (10)	0 (0)	17 (12)	
Surgery	72 (43)	17 (59)	55 (40)	
Invasion depth				0.82
LPM	45 (27)	9 (31)	36 (26)	
DMM	46 (27)	8 (28)	38 (27)	
SM	77 (46)	12 (41)	65 (47)	
Poorly differentiated component ^b				1.0
Positive	20 (16)	3 (15)	17 (17)	
Negative	103 (84)	17 (85)	86 (83)	
Infiltrative growth pattern ^b				0.28
Type a	26 (21)	3 (15)	23 (22)	
Type b	92 (75)	15 (75)	77 (75)	
Type c	5 (4)	2 (10)	3 (3)	
Lymphovascular involvement				0.82
Positive	51 (30)	8 (28)	43 (31)	
Negative	117 (70)	21 (72)	96 (69)	
Resection margin				1.0
pR0	156 (93)	27 (93)	129 (93)	
pR1 or pRX	12 (7)	2 (7)	10 (7)	
Synchronous Barrett's adenocarcinoma				0.53
Present	4 (2)	1 (3)	3 (2)	
Absent	164 (98)	28 (97)	136 (98)	

Data are expressed as the median (range) or n (%).

LSBE: long-segment Barrett's esophagus, SSBE: short-segment Barrett's esophagus, EGJ: esophagogastric junction, ER: endoscopic resection, LPM: lamina propria mucosae, DMM: deep muscularis mucosae, SM: submucosa, Infiltrative growth pattern type a: expansive growth of tumor nests with a well-demarcated border from surrounding tissue, Infiltrative growth pattern type b: intermediate growth pattern between type a and c, Infiltrative growth pattern type c: infiltrative growth of tumor nests with an ill-defined border with the surrounding tissue, pR0: pathologically negative resection margin, pR1: pathologically positive resection margin, pRX: pathologically non-assessable resection margin

^aFactors are evaluated in 160 patients with non-circumferential cancers.

^bFactors are evaluated in 123 patients with DMM and SM cancers.

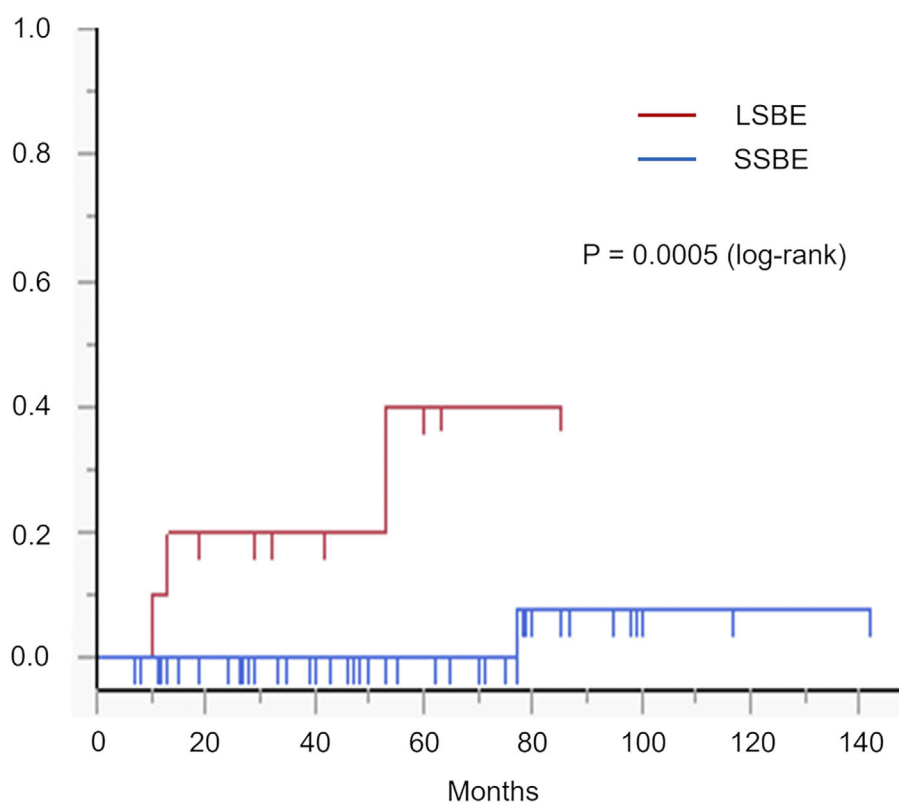


Figure 5. Cumulative metachronous Barrett's adenocarcinoma incidence rates between the LSBE and SSBE groups. LSBE: long-segment Barrett's esophagus, SSBE: short-segment Barrett's esophagus

Table 2. Endoscopic Findings of the Esophagus in Cases with and without Metachronous BA from Long-segment Barrett's Esophagus.

	Metachronous BA	
	Present n=3	Absent n=7
Hiatal hernia		
Present	3 (100)	7 (100)
Absent	0 (0)	0 (0)
Reflux esophagitis during surveillance endoscopy		
Present	2 (67)	3 (43)
Absent	1 (33)	4 (57)
Maximum length of Barrett's mucosa		
3 to <6 cm	1 (33)	1 (14)
6 to <9 cm	0 (0)	2 (29)
≥9 cm	2 (67)	4 (57)

Data are expressed as n (%).

BA: Barrett's adenocarcinoma

apply to only patients with SSBE. The present study demonstrated that superficial BAs were often detected between 0 and 3 o'clock in patients with SSBE, while they were able to be detected in any direction in patients with LSBE. The present study is the second report demonstrating that there is a statistically significant difference regarding the likely sites of superficial BA between patients with LSBE and those with SSBE in the same study cohort. This difference was originally demonstrated in a single-center study (18) and

subsequently validated in the present multicenter study, although the reason why such a difference was observed between LSBE and SSBE remains unclear.

On ER for adenocarcinoma of the EGJ, all cases of local recurrence were reported to occur in the pR1/pRX group, although the local recurrence rate in the pR1/pRX group was not shown (19). Therefore, it is also believed that pR0 resection reduces local recurrence of superficial BA; however, to date, data to confirm this have been insufficient. The present

study offers new evidence that endoscopic pR0 resection may reduce local recurrence of superficial BA. In addition, in the pR1/pRX group, all three patients experienced local recurrence within seven months after initial ER. Therefore, strict endoscopic follow-up should be conducted for at least one year after ER to detect local recurrence in its early stage when pR0 resection cannot be achieved and no additional surgery is performed. Meanwhile, in terms of local recurrence, such strict follow-up may not be required when pR0 resection is confirmed.

It is necessary to clarify the metastatic risk of superficial BA in order to determine the indications for additional surgery after ER. In a recent study conducted at high-volume Japanese centers, lymphovascular involvement, a poorly differentiated component, and a lesion size >3 cm were identified as independent risk factors for metastasis from superficial esophageal adenocarcinomas (9). Based on these findings, we divided patients into low- and high-risk groups. This risk classification system for metastasis was validated and suggested to be useful in patients with superficial BAs mainly treated at general hospitals. In the present study, 1 patient in the low-risk group had metastasis, and the invasion depth to the submucosa was >500 μm . SM cancers with invasion depths of >500 μm reportedly had a high metastasis risk, although SM invasion was not identified as an independent risk factor (9). Therefore, such cancers may need to be considered as being associated with a high risk of metastasis.

In Western countries, the risk for metachronous neoplasia is high in patients with LSBE, especially when no ablation therapy is performed for the remaining Barrett's esophagus after ER (11). However, included in the guidelines were the results of a systematic review (20) stating that there are no reports from Japan indicating that LSBE cases have increased rates of metachronous neoplasia after ER (19, 21, 22). To our knowledge, the present study is the first to demonstrate a high risk for metachronous neoplasia in patients with LSBE in a Japanese population. This is one of the few valuable data unique to Japan that cannot be obtained in Western countries, where ablation therapy is performed for the remaining Barrett's esophagus after ER. Japanese patients may also require ablation therapy after ER of BA arising from LSBE, as the American College of Gastroenterology clinical guideline recommends (12). However, at present in Japan, where ablation therapy is not covered by medical insurance, strict endoscopic surveillance for metachronous neoplasia is required, even if pR0 resection is confirmed. Our findings are important when considering post-ER surveillance.

However, the present study demonstrated that patients with SSBE had a low risk for metachronous adenocarcinoma. Therefore, in patients with SSBE, neither ablation therapy for the remaining Barrett's esophagus nor strict endoscopic surveillance may be required after ER when pR0 resection is confirmed.

Several limitations associated with the present study war-

rant mention. First, this was a retrospective study. Second, post-treatment follow-up was not performed according to a unified protocol, mainly because of restrictions arising from the study's retrospective design. Third, the quality of the endoscopic and histologic assessments was a limitation. Immunostaining, e.g. for desmin, D2-40, CD31, or CD34, was not mandatory in all patients, the invasion depth to the submucosa was not recorded in many cases, a central review of endoscopic and pathologic findings was not performed, and the reassessment of the slides was not approved by the ethics committee because it was difficult to obtain separate written informed consent from the patients. Therefore, the SM invasion distance could not be evaluated in all cases, and one case of metastasis was recognized in the low-risk group. However, in that case, SM invasion distance was >500 μm , so our results were not inconsistent with the previous reports (9). Finally, the small sample size was a limitation of this study.

In conclusion, noting the differences in likely sites of superficial BA between LSBE and SSBE may lead to the early detection of BA. The risk of metachronous BA after ER was shown to be high in Japanese patients with LSBE, as in Western patients.

The study protocol was approved first by the ethics committee of Okayama University Graduate School of Medicine, Dentistry and Pharmaceutical Sciences and Okayama University Hospital (the reference number: 1804-047) and subsequently by each institutional review board. As only anonymous retrospective data were used in the present study, the opt-out method was used to obtain informed consent. The ethics committee that approved the present study waived the need for written informed consent as part of the study approval.

The datasets used and analyzed in the present study are available from the corresponding author on reasonable request until February 28, 2024.

The authors state that they have no Conflict of Interest (COI).

Acknowledgements

The authors would like to thank Dr. Tomoki Inaba (Department of Gastroenterology, Kagawa Prefectural Central Hospital), Dr. Masahiro Takatani (Department of Internal Medicine, Japanese Red Cross Society Himeji Hospital), and Dr. Yuki Baba (Department of Gastroenterology, Mitoyo General Hospital) for their assistance with the data collection.

References

1. Pohl H, Welch HG. The role of overdiagnosis and reclassification in the marked increase of esophageal adenocarcinoma incidence. *J Natl Cancer Inst* **97**: 142-146, 2005.
2. Masuda M, Endo S, Natsugoe S, et al.; Committee for Scientific Affairs, The Japanese Association for Thoracic Surgery. Thoracic and cardiovascular surgery in Japan during 2015: Annual report by The Japanese Association for Thoracic Surgery. *Gen Thorac Cardiovasc Surg* **66**: 581-615, 2018.
3. Ueda Y, Osada H, Osugi H; Japanese Association for Thoracic

- Surgery Committee for Scientific Affairs. Thoracic and cardiovascular surgery in Japan during 2005. Annual report by the Japanese Association for Thoracic Surgery. *Gen Thorac Cardiovasc Surg* **55**: 377-399, 2007.
4. Japan Esophageal Society. Japanese classification of esophageal cancer, 11th edition: part I. *Esophagus* **14**: 1-36, 2017.
 5. Gerson LB, Shetler K, Triadafilopoulos G. Prevalence of Barrett's esophagus in asymptomatic individuals. *Gastroenterology* **123**: 461-467, 2002.
 6. Rex DK, Cummings OW, Shaw M, et al. Screening for Barrett's esophagus in colonoscopy patients with and without heartburn. *Gastroenterology* **125**: 1670-1677, 2003.
 7. Ronkainen J, Aro P, Storskrubb T, et al. Prevalence of Barrett's esophagus in the general population: an endoscopic study. *Gastroenterology* **129**: 1825-1831, 2005.
 8. Amano Y, Kinoshita Y. Barrett esophagus: perspectives on its diagnosis and management in Asian populations. *Gastroenterol Hepatol* **4**: 45-53, 2008.
 9. Ishihara R, Oyama T, Abe S, et al. Risk of metastasis in adenocarcinoma of the esophagus: a multicenter retrospective study in a Japanese population. *J Gastroenterol* **52**: 800-808, 2017.
 10. Goda K, Singh R, Oda I, et al. Current status of endoscopic diagnosis and treatment of superficial Barrett's adenocarcinoma in Asia-Pacific region. *Dig Endosc* **2**: 146-150, 2013.
 11. Pech O, Behrens A, May A, et al. Long-term results and risk factor analysis for recurrence after curative endoscopic therapy in 349 patients with high-grade intraepithelial neoplasia and mucosal adenocarcinoma in Barrett's oesophagus. *Gut* **57**: 1200-1206, 2008.
 12. Shaheen NJ, Falk GW, Iyer PG, Gerson LB; American College of Gastroenterology. ACG clinical guideline: diagnosis and management of Barrett's esophagus. *Am J Gastroenterol* **111**: 30-50, 2016.
 13. Kitagawa Y, Uno T, Oyama T, et al. Esophageal cancer practice guidelines 2017 edited by the Japan esophageal society: part 2. *Esophagus* **16**: 25-43, 2019.
 14. Pech O, Gossner L, Manner H, et al. Prospective evaluation of the macroscopic types and location of early Barrett's neoplasia in 380 lesions. *Endoscopy* **39**: 588-593, 2007.
 15. Moriyama N, Amano Y, Okita K, Mishima Y, Ishihara S, Kinoshita Y. Localization of early-stage dysplastic Barrett's lesions in patients with short-segment Barrett's esophagus. *Am J Gastroenterol* **101**: 2666-2667, 2006.
 16. Enestvedt BK, Lugo R, Guarner-Argente C, et al. Location, location: does early cancer in Barrett's esophagus have a preference? *Gastrointest Endosc* **78**: 462-467, 2013.
 17. Okada M, Ishimura N, Mikami H, et al. Circumferential distribution and clinical characteristics of esophageal cancer in lower esophagus: differences related to histological subtype. *Esophagus* **16**: 98-106, 2019.
 18. Yamasaki A, Shimizu T, Kawachi H, et al. Endoscopic features of esophageal adenocarcinoma derived from short-segment versus long-segment Barrett's esophagus. *J Gastroenterol Hepatol* **35**: 211-217, 2020.
 19. Abe S, Ishihara R, Takahashi H, et al. Long-term outcomes of endoscopic resection and metachronous cancer after endoscopic resection for adenocarcinoma of the esophagogastric junction in Japan. *Gastrointest Endosc* **89**: 1120-1128, 2019.
 20. Ishihara R, Arima M, Iizuka T, et al. Endoscopic submucosal dissection/endoscopic mucosal resection guidelines for esophageal cancer. *Dig Endosc* **32**: 452-493, 2020.
 21. Kagemoto K, Oka S, Tanaka S, et al. Clinical outcomes of endoscopic submucosal dissection for superficial Barrett's adenocarcinoma. *Gastrointest Endosc* **80**: 239-245, 2014.
 22. Nagami Y, Machida H, Shiba M, et al. Clinical efficacy of endoscopic submucosal dissection for adenocarcinomas of the esophagogastric junction. *Endosc Int Open* **2**: E15-E20, 2014.

The Internal Medicine is an Open Access journal distributed under the Creative Commons Attribution-NonCommercial-NoDerivatives 4.0 International License. To view the details of this license, please visit (<https://creativecommons.org/licenses/by-nc-nd/4.0/>).