

[REVIEW ARTICLE]

Managing Lung Cancer with Comorbid Interstitial Pneumonia

Eiki Ichihara¹, Nobuaki Miyahara², Yoshinobu Maeda³ and Katsuyuki Kiura¹

Abstract:

Systemic therapy for advanced non-small cell lung cancer (NSCLC) has dramatically changed in the latest 15 years. Molecular-targeted therapy has brought about an era of precision medicine, and immune checkpoint inhibitors have brought hope for a cure for advanced NSCLC. In the wake of this remarkable advancement, lung cancer with comorbid interstitial pneumonia (IP) has been completely left behind, as most clinical trials exclude patients with comorbid IP. IP, especially idiopathic pulmonary fibrosis (IPF), is often accompanied by lung cancer, and acute exacerbation can develop during various cancer therapies, including surgery, radiotherapy and pharmacotherapy. In this review, we focus on the clinical questions concerning pharmacotherapy in cases of advanced lung cancer with comorbid IP and discuss what we can do with the currently available data.

Key words: lung cancer, interstitial pneumonia

(Intern Med 59: 163-167, 2020)

(DOI: 10.2169/internalmedicine.3481-19)

Introduction

Drug therapy for advanced lung cancer has dramatically changed in the last 15 years. Epidermal growth factor receptor (EGFR) gene mutations were discovered in 2004 and indicate a strong susceptibility to EGFR tyrosine kinase inhibitors (TKIs) (1). Anaplastic lymphoma kinase (ALK) gene rearrangement was discovered in 2007, and it has since become clear that ALK TKIs strongly inhibit ALK rearranged cancers (2). Subsequently, various gene aberrations, such as ROS1 rearrangement (3), RET rearrangement (3) and BRAF gene mutation (4), were found one after another. The 2000s can be said to have been an era in which molecular-targeted therapies in non-small cell lung cancer (NSCLC) greatly advanced. In 2012, nivolumab, an immune checkpoint inhibitor, was shown to be effective for some NSCLCs (5). Subsequently, similar agents have been developed, such as pembrolizumab and atezolizumab (6, 7). Immune checkpoint inhibitors are now attracting substantial attention because of their potential to cure advanced NSCLC.

However, despite such progress, lung cancer with comorbid interstitial pneumonia (IP) has been completely left behind. One of the major reasons for this is that almost all clinical trials exclude lung cancer with comorbid IP because of the risk of triggering acute exacerbation (AE) with anti-cancer therapy.

IP, especially idiopathic pulmonary fibrosis (IPF), often accompanies lung cancer, and its frequency reaches up to 10-20% (8). The biggest problem regarding lung cancer with comorbid IP is AE, which can be fatal and makes cancer treatment difficult during the clinical course. In addition, Japanese people are prone to drug-induced pulmonary toxicity, even in those without comorbid IP (8). Therefore, the establishment of a treatment strategy for lung cancer with comorbid IP is an urgent issue.

In the present review, we will focus on drug therapy for lung cancer with comorbid IP.

¹Department of Allergy and Respiratory Medicine, Okayama University Hospital, Japan, ²Department of Medical Technology, Okayama University Graduate School of Health Sciences, Japan and ³Department of Hematology, Oncology and Respiratory Medicine, Okayama University Graduate School of Medicine, Dentistry, and Pharmaceutical Sciences, Japan

Received: June 11, 2019; Accepted: August 8, 2019; Advance Publication by J-STAGE: September 18, 2019

Correspondence to Dr. Eiki Ichihara, ichiha-e@md.okayama-u.ac.jp

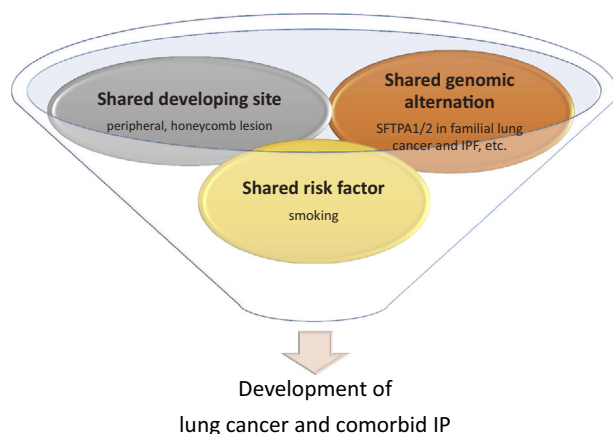


Figure. Similarities between lung cancer and IPF. There are some similarities between lung cancer and IPF, such as the development site, genomic alteration and influence of a smoking history.

Why Does IP Often Accompany Lung Cancer?

Although the precise rate of comorbidity is unclear, it has long been known that IP frequently accompanies lung cancer. Among different IPs, such as idiopathic IPs (IIPs), collagen vascular disease-associated IP (CVD IP) and pneumoconiosis, IPF has been well studied and often accompanies lung cancer. Although the frequency of comorbid IPF and lung cancer differs among studies, IPF is generally considered to accompany lung cancer in 10-20% of cases throughout the clinical course (9-13).

Why IP often accompanies lung cancer is unclear, but there are some similarities between lung cancer and IPF (Figure) that may be involved in the mechanisms underlying the comorbidity. Smoking is a shared risk factor for developing both lung cancer and IP. As is well known, smoking increases the risk of lung cancer development. It is also associated with an increased risk of IPF (14). The development site is another point of similarity between lung cancer and IP. Lung cancer often occurs around lesions with IP, suggesting that they may share a common development site (15-17). Furthermore, similarities in the molecular profiles between these two entities have also been reported (18, 19). There are reports of familial IP combined lung cancer associated with a surfactant protein germ cell mutation, suggesting that a common etiology may exist (20, 21).

Is Cancer Drug Therapy a Risk Factor for AE of IP?

Various cancer therapies, including surgery (22), radiation (23) and pharmacotherapy (24, 25), are risk factors of AE in cases of pre-existing IP. When AE develops during cancer pharmacotherapy in patients with comorbid IP, it is

difficult to distinguish from drug-induced pneumonitis. It was recently proposed that such cases be diagnosed as triggered AE, in contrast to AE without any idiopathic trigger factors (26).

Cytotoxic chemotherapy

The risk of AE in patients with lung cancer with comorbid IP due to cytotoxic chemotherapy is considered to be 10% to 30% (Table) (24, 25, 27-29). Given that the annual AE risk in the natural course of IP is 5-15% (30, 31) and that the risk of drug-induced pneumonia in patients without comorbid IP is generally less than 5%, the frequency of AE in lung cancer with comorbid IP treated with cytotoxic chemotherapy is clearly high.

Molecular-targeted agents

Drug-induced pneumonitis among patients treated with the EGFR-TKI gefitinib has become a social problem in Japan because of its severity and mortality. A large cohort study was conducted to determine the risk factors of gefitinib-induced IP in Japanese patients (32), revealing that pre-existing IP was an independent risk factor. The rate of gefitinib-induced pneumonia was significantly higher in patients with comorbid IP than in those without IP (13.9% vs. 3.8%, $p=0.013$) (Table). Based on these data, lung cancer patients with comorbid IP are considered to have a high risk of AE caused by molecular-targeted agents.

Immune checkpoint inhibitors

Immune checkpoint inhibitors, such as PD-1/PD-L1, reportedly cause drug-induced pneumonitis in 3-4% of NSCLC patients (Table) (33, 34). Although whether or not immune checkpoint inhibitors can cause AE of comorbid IP is still unclear, a retrospective study showed that nivolumab-related pneumonitis occurred more frequently in NSCLCs with interstitial lung disease (ILD) than in those without ILD (31% vs. 12%, $p=0.014$) (35). In addition, a history of thoracic radiation is associated with an increased risk of pneumonitis during immune checkpoint inhibitor treatment (36), suggesting that pulmonary damage can potentially be a risk factor of pneumonitis induced by immune checkpoint inhibitors. The accumulation of further data is awaited.

What is the Risk of Cancer Drug Therapy Other Than Pulmonary Toxicity in IP Patients?

There have been no reports concerning whether or not lung cancer with comorbid IP increases the risk of adverse events other than pulmonary toxicity. However, since the lung reserve capacity is potentially decreased in cases with comorbid IP, it is necessary to be more cautious concerning respiratory infection during the period of myelosuppression due to cytotoxic chemotherapy. If lung cancer is accompa-

Table. Frequency of AEs or Development of Drug-induced IP.

	Frequency of AEs or drug-induced IP	
	without comorbid IP	with comorbid IP
Cytotoxic chemotherapies	<5%	10-30%
Molecular-targeted therapy (gefitinib)	3.8%	13.8%
Immune checkpoint inhibitors	3-4%	unknown

nied by CVD IP, there is a possibility that existing collagen disease may be exacerbated by an immune checkpoint inhibitor (37).

Does the Risk of Cancer Pharmacotherapy Differ Depending on the Type of Comorbid IP?

Patients with a usual interstitial pneumonia (UIP) pattern are reported to develop cytotoxic chemotherapy-triggered AE more frequently than those with a non-UIP pattern (30% vs. 8%, $p=0.005$) (38). Therefore, we should cautiously consider the indication in cases of lung cancer with comorbid UIP and be extremely careful when treating such patients with cytotoxic chemotherapy cannot be avoided. Whether or not the risk of AE induced by molecular-targeted agents or immune checkpoint inhibitors differs according to the type of IP remains to be elucidated.

Can Anti-fibrotic Agents Prevent AE?

Recently, pirfenidone and nintedanib, both of which are anti-fibrotic agents, became available for clinical use as IPF therapeutic agents, and nintedanib in particular prevents AE of IPF with a hazard ratio for time to first AE of 0.53 (95% confidence interval: 0.34-0.83; $p=0.0047$) (39). Although there are no data concerning whether or not these anti-fibrotic drugs prevent AE during drug therapy of lung cancer, a retrospective single-center study investigated the effect of the prophylactic anti-IPF agent pirfenidone on preventing post-operative AE of IPF (40). In that study, the incidence of AE was significantly lower in lung cancer patients with IPF treated with perioperative pirfenidone than in those without pirfenidone (3.2% vs. 21.1% within 90 postoperative days; $p=0.04$). A randomized controlled clinical trial is currently being conducted to determine whether or not nintedanib can prevent AE during cytotoxic chemotherapy in patients with comorbid IPF (41). If nintedanib can reduce the risk of AE due to chemotherapy, more ways to treat lung cancer with comorbid IP may become available.

What Makes It Difficult to Establish Evidence Concerning Lung Cancer with Comorbid IP?

There are a number of hurdles to establishing evidence concerning lung cancer with comorbid IP. First, although the

populations is not small, there are relatively few cases of lung cancer with comorbid IP, and majority of lung cancer do not have accompanying IP. Second, the classification of IP is not always consistent among physicians. The Official American Thoracic Society/European Respiratory Society/Japanese Respiratory Society/Latin American Thoracic Association (ATS/ERS/JRS/ALAT) Clinical Practice Guideline for the diagnosis of IPF was recently updated (42), but it might still be somewhat difficult for general physicians or oncologists to make a definite diagnosis of IPF. For example, honeycomb is an important finding among the imaging findings of IPF, but the judgment of the presence or absence of honeycomb greatly differs depending on the diagnostician (43). Third, there is extremely little information available regarding lung cancer with secondary IP, and whether or not secondary IP, such as CVD IP and pneumoconiosis, complicating lung cancer can be dealt with like idiopathic IP remains unclear. Fourth, it is difficult to quantify the extent of IP. The risk of AE is expected to differ between mild IP, which cannot be detected without CT, and symptomatic severe IP, which can be recognized on chest X-ray. In Japan, the severity of IPF is classified according to the partial pressure of arterial oxygen (PaO_2) at rest and percutaneous oxygen saturation (SpO_2) during a six-minute walk test, but it may be affected by other comorbidities, such as chronic obstructive pulmonary disease (COPD) or heart diseases, and does not always reflect the extent of IP itself. Since there are no established direct indicators for quantifying the extent of IP, it is difficult to determine the extent of comorbid IP.

How Should Lung Cancer with Comorbid IP Be Treated According to the Currently Available Information?

Cytotoxic chemotherapy

According to Japanese package inserts, irinotecan is contraindicated for IP-complicated cases, and amrubicin and gemcitabine are contraindicated in cases with symptomatic IP that can be detected by chest X-ray (8). Several small studies have shown the tolerability of regimens including paclitaxel (27), nab-paclitaxel (44), and S-1 (25). At this stage, it would be best to avoid treating patients with a UIP pattern whenever possible and use drugs that are reported to be relatively well tolerated.

Molecular-targeted therapeutic agents

Drug-induced pneumonia due to EGFR inhibitors tends to be fatal with a diffuse alveolar damage (DAD) pattern (45), and it happens more frequently in patients with comorbid IP (32). Therefore, when an EGFR gene mutation is detected in lung cancer patients with comorbid IP, patients and physicians will be forced to decide whether to treat it or to give up on targeted therapy. Fortunately, the frequency of EGFR gene mutation-positive cases with comorbid IP is not high (46), and it is said that there are many KRAS gene mutations for which molecule-targeted therapy has not been established (46), so it is rare to be placed in such a situation. However, if molecular-targeted therapy for a KRAS gene mutation is established in the future, this problem cannot be avoided.

ILD-related deaths in patients who develop drug IP account for 31.6% of those treated with gefitinib and 27.9% of patients who undergo chemotherapy (47). Gefitinib-induced ILD occurred most commonly in the first four weeks of gefitinib treatment (47). Patients with pre-existing ILD are at a high risk of developing gefitinib-induced ILD, with an odds ratio of 2.89 (32).

Immune checkpoint inhibitors

As mentioned above, there are many unclear points concerning the risk with administering immune checkpoint inhibitors to patients with IP. In a prospective study in which nivolumab was administered to six NSCLC patients with mild IP, AE did not occur in any patients (48). However, based on previous experience with cytotoxic chemotherapy and molecular-targeted agents, we believe that the use of immune checkpoint inhibitors for patients with IP should be cautiously considered as more data are accumulated going forward.

Should We Treat or Not Treat Lung Cancer with Comorbid IP?

No randomized controlled trial has shown an improvement in the overall survival of lung cancer with comorbid IP, and from a purely scientific point of view, there is no basis for recommending cancer pharmacotherapy over best supportive care. However, for example, when a patient with IP in good health develops advanced lung cancer with a high PD-L1 expression, is just best supportive care without any cancer therapy really acceptable? The establishment of a treatment strategy for lung cancer with comorbid IP is an urgent issue and must be studied more closely.

The authors state that they have no Conflict of Interest (COI).

References

- Lynch TJ, Bell DW, Sordella R, et al. Activating mutations in the epidermal growth factor receptor underlying responsiveness of non-small-cell lung cancer to gefitinib. *N Engl J Med* **350**: 2129-2139, 2004.
- Kwak EL, Bang YJ, Camidge DR, et al. Anaplastic lymphoma kinase inhibition in non-small-cell lung cancer. *N Engl J Med* **363**: 1693-1703, 2010.
- Takeuchi K, Soda M, Togashi Y, et al. RET, ROS1 and ALK fusions in lung cancer. *Nat Med* **18**: 378-381, 2012.
- Paik PK, Arcila ME, Fara M, et al. Clinical characteristics of patients with lung adenocarcinomas harboring BRAF mutations. *J Clin Oncol* **29**: 2046-2051, 2011.
- Topalian SL, Hodi FS, Brahmer JR, et al. Safety, activity, and immune correlates of anti-PD-1 antibody in cancer. *N Engl J Med* **366**: 2443-2454, 2012.
- Fehrenbacher L, Spira A, Ballinger M, et al. Atezolizumab versus docetaxel for patients with previously treated non-small-cell lung cancer (POPLAR): a multicentre, open-label, phase 2 randomised controlled trial. *Lancet* **387**: 1837-1846, 2016.
- Garon EB, Rizvi NA, Hui R, et al. Pembrolizumab for the treatment of non-small-cell lung cancer. *N Engl J Med* **372**: 2018-2028, 2015.
- Ogura T, Takigawa N, Tomii K, Kishi K. Summary of JRS statement for the treatment of lung cancer with comorbid interstitial pneumonia. *Respir Investig*. Forthcoming.
- Kinoshita A, Hirose K, Taniguchi T, et al. [Lung cancer associated with idiopathic interstitial pneumonia]. *Nihon Kyobu Shikkan Gakkai Zasshi* **28**: 852-858, 1990 (in Japanese, Abstract in English).
- Nagai A, Chiyotani A, Nakadate T, Konno K. Lung cancer in patients with idiopathic pulmonary fibrosis. *Tohoku J Exp Med* **167**: 231-237, 1992.
- Ohtsuka Y, Ukita H, Masaki Y, et al. [A prospective study of lung cancer in cases of idiopathic interstitial pneumonia (IIP)]. *Nihon Kyobu Shikkan Gakkai Zasshi* **29**: 560-565, 1991 (in Japanese, Abstract in English).
- Takeuchi E, Yamaguchi T, Mori M, et al. [Characteristics and management of patients with lung cancer and idiopathic interstitial pneumonia]. *Nihon Kyobu Shikkan Gakkai Zasshi* **34**: 653-658, 1996 (in Japanese, Abstract in English).
- Ogura T, Kondo A, Sato A, Ando M, Tamura M. [Incidence and clinical features of lung cancer in patients with idiopathic interstitial pneumonia]. *Nihon Kyobu Shikkan Gakkai Zasshi* **35**: 294-299, 1997 (in Japanese, Abstract in English).
- Baumgartner KB, Samet JM, Stidley CA, Colby TV, Waldron JA. Cigarette smoking: a risk factor for idiopathic pulmonary fibrosis. *Am J Respir Crit Care Med* **155**: 242-248, 1997.
- Khan KA, Kennedy MP, Moore E, et al. Radiological characteristics, histological features and clinical outcomes of lung cancer patients with coexistent idiopathic pulmonary fibrosis. *Lung* **193**: 71-77, 2015.
- Lee T, Park JY, Lee HY, et al. Lung cancer in patients with idiopathic pulmonary fibrosis: clinical characteristics and impact on survival. *Respir Med* **108**: 1549-1555, 2014.
- Tomassetti S, Gurioli C, Ryu JH, et al. The impact of lung cancer on survival of idiopathic pulmonary fibrosis. *Chest* **147**: 157-164, 2015.
- Vancheri C. Common pathways in idiopathic pulmonary fibrosis and cancer. *Eur Respir Rev* **22**: 265-272, 2013.
- Vancheri C. Idiopathic pulmonary fibrosis and cancer: do they really look similar? *BMC Med* **13**: 220, 2015.
- Nathan N, Giraud V, Picard C, et al. Germline SFTPA1 mutation in familial idiopathic interstitial pneumonia and lung cancer. *Hum Mol Genet* **25**: 1457-1467, 2016.
- van Moersel CH, Ten Klooster L, van Oosterhout MF, et al. SFTPA2 mutations in familial and sporadic idiopathic interstitial pneumonia. *Am J Respir Crit Care Med* **192**: 1249-1252, 2015.
- Sato T, Kondo H, Watanabe A, et al. A simple risk scoring system

- for predicting acute exacerbation of interstitial pneumonia after pulmonary resection in lung cancer patients. *Gen Thorac Cardiovasc Surg* **63**: 164-172, 2015.
23. Minegishi Y, Takenaka K, Mizutani H, et al. Exacerbation of idiopathic interstitial pneumonias associated with lung cancer therapy. *Intern Med* **48**: 665-672, 2009.
 24. Shukuya T, Ishiwata T, Hara M, et al. Carboplatin plus weekly paclitaxel treatment in non-small cell lung cancer patients with interstitial lung disease. *Anticancer Res* **30**: 4357-4361, 2010.
 25. Kenmotsu H, Naito T, Mori K, et al. Effect of platinum-based chemotherapy for non-small cell lung cancer patients with interstitial lung disease. *Cancer Chemother Pharmacol* **75**: 521-526, 2015.
 26. Collard HR, Ryerson CJ, Corte TJ, et al. Acute exacerbation of idiopathic pulmonary fibrosis. An international working group report. *Am J Respir Crit Care Med* **194**: 265-275, 2016.
 27. Minegishi Y, Sudoh J, Kuribayashi H, et al. The safety and efficacy of weekly paclitaxel in combination with carboplatin for advanced non-small cell lung cancer with idiopathic interstitial pneumonias. *Lung Cancer* **71**: 70-74, 2011.
 28. Sekine A, Satoh H, Baba T, et al. Safety and efficacy of S-1 in combination with carboplatin in non-small cell lung cancer patients with interstitial lung disease: a pilot study. *Cancer Chemother Pharmacol* **77**: 1245-1252, 2016.
 29. Watanabe N, Niho S, Kirita K, et al. Vinorelbine and cisplatin in patients with advanced non-small cell lung cancer with interstitial pneumonia. *Anticancer Res* **35**: 1697-1701, 2015.
 30. Azuma A, Nukiwa T, Tsuboi E, et al. Double-blind, placebo-controlled trial of pirfenidone in patients with idiopathic pulmonary fibrosis. *Am J Respir Crit Care Med* **171**: 1040-1047, 2005.
 31. Taniguchi H, Ebina M, Kondoh Y, et al. Pirfenidone in idiopathic pulmonary fibrosis. *Eur Respir J* **35**: 821-829, 2010.
 32. Ando M, Okamoto I, Yamamoto N, et al. Predictive factors for interstitial lung disease, antitumor response, and survival in non-small-cell lung cancer patients treated with gefitinib. *J Clin Oncol* **24**: 2549-2556, 2006.
 33. Nishino M, Giobbie-Hurder A, Hatabu H, Ramaiya NH, Hodi FS. Incidence of programmed cell death 1 inhibitor-related pneumonitis in patients with advanced cancer: a systematic review and meta-analysis. *JAMA Oncol* **2**: 1607-1616, 2016.
 34. Nishino M, Ramaiya NH, Awad MM, et al. PD-1 inhibitor-related pneumonitis in advanced cancer patients: radiographic patterns and clinical course. *Clin Cancer Res* **22**: 6051-6060, 2016.
 35. Kanai O, Kim YH, Demura Y, et al. Efficacy and safety of nivolumab in non-small cell lung cancer with preexisting interstitial lung disease. *Thorac Cancer* **9**: 847-855, 2018.
 36. Sul J, Blumenthal GM, Jiang X, He K, Keegan P, Pazdur R. FDA approval summary: pembrolizumab for the treatment of patients with metastatic non-small cell lung cancer whose tumors express programmed death-ligand 1. *Oncologist* **21**: 643-650, 2016.
 37. Leonardi GC, Gainor JF, Altan M, et al. Safety of programmed death-1 pathway inhibitors among patients with non-small-cell lung cancer and preexisting autoimmune disorders. *J Clin Oncol* **36**: 1905-1912, 2018.
 38. Kenmotsu H, Naito T, Kimura M, et al. The risk of cytotoxic chemotherapy-related exacerbation of interstitial lung disease with lung cancer. *J Thorac Oncol* **6**: 1242-1246, 2011.
 39. Richeldi L, Cottin V, du Bois RM, et al. Nintedanib in patients with idiopathic pulmonary fibrosis: Combined evidence from the TOMORROW and INPULSIS((R)) trials. *Respir Med* **113**: 74-79, 2016.
 40. Iwata T, Yoshida S, Fujiwara T, et al. Effect of perioperative pirfenidone treatment in lung cancer patients with idiopathic pulmonary fibrosis. *Ann Thorac Surg* **102**: 1905-1910, 2016.
 41. Otsubo K, Kishimoto J, Kenmotsu H, et al. Treatment rationale and design for J-SONIC: a randomized study of carboplatin plus nab-paclitaxel with or without nintedanib for advanced non-small-cell lung cancer with idiopathic pulmonary fibrosis. *Clin Lung Cancer* **19**: e5-e9, 2018.
 42. Raghu G, Remy-Jardin M, Myers JL, et al. Diagnosis of idiopathic pulmonary fibrosis. An Official ATS/ERS/JRS/ALAT clinical practice guideline. *Am J Respir Crit Care Med* **198**: e44-e68, 2018.
 43. Watadani T, Sakai F, Johkoh T, et al. Interobserver variability in the CT assessment of honeycombing in the lungs. *Radiology* **266**: 936-944, 2013.
 44. Usui Y, Kenmotsu H, Mori K, Ono A. A multicenter single-arm phase II study of nab-paclitaxel/carboplatin for non-small cell lung cancer patients with interstitial lung disease. *Ann Oncol* **29** (suppl 8): viii493-viii547, 2018.
 45. Min JH, Lee HY, Lim H, et al. Drug-induced interstitial lung disease in tyrosine kinase inhibitor therapy for non-small cell lung cancer: a review on current insight. *Cancer Chemother Pharmacol* **68**: 1099-1109, 2011.
 46. Masai K, Tsuta K, Motoi N, et al. Clinicopathological, immunohistochemical, and genetic features of primary lung adenocarcinoma occurring in the setting of usual interstitial pneumonia pattern. *J Thorac Oncol* **11**: 2141-2149, 2016.
 47. Kudoh S, Kato H, Nishiwaki Y, et al. Interstitial lung disease in Japanese patients with lung cancer: a cohort and nested case-control study. *Am J Respir Crit Care Med* **177**: 1348-1357, 2008.
 48. Fujimoto D, Morimoto T, Ito J, et al. A pilot trial of nivolumab treatment for advanced non-small cell lung cancer patients with mild idiopathic interstitial pneumonia. *Lung Cancer* **111**: 1-5, 2017.

The Internal Medicine is an Open Access journal distributed under the Creative Commons Attribution-NonCommercial-NoDerivatives 4.0 International License. To view the details of this license, please visit (<https://creativecommons.org/licenses/by-nc-nd/4.0/>).