

*Case Report*

## The Novel Eryngii Method of Nipple Reduction for Female-to-Male Transsexuals

Toru Sakurai<sup>a</sup>, Toshiyuki Watanabe<sup>a</sup>, Kensuke Manako<sup>a</sup>, Syo Komagoe<sup>b</sup>,  
Yuko Mukai<sup>a</sup>, Yoshiro Kimata<sup>a</sup>, and Yuzaburo Namba<sup>c</sup>

*Departments of<sup>a</sup>Plastic and Reconstructive Surgery, <sup>c</sup>Gender Center, Okayama University Hospital, Okayama 700-8558, Japan,  
<sup>b</sup>Department of Plastic Surgery, Okayama Saiseikai General Hospital, Okayama 700-8511, Japan*

Mastectomy is usually the first and most important surgical procedure in female-to-male (FTM) individuals with gender identity disorder. Nipple reduction is also important in the process of reconstructing the chest wall for a more male appearance. If the nipples remain large after a mastectomy, the results may be disappointing to many FTM transsexuals. Nipple reduction enables these individuals to go to the beach or Japanese public baths, where they may go topless in public. We therefore consider that nipple reduction is indicated for all FTM transsexuals who desire it. There are a variety of methods for the reduction of enlarged nipples for women or non-FTM patients, but only a few reports have described the process used to create masculine-appearing nipples for FTM transsexuals. We developed a novel technique called the Eryngii method for creating male-like nipples using a 4-mm diameter dermal punch knife. The name of the method refers to the Eryngii king trumpet mushroom, which the nipple resembles after the surgical process. The main strength of this method is that it permits the creation of ideal nipples without difficulty. Here we introduce the technique and discuss our history of surgical methods for nipple reduction, including improvements and elaborations.

**Key words:** nipple reconstruction, female-to-male, transmen, mastectomy, top surgery

We have performed sex reassignment surgery (SRS) in patients with gender identity disorder (GID) since 2001. Over the nearly 2 decades since we began performing SRS, we have observed an increasing number of patients who desire nipple reduction surgery as well as mastectomies. Needless to say, a mastectomy is essential for chest wall masculinization [1-3]. Nipple reduction is also an important procedure used to achieve a male-appearing chest, as it enables female-to-male (FTM) transsexuals to go to the beach or visit a public bath topless. A mastectomy alone with large nipples remaining after the procedure is often not acceptable to FTM transsexuals. We therefore consider that nipple reduction is indicated for all FTM transsexuals

who desire it. We usually perform the nipple reduction after the mastectomy.

There have been only a few reports describing nipple reduction for FTM transsexuals to create masculine-appearing nipples [2-4]. We suspect that plastic surgeons who perform such reductions do so using their own techniques. We developed a new technique that we named the Eryngii method (after the Eryngii king trumpet mushroom) that uses a 4-mm diameter dermal punch commonly used for dermal biopsies. This method can create ideal nipples without difficulty. We herein report this method and our history of surgical strategies for nipple reduction.

**Surgical technique.** We have used our novel Eryngii method for FTM patients who requested nipple

Received February 18, 2019; accepted September 19, 2019.

\*Corresponding author. Phone: +81-86-235-7241; Fax: +81-86-235-7210  
E-mail: mm040001@nms.ac.jp (T. Sakurai)

Conflict of Interest Disclosures: No potential conflict of interest relevant to this article was reported.

reduction without mastectomy as well as for FTM patients after mastectomy (excluding those who underwent a double incision mastectomy with free nipple grafting). All procedures were performed under local anesthesia with 1% lidocaine.

The details of the Eryngii nipple reduction method are as follows.

(1) A 4-mm diameter circle is drawn at the tip of the nipple and a circle is drawn around the base of the nipple (Figs. 1a, 2a).

(2) A 4-mm diameter dermal punch knife is used to hollow out the tip of the nipple as designed. The knife is gently twisted and pushed into the nipple only as far as needed to circumferentially incise the nipple epidermis (Fig. 2b).

(3) The base of the circle line is incised, and a scalpel or scissors is used to excise the lateral wall tissue of the nipple (Figs. 1b, 2c).

(4) The lateral tissue is excised to the extent that the new nipple does not rebound out when pushed upon (Fig. 1c).

(5) The nipple is sutured to the areola with 6-0 nylon sutures (Fig. 1d). The tip of the nipple should be sutured and slightly prominent above the surface. Although part of the lateral tissue of the nipple is left as a raw exposed surface, it can be expected to heal conservatively (Figs. 1e, 2d).

(6) Antibacterial ointment is applied to the nipple and the area is dressed with gauze. The sutures are removed 3-4 weeks postoperatively.

### Case Presentation

During the year from May 2017 until May 2018, we treated 6 patients (12 nipples) with this method (1 patient without mastectomy, 5 with mastectomy). All patients were diagnosed and treated according to diagnostic and therapeutic guidelines for patients with gender identity disorder [5]. The mean patient age was 27.5 years ( $\pm 4.4$ ). The mean body mass index was 22.1 ( $\pm 1.8$ ). The smoking rate was 67%. All patients had undergone hormone treatment prior to the Eryngii nipple reduction and had no medical history relevant to the procedure. No complications were observed (Table 1). We were able to confirm that male-like nipples and chest walls were achieved in all cases at 1 month after the surgery. This study was approved by the local Ethical Committee Board (No.1808-030). Informed consent

was obtained from all patients, including written consent to publish images.

**Case 1.** A 23-year-old FTM transsexual patient desired a nipple reduction. He had already undergone a mastectomy with a sub-areolar incision. The Eryngii method was used for nipple reduction, under local anesthesia. The result was satisfactory, and male-like nipples and chest wall were obtained (Fig. 3).

**Case 2.** A 35-year-old FTM transsexual who had not undergone a mastectomy wanted to reduce the nipples only because the breasts were already small. Nipple reduction surgery was performed using the Eryngii method. After the surgery, slight swelling of the breast was seen, but since he was left with male-like nipples and a male-like chest, he was satisfied (Fig. 4).

### Discussion

The ideal male nipple has been reported as 4 mm in diameter [6], while that of the female nipple is 10 mm in diameter with an 8-mm height [7], although in actuality female nipples vary in size and are often larger than 10 mm. Mastectomy has the potential to reduce the psychological burden of FTM transsexuals and improve their quality of life. If the nipples of FTM transsexuals remain female-like after a mastectomy, the results are often not acceptable to them, especially when they wear a T-shirt or show their chests at the beach. Nipple reduction is thus indicated for all FTM transsexuals who desire it. Some (as in our Case 2) are small-breasted and require only nipple reduction to achieve satisfactory outcomes. These results suggest that nipple reduction is key for patients who want to achieve a chest wall with male-contouring.

Although several studies have described nipple reduction methods for women or non-FTM transsexuals [7-10], few studies have described nipple reduction specifically in FTM transsexuals, or the differences between nipple reduction methods for FTM transsexuals and those for non-FTM transsexuals. Breast resection and nipple areolar complex (NAC) transplantation have been commonly performed for FTM transsexuals in the U. S. and Europe [11, 12], whereas nipple reduction is less commonly performed. It is important to preserve the duct and the three-dimensional structure in order to preserve lactation in a nipple reduction for non-FTM patients, and complicated flaps may be used for this purpose [6-9]. However, lactation preservation

is not an issue for FTM transsexuals; the important point is the marked reduction of nipple size. Takayanagi *et al.* reported good results for nipple reduction for FTM transsexuals [4]. Their method includes somewhat complex techniques. As described below, we have performed and revised many methods [13], ultimately developing this Eryngii method. This method involves easy manipulation and leads to satisfactory outcomes.

We next describe our history of nipple reconstruction.

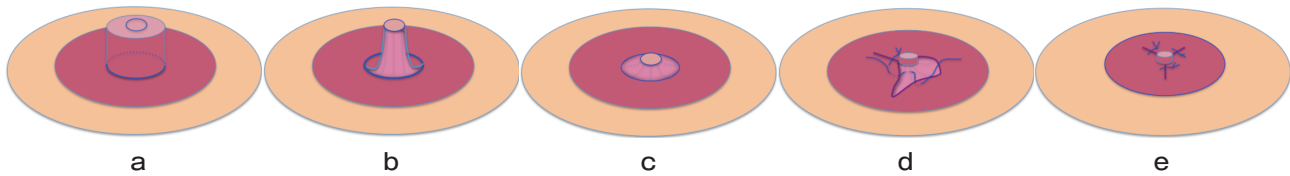
(1) Horizontal and wedge resection [13] (Fig. 5)

We initially used this method, in which a semicircular areola is incised and the other semicircular side is

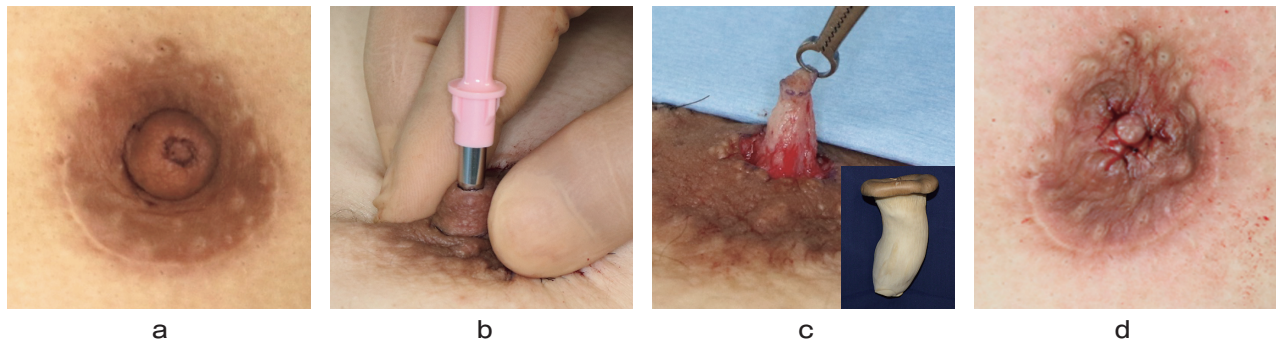
horizontally incised in a wedge shape. A certain amount of the diameter is reduced, whereas the diameter of the nipple is not decreased. We observed that the new nipples were only reduced to half their original size, and still larger than male-appearing nipples.

(2) The 270° incision method [13] (Fig. 6)

In this method, a 270° arc around the tip of the nipple is excised. The remaining 90° of the nipple is folded down and sutured. Although this method can reduce the new nipple to one-quarter its original size, it results in a decreased nipple projection. We found that the projection of the new nipple became so dull using this method that the surgery border between the nipple and



**Fig. 1** The Eryngii method (named after a king trumpet mushroom). **a**, Preoperative design; **b**, Using a 4-mm diameter dermal punch knife, make an incision at the base circle line and use a scalpel or scissors to de-epithelialize the lateral wall of the nipple; **c**, Excise the lateral tissue to the extent that the new nipple does not rebound out when pushed upon; **d**, Suture the nipple to the areola using 6-0 nylon sutures; **e**, Part of the lateral tissue of the nipple will remain exposed, but this is expected to heal with conservative management.



**Fig. 2** **a**, Preoperative design; **b**, Using a 4-mm diameter dermal punch knife, twist and push it gently into the nipple to circumferentially incise the epidermis; **c**, The nipple after removal of the residual tissue circumferentially, and an Eryngii (king trumpet mushroom); **d**, Completed nipple reduction.

**Table 1** Patient Details

	Age	BMI	Mastectomy	Smoking	Hormonal Therapy	History	Complications
Case 1	24	19.1	Without Mastectomy	—	+	—	—
Case 2	35	21.9	Our Hospital	+	+	—	—
Case 3	32	24.9	Other Clinic (Japan)	+	+	—	—
Case 4	26	24	Other Hospital (Thailand)	+	+	—	—
Case 5	24	21.6	Other Clinic (Japan)	+	+	—	—
Case 6	24	21.3	Other Clinic (Japan)	—	+	—	—
Mean ± SD or %	27.5 ± 4.4	22.1 ± 1.8		67%	100%	0%	0%

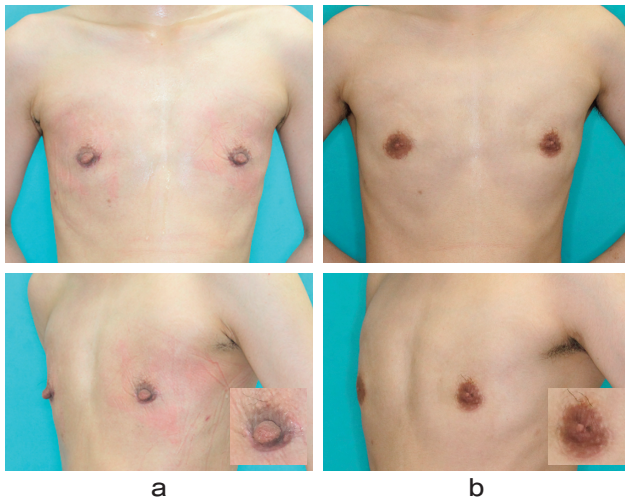


Fig. 3 a, Chest wall after mastectomy with a semicircular approach but before the nipple reduction; b, Appearance 1 month after the nipple reduction.

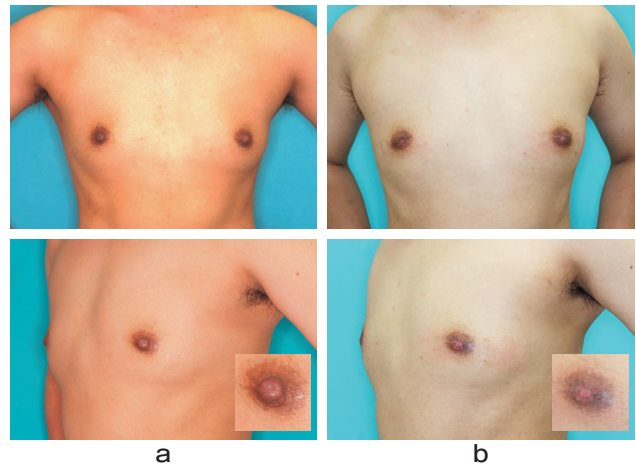


Fig. 4 a, Chest wall before the nipple reduction without a mastectomy; b, Appearance 1 month after the nipple reduction without a mastectomy.

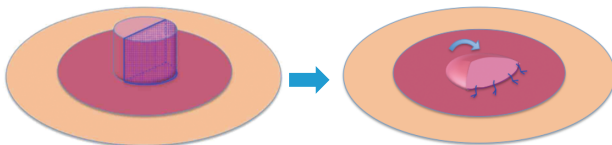


Fig. 5 The horizontal and wedged resection method.

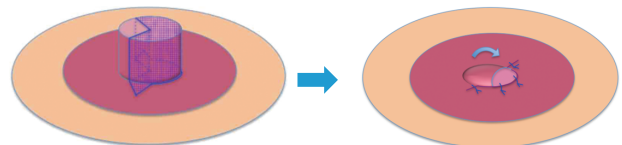


Fig. 6 The 270° incision method.

the areola became obscure.

(3) The Eryngii method (Fig. 1)

As mentioned above, the Eryngii method has become our standard technique. Figures 1c and 2c show the nipple after de-epithelization and the removal of the residual circumferential tissue. The nipple resembles an Eryngii king trumpet mushroom, after which we named the procedure. In the early years of performing this procedure, after making the circumferential excision, we added 2 triangular excisions in the areola and thus we did not create “dog ears.” Today we perform only the circumferential excisions. This results in dog ears, which resemble areolar glands and leads to a good aesthetic shape. The circular scar will become slightly contracted after the surgery, which makes it possible to clear the border between the nipple and the areola. If there are slight differences in nipple size, they can be adjusted by expanding the circumferential excision.

The nipple sizes among women vary considerably. If the nipple size is felt to be too large, the former procedures we used cannot make the nipple appear male-like.

Using the Eryngii method, 4-mm diameter nipples can be created regardless of the size difference. Although the reported mean diameter of male nipples in a U.S. study was 6 mm [14], we use 4 mm. This is because FTM transsexuals often have a smaller physique than cis males. In addition, the 4-mm diameter nipple also seems to satisfy the general aesthetic expectations of most males [6]. A 5-mm diameter dermal punch knife can be used for patients with a larger physique.

**Insurance coverage:** One problem for FTM transsexuals in Japan is that the surgical cost of nipple reduction is not covered by health insurance. Japan’s Health Ministry has allowed public health insurance to cover SRS since April 2018 but it does not yet allow nipple reduction insurance coverage. Nipple reduction is also important in the process of reconstructing the chest wall with a male appearance. This will be a key challenge for public medical insurance in the future.

In conclusion, nipple reduction and mastectomy are essential for creating a male-like chest for FTM transsexuals. By changing and revising the procedures over

time, we eventually developed the Eryngii method, which avoids complex manipulation and results in satisfactory outcomes. We hope this nipple reduction method will become increasingly common worldwide.

### References

1. Lindsay WR: Creation of a male chest in female transsexuals. *Ann Plast Surg* (1979) 3: 39–46.
2. Monstrey S, Selvaggi G, Ceulemans P, Van Landuyt K, Bowman C, Blondeel P, Hamdi M and De Cuypere G: Chest-wall contouring surgery in female-to-male transsexuals: a new algorithm. *Plast Reconstr Surg* (2008) 121: 849–859.
3. Ammari T, Sluiter EC, Gast K and Kuzon WM Jr: Female-to-Male Gender-Affirming Chest Reconstruction Surgery. *Aesthet Surg J* (2019) 39: 150–163.
4. Takayanagi S and Nakagawa C: Chest wall contouring for female-to-male transsexuals. *Aesthetic Plast Surg* (2006) 30: 206–212.
5. The Japanese Society of Psychiatry and Neurology: The diagnostic and therapeutic guidelines for patients with gender identity disorder, 4th ED, *Seishin Shinkeigaku Zasshi* (2012) 114: 1250–1266 (in Japanese).
6. Mu D, Luan J, Guo X and Xu B: Male Nipple Reduction With a Simple Circular-Flap Technique. *Aesthet Surg J* (2016) 36: 113–116.
7. Yijia Y, Liyuan W, Yichen S, Wei X, Jiabin H and Jinghong X: Windmill Flap Nipple Reduction: A New Method of Nipple Plasty *Aesthet Surg J* (2017) 41: 788–792.
8. Cheng MH, Smartt JM, Rodriguez ED and Ulusal BG: Nipple reduction using the modified top hat flap. *Plast Reconstr Surg* (2006) 118: 1517–1525.
9. Jin US and Lee HK: Nipple reduction using circumcision and wedge excision technique. *Ann Plast Surg* (2013) 70: 154–157.
10. Lai YL and Wu WC: Nipple reduction with a modified circumcision technique. *Br J Plast Surg* (1996) 49: 307–309.
11. Vigneswaran N, Lim J, Lee HJ, Ong WC, Rasheed MZ and Lim TC: A novel technique with aesthetic considerations in female-to-male transsexuals nipple areola complex reconstruction. *J Plast Reconstr Aesthet Surg* (2013) 66: 1805–1807.
12. Frey JD, Yu JZ, Poudrier G, Motosko CC, Saia WV, Wilson SC and Hazen A.: Modified Nipple Flap with Free Areolar Graft for Component Nipple-Areola Complex Construction: Outcomes with a Novel Technique for Chest Wall Reconstruction in Transgender Men. *Plast Reconstr Surg* (2018) 142: 331–336.
13. Namba Y, Tsutsui T, Kimata Y and Koshima I: Mastectomy for female to male transsexuals *Jpn J Plast Reconstr Surg* (2006) 49: 985–991 (in Japanese).
14. Agarwal CA, Wall VT, Mehta ST, Donato DP and Walzer NK: Creation of an Aesthetic Male Nipple Areolar Complex in Female-to-Male Transgender Chest Reconstruction. *Aesthetic Plast Surg* (2017) 41: 1305–1310.