

Mutation-in-Brief

Novel *AVPR2* variant in a male infant with nephrogenic diabetes insipidus who showed delayed head control

Kosei Hasegawa¹, Hiromi Ihoriya², Natsuko Futagawa^{1,3}, Yousuke Higuchi^{1,3}, Hiroki Tsuchiya⁴, Takashi Shibata⁴, Yumiko Hayashi⁴, Katsuhiro Kobayashi⁵, and Hirokazu Tsukahara³

¹Department of Pediatrics, Okayama University Hospital, Okayama, Japan

²Advanced Critical Care and Emergency Center, Okayama University Hospital, Okayama, Japan

³Department of Pediatrics, Okayama University Graduate School of Medicine Dentistry, and Pharmaceutical Sciences, Okayama, Japan

⁴Department of Child Neurology, Okayama University Hospital, Okayama, Japan

⁵Department of Child Neurology, Okayama University Graduate School of Medicine, Dentistry, and Pharmaceutical Sciences, Okayama, Japan

Key words: developmental delay, polyuria, polydipsia, fever, poor weight gain

Introduction

Congenital nephrogenic diabetes insipidus (NDI) is a rare disease caused by genetic mutations in *AVPR2* or *AQP2* (1). *AVPR2* is located at the Xq28 locus, and it encodes arginine vasopressin receptor 2 (AVPR2). Mutations in *AVPR2* have been associated with X-linked NDI. *AQP2* is located at the 12q13.12 locus, and it encodes the water transporter aquaporin-2. Mutations in *AQP2* result in autosomal NDI. Here, we describe a male infant with a novel *AVPR2* variant who was referred to our hospital due to delayed head control.

Case Report

A 5-mo-old boy was referred to the Department of Child Neurology in Okayama University Hospital (Okayama, Japan) due to delayed head control. He was born to non-consanguineous parents. His birth weight was 3630 g (+1.39 SD) and birth length was 50.8 cm (+0.86 SD). He showed no signs of asphyxia. A recurrent fever of unknown origin was observed beginning at 2 mo of age. Poor weight gain was observed at 3 mo of age. Notably, he did not take any medications.

At his first visit to our hospital, the patient's length was 62.6 cm (−1.55 SD) and weight was 6190 g (−1.82 SD). His heart rate was 128 bpm, and his body temperature was 36.8°C. He was dehydrated, and his head control was incomplete. Laboratory examination revealed that his sodium level and serum osmolality were elevated, and his urinary osmolality and specific gravity were noticeably low. Head magnetic resonance imaging scanning revealed that high posterior lobe intensity was absent

Received: May 13, 2019

Accepted: August 2, 2019

Corresponding Author: Kosei Hasegawa M.D., Ph.D., Department of Pediatrics, Okayama University Hospital, Shikata-cho 2-5-1, Kita-ku, Okayama 700-8558, Japan
E-mail: haseyan@md.okayama-u.ac.jp

This is an open-access article distributed under the terms of the Creative Commons Attribution Non-Commercial No Derivatives (by-nc-nd) License <<http://creativecommons.org/licenses/by-nc-nd/4.0/>>.

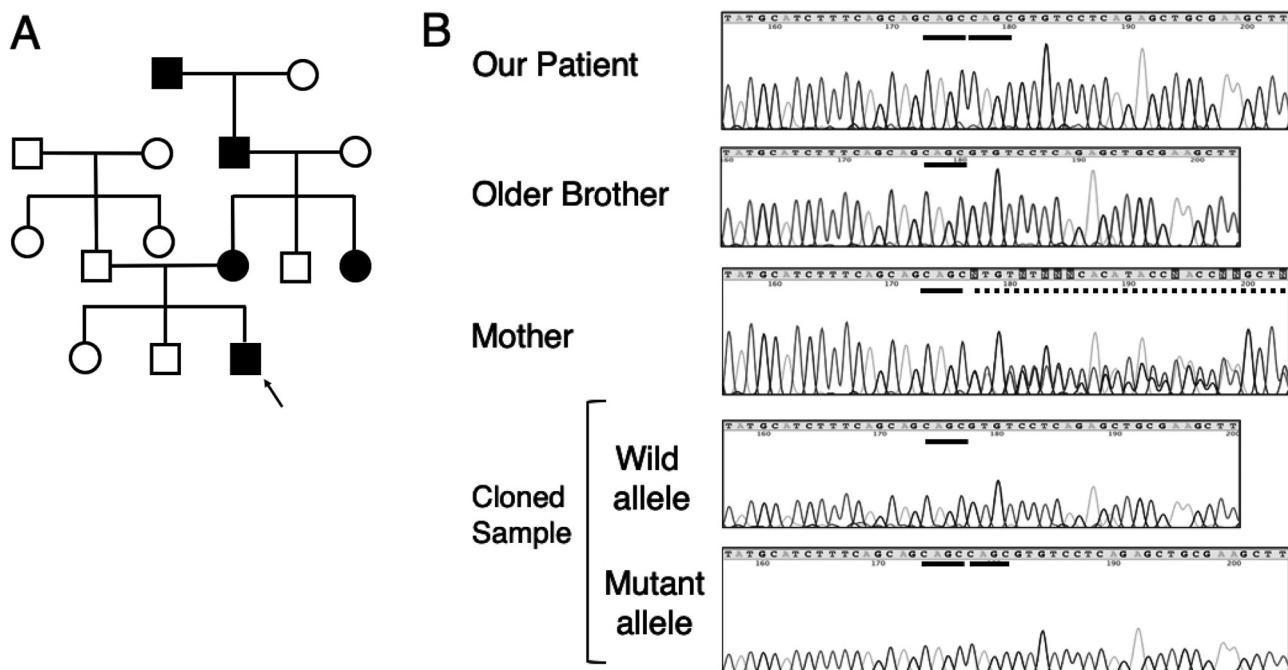


Fig. 1. A: Family tree of our patient (arrow). Black square and black circle indicate family members with polydipsia and polyuria, respectively. Arrow indicates our patient. B: Results of mutation analysis. Our patient showed hemizygous duplication of four base pairs (c.990_993 dup CAGC; single bold line indicates CAGC). His older brother did not show this duplication. His mother was heterozygous for the wild-type allele and the four-base pair duplication (dotted line).

in T1-weighted images. However, the pituitary stalk was intact, and no other abnormalities were identified. These findings were indicative of diabetes insipidus. Water deprivation test with vasopressin challenge test resulted in no urine osmolality increase and no urine volume decrease. Moreover, the AVP level at admission was extremely high (114 pg/mL; reference range; 0.0–4.2 pg/mL). Based on these findings, we diagnosed the patient with congenital NDI. His urine volume decreased, his weight increased, and head control was achieved after initiation of hydrochlorothiazide.

Assessment of the patient's family history revealed that his mother had polydipsia and polyuria from infancy until the present day (Fig. 1A). She also had increased levels of sodium of unknown origin during each of her three pregnancies. Furthermore, the patient's maternal grandfather, maternal great-

grandfather, and maternal aunt had histories of polyuria and polydipsia. We suspected that our patient had familial NDI and, thus, conducted a genetic analysis.

Mutational Analysis

Genetic analysis was approved by the ethical committee of Okayama University Hospital and conducted in accordance with the 1975 Declaration of Helsinki and subsequent amendments. Informed consent for genetic analysis was obtained from the patient's mother.

We identified a hemizygous four-base pair duplication in exon 3 of *AVPR2* (c.990_993 dup CAGC, Fig. 1B). This four-base pair duplication results in early termination (p.Val332Gln Fs26X). This variant was previously unreported, and it is not present in the 1000 Genomes Project databases (<http://www.internationalgenome>).

org/1000-genomes-browsers), the Human Genetic Variation Database (<http://www.hgvd.genome.med.kyoto-u.ac.jp>), or the Exome Aggregation Consortium Server (<http://exac.broadinstitute.org>). This variant is considered to be likely pathogenic based on ACMG criteria (PS1, PM2 and PM4). We suspected that the patient's mother was heterozygous for the wild-type allele and the four-base pair duplication. Thus, an amplicon obtained from the mother was cloned into a PCR[®] 4-TOPO[®] vector using the TOPO[®] TA Cloning[®] Kit for Sequencing (Thermo Fisher Scientific, Waltham, MA, USA), and each transformant was, subsequently, sequenced. The results confirmed heterozygosity for the wild-type allele and the four-base pair duplication. Since the patient's mother suspected that the patient's older brother had polydipsia, we also analyzed the patient's older brother. However, the patient's brother did not carry the four-base pair duplication. Notably, we did not analyze *AQP2* in our patient, and we did not perform genetic analysis for his father, older sister, maternal aunt, maternal grandfather, or maternal great-grandfather.

Discussion

We identified a novel *AVPR2* variant in a patient with familial congenital NDI. Duplication variants are relatively rare among X-linked NDI patients: insertion *AVPR2* variants were found in only about 5% of large cohort (1) and Japanese patients (2).

There are five classes of loss of function mutations in *AVPR2* (1). Class I mutations result in unstable mRNA, which undergoes nonsense-mediated RNA decay. Class II mutations cause misfolding of receptors, and these mutant receptors remain in the endoplasmic reticulum. Class III mutations also cause receptor misfolding. Class III receptors reach the plasma membrane and react with AVP, but subsequent interactions with G proteins and cAMP production are impaired. Class IV mutations also result in misfolded receptors

that reach the plasma membrane, but result in incomplete AVP binding. Class V mutations cause mis-sorting to incorrect cellular compartments. A duplication of four bases in exon 3 of *AVPR2* causes early termination. However, this is the final exon, which might avoid nonsense-mediated RNA decay (3). Residue 332 is located in an intracellular domain that does not bind to AVP. Therefore, the variant in our patient may lose its function via a non-class I mechanism. Functional analysis is needed to clarify the pathophysiology of this variant.

Congenital NDI is generally identified by the presence of DI symptoms like polyuria, polydipsia, fever, and poor weight gain (2). The patient whose case is reported here was referred to the department of Child Neurology in our hospital because of delayed head control, poor weight gain, and fever. After treating his dehydration, he gained head control and his development proceeded normally. We consider delayed motor development in infancy to be an important clinical symptom of congenital NDI.

The patient's mother had a heterozygous *AVPR2* variant. She demonstrated a high sodium level during each of her pregnancies, but her sodium levels were normal before pregnancy and after birth for all children. In gestational DI, urinary volume increases during pregnancy because of increased clearance of AVP by placental vasopressinase, a cystine aminopeptidase that strongly degrades AVP (4). Although inactivation of the X chromosome was not analyzed in the patient's mother, AVP resistance and degradation by vasopressinase, might have contributed to her high sodium levels during pregnancy.

In conclusion, we identified a novel *AVPR2* variant in a patient with familial congenital NDI. Common symptoms of DI were observed, including polyuria, polydipsia, poor weight gain, and fever, and delayed motor development was also observed during infancy.

Conflict of Interest: The authors declare that they have no conflict of interest.

Acknowledgement

We thank the patient and his family for participating in this study.

References

1. Moeller HB, Rittig S, Fenton RA. Nephrogenic diabetes insipidus: essential insights into the molecular background and potential therapies for treatment. *Endocr Rev* 2013;34: 278–301. [\[Medline\]](#) [\[CrossRef\]](#)
2. Fujimoto M, Okada S, Kawashima Y, Nishimura R, Miyahara N, Kawaba Y, *et al.* Clinical overview of nephrogenic diabetes insipidus based on a nationwide survey in Japan. *Yonago Acta Med* 2014;57: 85–91. [\[Medline\]](#)
3. Holbrook JA, Neu-Yilik G, Hentze MW, Kulozik AE. Nonsense-mediated decay approaches the clinic. *Nat Genet* 2004;36: 801–8. [\[Medline\]](#) [\[CrossRef\]](#)
4. Ananthakrishnan S. Diabetes insipidus during pregnancy. *Best Pract Res Clin Endocrinol Metab* 2016;30: 305–15. [\[Medline\]](#) [\[CrossRef\]](#)