

Case Report

## Efficacy of Oral Care Provided by Interprofessional Collaboration for a Patient with Esophageal Cancer Associated with Post-polio Syndrome during Neoadjuvant Chemotherapy

Keiko Takahashi-Arimasa<sup>a</sup>, Reiko Kohno-Yamanaka<sup>b\*</sup>, Yoshihiko Soga<sup>b</sup>, Rumi Miura<sup>a</sup>, and Manabu Morita<sup>c</sup>

<sup>a</sup>Dental Hygienist Team, Division of Medical Technology, <sup>b</sup>Division of Hospital Dentistry, Central Clinical Department, Okayama University Hospital, <sup>c</sup>Department of Preventive Dentistry, Okayama University Graduate School of Medicine, Dentistry and Pharmaceutical Sciences, Okayama 700-8558, Japan

Preoperative oral care is helpful to prevent postoperative complications in patients who are undergoing esophagectomy. Here, we report the case of an 81-year-old Japanese man with an upper limb disability caused by post-polio syndrome who was receiving neoadjuvant chemotherapy for esophageal cancer. He had poor oral health status and developed oral complications as a side effect of chemotherapy. He could not brush his teeth by himself. However, infection control by oral care provided by an interprofessional collaboration successfully improved his oral hygiene, and his follow-up involved no severe complications. Interprofessional collaboration is useful especially for patients with upper limb disability.

**Key words:** esophageal cancer, preoperative oral care, post-polio syndrome, neoadjuvant chemotherapy, oral mucositis

Surgical intervention for esophageal cancer is site-specifically impacted by oral infection. Oral pathogens could be causes of postoperative complications in esophagectomy including aspiration pneumonia and surgical site infection. Preoperative oral care is thus helpful to improve the prognosis of patients who are undergoing an esophagectomy. For instance, it is an effective and easy method to prevent postoperative pneumonia in such patients [1,2]. Occlusal support is also an important factor for accelerating recovery after surgery [3]. However, it is difficult for patients with post-polio syndrome (PPS) to brush their teeth, due to their progressive muscle weakness. In such cases, the support of medical personnel and family members is indispensable for the provision of proper oral hygiene.

Here, we report a patient with esophageal cancer associated with PPS whose oral hygiene during neoadjuvant chemotherapy was successfully improved by infection control by oral care provided by an interprofessional collaboration, and he was followed up without severe complications.

### Case Report

An 81-year-old Japanese man visited an area hospital with the chief complaints of aphagia and abdominal discomfort. He was diagnosed with lower esophageal cancer by upper gastrointestinal endoscopy. He was advised to undergo an esophagectomy and was referred to the core hospital of Okayama Prefecture. Contrast-enhanced computed tomography and positron emission

Received June 4, 2018; accepted October 15, 2018.

\*Corresponding author. Phone & Fax: +81-86-235-6588

E-mail: reiko\_y@md.okayama-u.ac.jp. (R. Yamanaka)

Conflict of Interest Disclosures: No potential conflict of interest relevant to this article was reported.

the Department of Neurology, Okayama University Hospital for further examination. A neurological examination showed the dominant form of proximal muscular atrophy of the bilateral upper limbs and left lower limb, increased tendon reflexes and pathological reflexes. His extraocular movements were full and he did not present dysarthria, dysphagia, tongue atrophy, or fasciculation. Laboratory data did not show creatine kinase elevation. Magnetic resonance imaging (MRI) of the cervical spine did not show any abnormal findings of the ventral horn cells. Needle electromyography showed no neurogenic change. Although his cerebrospinal fluid was negative for poliovirus type 1-3 antibodies, he was clinically diagnosed with PPS. ALS was not completely ruled out, and cranial MRI revealed asymptomatic cerebral infarctions. Antiplatelet drugs were then administered. Thereafter, the patient was followed up by the Department of Neurology, Okayama University Hospital.

He was admitted to the Department of Gastroenterological Surgery, Okayama University Hospital, to receive neoadjuvant chemotherapy (NAC) for esophageal cancer considering the radical esophagectomy at the age of 81 years. The neurologist did not consider PPS as a short-term prognostic factor of the patient's survival because of its very slow progression. The NAC regimen consisted of fluorouracil (2,000 mg/day on days 1, 3, and 4 and 4,000 mg/day on day 5) and cisplatin (60 mg/day on day 1) (Fig. 1).

On day 1 of the NAC, he was referred to the Perioperative Management Center (PERIO) for management during the preoperative period. His body mass

[illegible]

**Fig. 1** Changes in the involvement of each professional during the patient's neoadjuvant chemotherapy.

index was 16.1 with a height of 159 cm and weight of 40.8 kg. He had developed PPS and had upper and lower limbs weakness. He was able to walk while holding onto something. He had been able to raise his hands only to hip level and had not been able to brush his teeth by himself. However, he was stubborn and irritable and unwilling to accept help.

On day 1 of the NAC, the PERIO nurse consulted the dentist in the PERIO's dental section about preventing oral complications during chemotherapy, and the dentist attempted to address the patient's dental problem. However, the patient refused treatment from anyone other than his primary care dentist and did not give informed consent. The PERIO dentist consulted with the patient's primary care dentist, and his primary care dentist advised the patient to consult the dentistry department in the hospital during his hospitalization. He finally agreed to receive oral care on day 6 of the NAC.

The number of white blood cells (WBC), especially neutrophils (NE) gradually increased from day 1 of the NAC, and he had a fever of  $>37^{\circ}\text{C}$  on days 1, 2, and 5 of the NAC (Fig. 2). He had 6 residual teeth (33-43), all of which were connected by a full metal crown. He was using a maxillary complete denture and a mandibular partial denture. His lips and oral cavity were dry. He

had thick white moss on his tongue and white spots on the vestibulum oris and buccal mucosa. He also had an ulceration on the inside of the lower lip. His oral and denture hygiene were poor. He was clinically diagnosed as having oral mucositis Grade 3 according to the U.S. National Institutes of Health Common Terminology Criteria for Adverse Events version 3.0 [4], oral pseudomembranous candidiasis, and mouth dryness induced as a side effect of NAC.

Two days later, *Candida albicans* (+++) and *Candida glabrata* (+++) were identified by a laboratory culture test on oral mucosal smear. Although the patient refused swallowing testing by the otolaryngologist or dentist, the neurologist had confirmed that he did not exhibit bulbar palsy (tongue atrophy), dysarthria, or dysphagia. On the same day, we developed an oral care plan based on our diagnosis and began to provide treatment and care.

The dentist administered oral amphotericin B (Halizon Syrup<sup>®</sup> 100 mg/mL, Fuji Pharma, Tokyo) 300 mg/day for 8 days, and prescribed dimethyl isopropylazulene ointment (Azunol<sup>®</sup> Ointment 0.033%, Nippon Shinyaku, Kyoto, Japan) for the patient. Following the diagnosis and instructions by dentists, dental hygienists provided oral care for the patient including denture cleaning, tooth cleaning of his

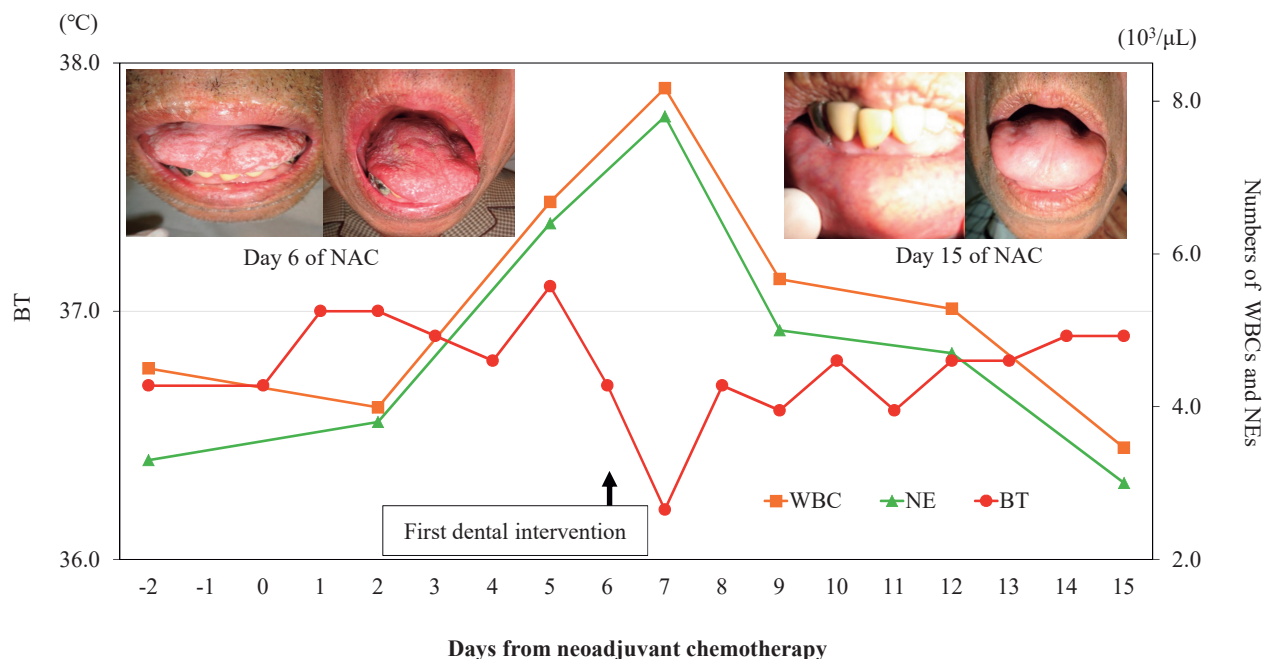


Fig. 2 Changes in the numbers of WBCs, NEs, body temperature (BT) and oral status during the neoadjuvant chemotherapy.

remaining teeth with a toothbrush, lip moisturizing with Vaseline, and oral cavity moisturizing with a moisturizing mouth spray (Butler Gel Spray®, Sunstar, Osaka, Japan). On day 12 of the NAC, dental technicians performed professional cleaning and denture polishing. Ward nurses were instructed in proper oral care and performed daily oral care for the patient.

The patient was emotionally unstable and had a tendency of day-night reversal. He did not have the mental capacity to give informed consent, and he often shouted at medical personnel or was depressed. It was difficult for him to discuss and make decisions about the treatment strategy for esophageal cancer. On day 14, the attending doctor consulted a psychiatrist. Although the patient had reduced mild cognitive and memory retention and decreased ability to lead to a conclusion when supplied with various types of information, his orientation was not as badly impaired. He was irritable when something happened contrary to his expectation, but he calmed down when the situation was explained to his satisfaction. He needed to be spoken to slowly in a loud voice because he had severe hearing loss. He had no appreciable impaired consciousness or delirium. The psychiatrist judged that he retained his decision-making ability. He was given trazodone hydrochloride (25 mg) and risperidone (1 mg) to improve the tendency of day-night reversal. The influence of PPS on his behavior was unclear.

After the dental intervention on day 6 of the NAC, the number of WBCs (especially NEs) gradually decreased, and he had no longer had the  $>37^{\circ}\text{C}$  fever that had lasted for  $>1$  week. On day 15, the lip ulceration had healed and his dry mouth was ameliorated. His oral hygiene was improved, and *Candida* was not detected in the oral cavity. He was subsequently referred to another hospital to receive the second course of chemotherapy on day 17. On day 15, we had prepared a dental referral that showed the ward nurse how to perform oral care.

After the second course of chemotherapy, the patient decided not to undergo surgery when he was re-admitted to Okayama University Hospital. We made dental referrals to an area hospital and his primary care dentist. We informed the patient about the necessity of oral care and about consulting the primary care dentist and attending doctor in an area hospital. We discussed our oral care management using a toothbrush, sponge brush, and moisturizing mouth spray, the roles of ward

nurses, and clinical causes of *Candida* infection with the primary care dentist.

Informed consent for publication of the details of this case was obtained orally from the patient's family.

## Discussion

It is important to prevent the complication of pneumonia and provide perioperative nutrition for patients after esophagectomy. The presence of pathogens in dental plaque is a risk factor for postoperative pneumonia in esophageal cancer patients. Postoperative pneumonia decreased from 32% to 9% and the frequency of postoperative pneumonia requiring tracheostomy decreased from 12% to 0% only by tooth brushing 5 times a day [5]. Soutome *et al.* investigated the effect of perioperative oral care in 539 esophageal cancer patients undergoing surgery, and they concluded that perioperative oral care can reduce the risk of postoperative pneumonia [2].

Oral infection can cause febrile neutropenia (FN) during chemotherapy [6]. In the present case, from day 1 to day 7 of the NAC, the number of WBCs (especially NEs) gradually increased, and the patient suffered from a fever  $>37^{\circ}\text{C}$  for 3 out of the first 5 days. These findings indicated that he had an infection. On day 6 of the NAC, we confirmed the presence of *Candida* as an oral pathogen and recognized the breakdown (*i.e.*, oral mucositis) of the epithelial barrier as a route of pathogen entry. After dental intervention on day 6 of the NAC, the patient's WBC and NE counts gradually decreased, and he no longer had the  $>37^{\circ}\text{C}$  fever that had lasted  $>1$  week. The oral care of the patient likely reduced the source of infection and fever. In addition, the oral care might have reduced the risk of FN and antimicrobial agent use.

Occlusal support is another important factor affecting nutritional support to improve the prognosis of patients after esophagectomy. We have reported the case of an 82-year-old man who underwent esophagectomy and gained body weight after receiving denture treatment; thus, an appropriate prosthesis can contribute to perioperative nutrition support and lead to earlier recovery after surgery [3]. Moreover, dysphagia is a concern in patients with PPS, because their bulbar muscles often have clinical or subclinical signs of dysfunction [7]. Dysphagia suggests a slow, progressive deterioration of bulbar neurons, similar to that in the

muscles of the limbs [7]. Although our patient refused swallowing testing, medical professionals including dentists and dental hygienists should prospectively follow up swallowing function in patients with PPS.

In our patient's case, although he had a chief complaint of aphagia at the first visit, the neurologist confirmed that he did not exhibit bulbar palsy including dysphagia. Aphagia might develop due to obstruction of the esophagus with cancer. Although poliomyelitis has been almost completely eradicated in most industrialized countries including Japan, PPS has emerged as a neuromuscular pathology in many survivors of the acute disease [8]. The most common symptoms are fatigue, pain, and new episodes of weakness thought to be related to a delayed deterioration of motor neuron function [9]. The effectiveness of pharmacological treatment and rehabilitation management in PPS is not yet established [10,11]. Patients with PPS need particular attention; for example, understanding and consideration of the disease in perioperative oral management. In our patient's case, oral care provided by an interprofessional collaboration proved to have a remarkable effect on the quality of life of this individual with progressive muscle weakness associated with PPS.

This oral care approach might be useful for patients with upper limb disability caused by neurological diseases, *e.g.*, cerebrovascular disorders and sequelae of traumatic injuries. Patients with PPS develop both physical symptoms, including progressive muscle weakness, and psychological symptoms, such as chronic stress, anxiety, depression, and compulsive type A behavior [12]. These symptoms not only cause marked distress but also prevent patients from making the necessary lifestyle changes to treat their illness [13]. Psychological symptoms must be decreased so that patients can make necessary lifestyle changes and possibly feel less lonely. Patients need support from their family, friends, or medical personnel to accept lifestyle changes and treat their illness [13].

Our patient had hemiparesis of the upper limbs associated with sequelae of PPS, and he could not perform oral care by himself. He required support from his family, friends, or medical personnel to perform oral care. However, he had been stubborn and irritable and persisted in his idea of being self-sufficient. His character seemed to prevent us from providing preoperative oral care. Initially, he would not let anyone other than his primary care dentist treat him, and he did not give

us informed consent. He had established a relationship of mutual trust with his primary care dentist over a long period of time. He might have refused to consult another dentist other than his primary care dentist because of stubbornness as a characteristic of PPS. Moreover, he had not understood the significance of consulting acute hospital dentists.

The primary care dentist informed the patient about the importance of perioperative dental management, and the patient then agreed to a dental intervention. Cooperation between the primary care dentist and the acute hospital dentist likely led to the successful outcome. It is noteworthy that the patient ultimately refused an esophagectomy and chose to stay home with his family and colleagues because polio survivors have a tendency to value social occupations and participation in family life [13]. In his case, the interprofessional collaboration including his primary care dentist, dentists of Okayama University, dental hygienists, dental technicians, and ward nurses was critical (Fig. 3). The further improvement of the patient's oral health by interprofessional oral care performed as perioperative management and data-sharing with a primary care dentist would be useful for his continued care.

To our knowledge, we have described the first case in which infection control by oral care proved by an interprofessional collaboration successfully improved the oral hygiene of a patient with esophageal cancer associated with PPS. The patient was followed without severe complications during the NAC. Further studies of larger populations are needed to confirm the efficacy of preoperative oral care in patients with cancers associated with PPS, especially those with an upper limb

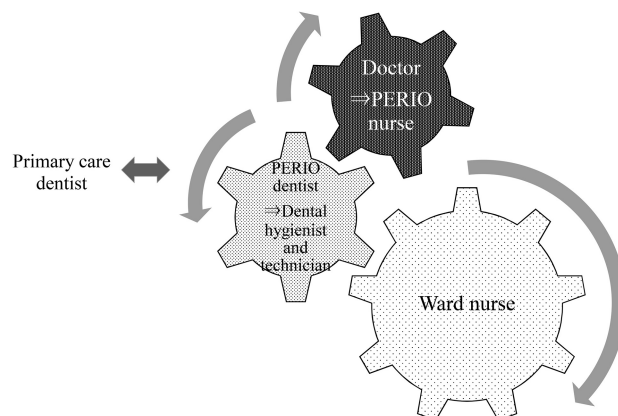


Fig. 3 The importance of interprofessional collaboration.



disability caused by neurological disease or the sequelae of a traumatic injury.

**Acknowledgments.** We are deeply grateful to the members of the Perioperative Management Center, Okayama University Hospital. This work was supported in part by the Japan Society for the Promotion of Science (JSPS) through a Kakenhi Grant-in-Aid for Scientific Research for Young Scientists (B) (no. 25862082) and a Grant-in-Aid for Scientific Research (C) (no. 16K11858) from the JSPS.

## References

1. Soutome S, Yanamoto S, Funahara M, Hasegawa T, Komori T, Oho T and Umeda M: Preventive Effect on Post-Operative Pneumonia of Oral Health Care among Patients Who Undergo Esophageal Resection: A Multi-Center Retrospective Study. *Surg Infect (Larchmt)* (2016) 17: 479–484.
2. Soutome S, Yanamoto S, Funahara M, Hasegawa T, Komori T, Yamada SI, Kurita H, Yamauchi C, Shibuya Y, Kojima Y, Nakahara H, Oho T and Umeda M: Effect of perioperative oral care on prevention of postoperative pneumonia associated with esophageal cancer surgery: A multicenter case-control study with propensity score matching analysis. *Medicine (Baltimore)* (2017) 96: e7436.
3. Yamanaka R, Soga Y, Minakuchi M, Nawachi K, Maruyama T, Kuboki T and Morita M: Occlusion and weight change in a patient after esophagectomy: success derived from restoration of occlusal support. *Int J Prosthodont* (2013) 26: 574–576.
4. Sonis S and Treister: Oral mucositis; in *Oral complications*, Davis AN and Epstein JB, 1st Ed, OXFORD, Oxford (2010) pp 141–149.
5. Akutsu Y, Matsubara H, Shuto K, Shiratori T, Uesato M, Miyazawa Y, Hoshino I, Murakami K, Usui A, Kano M and Miyauchi H: Pre-operative dental brushing can reduce the risk of postoperative pneumonia in esophageal cancer patients. *Surgery* (2010) 147: 497–502.
6. Soga Y, Yamasuji Y, Kudo C, Matsuura-Yoshimoto K, Yamabe K, Sugiura Y, Maeda Y, Ishimaru F, Tanimoto M, Nishimura F and Takashiba S: Febrile neutropenia and periodontitis: lessons from a case periodontal treatment in the intervals between chemotherapy cycles for leukemia reduced febrile neutropenia. *Support Care Cancer* (2009) 17: 581–587.
7. Sonies BC and Dalakas MC: Dysphagia in patients with the post-polio syndrome. *N Engl J Med* (1991) 324: 1162–1167.
8. Blondel B, Duncan G, Couderc T, Delpeyroux F, Pavio N and Colbère-Garapin F: Molecular aspects of poliovirus biology with a special focus on the interactions with nerve cells. *J Neurovirol* (1998) 4: 1–26.
9. Lambert DA, Giannouli E and Schmidt BJ: Postpolio syndrome and anesthesia. *Anesthesiology* (2005) 103: 638–644.
10. Koopman FS, Beelen A, Gilhus NE, de Visser M and Nollet F: Treatment for postpolio syndrome: *Cochrane Database Syst Rev* (2015) 18: CD007818.
11. Creange SJ and Bruno RL: Compliance with treatment for postpolio sequelae: effect of type A behavior, self-concept, and loneliness. *Am J Phys Med Rehabil* (1997) 76: 378–382.
12. Bruno RL and Frick NM: The psychology of polio as prelude to post-polio sequelae: behavior modification and psychotherapy. *Orthopedics* (1991) 14: 1185–1193.
13. Atwal A, Giles A, Spiliotopoulou G, Plastow N and Wilson L: Living with polio and postpolio syndrome in the United Kingdom. *Scand J Caring Sci* (2013) 27: 238–245.