

*Case Report*

## Orthodontic Treatment of a Patient with Bilateral Congenitally Missing Maxillary Canines: The Effects of First Premolar Substitution on the Functional Outcome

Kumi Sumiyoshi, Yoshihito Ishihara\*, Hiroki Komori, Takashi Yamashiro, and Hiroshi Kamioka

*Department of Orthodontics, Graduate School of Medicine, Dentistry and Pharmaceutical Sciences, Okayama University, Okayama 700-8558, Japan*

Permanent canines are thought to play a pivotal role in obtaining an ideal occlusion. Dentists occasionally encounter patients who lack canines and are therefore missing a key to harmonious guidance during functional mandibular excursions. This case report describes the substitution of maxillary first premolars for congenitally missing canines in the context of an orthodontic treatment plan. A boy, age 10 years and 11 months, with a chief complaint of crooked teeth was diagnosed with Class II division 2 malocclusion associated with a high mandibular plane angle and deep overbite. A stable occlusion with a satisfactory facial profile and functional excursions without interference were achieved after a comprehensive two-stage orthodontic treatment process. The resulting occlusion and satisfactory facial profile were maintained for 12 months. These results indicate that substituting the first premolars for the canines is an effective option in treating patients with missing canines while maintaining functional goals.

**Key words:** orthodontics, missing canines, stomatognathic function

**D**ue to their shape and position in the dental arch, the permanent canines are crucial to both functional occlusion and the dentofacial aesthetics [1-3]. Canines also play an important role in providing guidance and achieving the occlusal scheme known as mutually protected occlusion [4-6] due to their larger root surface areas, better crown-root ratio, and greater capacity to tolerate high occlusal forces compared with other teeth [7]. However, dentists sometimes encounter situations in which canines require extraction for reasons related to severe malposition, ankylosis, impaction or congenital defects.

In cases of missing canines, appropriate occlusal rehabilitation demands special consideration due to the complexity of treatment. Orthodontic space closure is a possible treatment option for achieving better periodontal health in such cases [8]. While there are reports of comprehensive orthodontic treatment for congenitally-missing canines [9, 10], no previous studies have described the clinical assessment of stomatognathic function.

The present report describes the successful orthodontic treatment of a young patient with a skeletal Class II division 2 malocclusion associated with congenitally missing maxillary permanent canines. The patient's stomatognathic function, condylar motion and

Received July 6, 2015; accepted September 15, 2015.

\*Corresponding author. Phone: +81-86-235-6692; Fax: +81-86-235-6694  
E-mail: [ishihara@md.okayama-u.ac.jp](mailto:ishihara@md.okayama-u.ac.jp) (Y. Ishihara)

Present address: Department of Oral Medicine, Infection and Immunity, Harvard School of Dental Medicine, Boston, MA 02115, USA

Conflict of Interest Disclosures: No potential conflict of interest relevant to this article was reported.

jaw movement were evaluated to assess the usefulness of substitution for absent canines in terms of maintaining gnathologic principles.

### Case Report

A boy 10 years and 11 months of age visited the outpatient dental clinic of Okayama University Hospital with a chief complaint of crooked teeth (Fig. 1A). An excessive overjet of 5.0 mm with Angle Class II molar relationships on both sides and a deep overbite of 6.0 mm were observed. The upper deciduous canines were peg-shaped, and an anterior crossbite was present in both canines. The absence of the maxillary permanent canines was confirmed on a panoramic radiograph (Fig. 2A).

In comparison with Japanese norms [11], the cephalometric analysis of the patient showed a skeletal

Class II jaw relationship due to the relatively retruded position of the mandible (ANB, 7.5°; SNA, 75.5°; SNB, 68.0°) and a high mandibular plane angle (Mp-SN, 48.0°) (Fig. 3A, Fig. 4A). The maxillary and mandibular incisor angles were within the normal ranges (U1-SN, 88.5°; L1-Mp, 93.0°), although extruded (L1/Mp, 46.5 mm; U1/PP, 32.5 mm). In addition, the patient's lower facial ratio was slightly small (N-Me, 124.4 mm; Me/PP, 64.7 mm), and the upper and lower lips protruded relative to the aesthetic E-line (upper, 5.0 mm; lower, 5.5 mm).

Based on these findings, the patient was diagnosed with skeletal Class II, Angle Class II malocclusion, with a high mandibular plane angle, a deep overbite and congenitally missing maxillary canines. The phase 1 treatment aimed to correct deep overbite, reduce the mandibular anterior crowding and prevent downward and backward rotation of the mandible. The phase 2

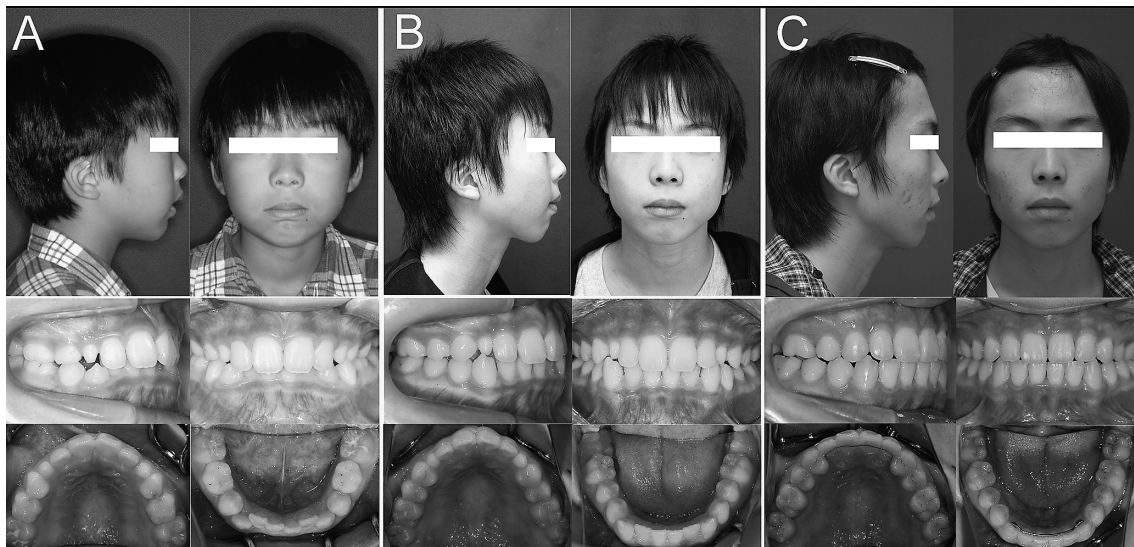


Fig. 1 Facial and intraoral photographs. A, Pretreatment; B, End of the phase 1 treatment; C, Posttreatment.

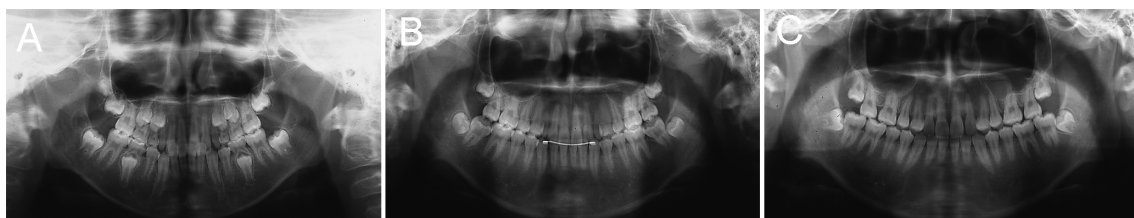

Fig. 2 Panoramic radiograph. A, Pretreatment; B, End of the phase 1 treatment; C, Posttreatment.

treatment aimed to camouflage the antero-posterior skeletal discrepancy, improve the facial aesthetics, correct the dental midline and create a functional and aesthetic occlusion by retracting the maxillary incisors into the spaces created by the extraction of the maxillary deciduous canines.

A bite-plate with posterior occlusal capping and a 2 × 4 appliance were used to improve the patient's deep overbite for 10 months. A lower lingual arch was also employed in order to take advantage of the leeway space and to reduce incisor crowding. The total treatment period for phase 1 treatment was 22 months, and dentofacial growth was observed for 24 months. After the conclusion of phase 1 treatment, the patient continued to exhibit a skeletal Class II and Angle Class II malocclusion with a scissor-bite of both second molars and a cross-bite in the maxillary deciduous and lower canines (Fig. 1B). Cephalometric superimposition showed significant growth of the maxilla and mandible in a slightly forward and mostly downward direction

consistent with the patient's vertical facial pattern of growth (Fig. 3D). The mandibular plane angle was reduced in an upward and forward direction by 5.5° (Fig. 4). A slight intrusion of the anterior teeth was observed compared to the vertical growth of the upper and lower jaws. The phase 2 treatment lasted 44 months. After the removal of all appliances, a palatal fixed retainer combined with a wrap around-type retainer was placed in the upper arch, and a canine-to-canine lingual bonded retainer in the lower arch.

Orthodontic treatment improved the patient's skeletal discrepancy and occlusal relationships. The posttreatment facial photographs showed slight forward movement of the mandibular position and improvements in the upper and lower lip protrusion (Fig. 1C). The extraction spaces created by the deciduous maxillary canines were closed via mesial movement of the upper buccal teeth and palatal inclination of the incisors. The maxillary incisors were

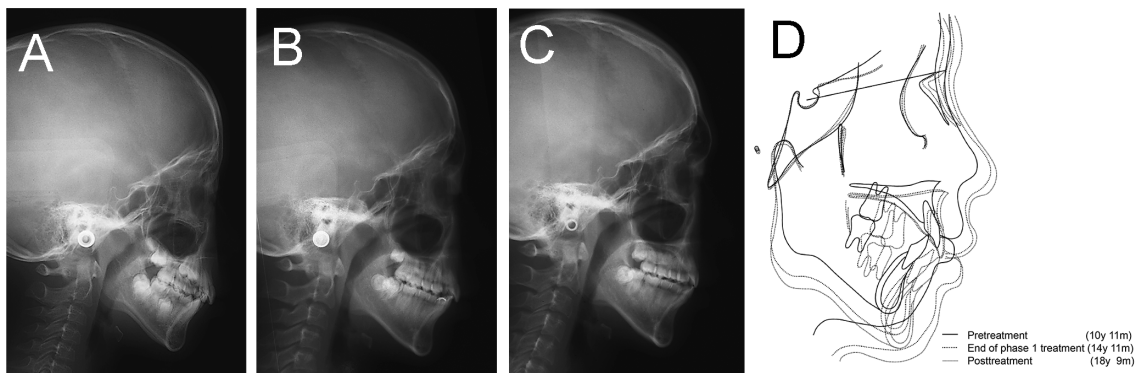


Fig. 3 Cephalometric radiograph. **A**, Pretreatment; **B**, End of the phase 1 treatment; **C**, Posttreatment; **D**, Superimposed cephalometric tracings show changes from pretreatment to posttreatment stages.

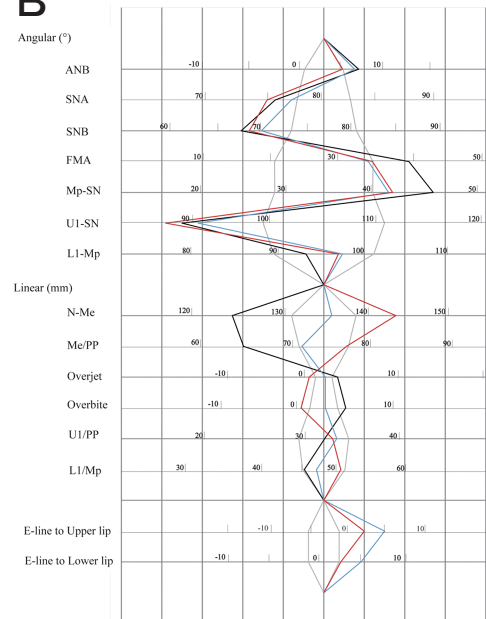
Table 1 Three-dimensional linear measurements of the jaw border movements

Variables	Condylar path length				Lower incisor path length			
	Japanese norms (Adult male)	S.D.	Phase 2 Pretreatment	Phase 2 Posttreatment	Japanese norms (Adult male)	S.D.	Phase 2 Pretreatment	Phase 2 Posttreatment
Maximum jaw opening (mm)	19.2	2.62	R : 9.14/L : 9.30	R : 12.29/L : 11.34	49.84	5.13	33.93	41.2
Maximum jaw protrusion (mm)	9.4	3.44	R : 8.13/L : 5.35	R : 9.53/L : 7.68	10.90	1.46	7.1	8.3
Maximum jaw laterotrusion (mm)	10.0	2.23	R : 7.57/L : 3.65	R : 9.33/L : 8.63	10.76	2.48	R : 3.68/L : 7.31	R : 7.58/L : 8.18

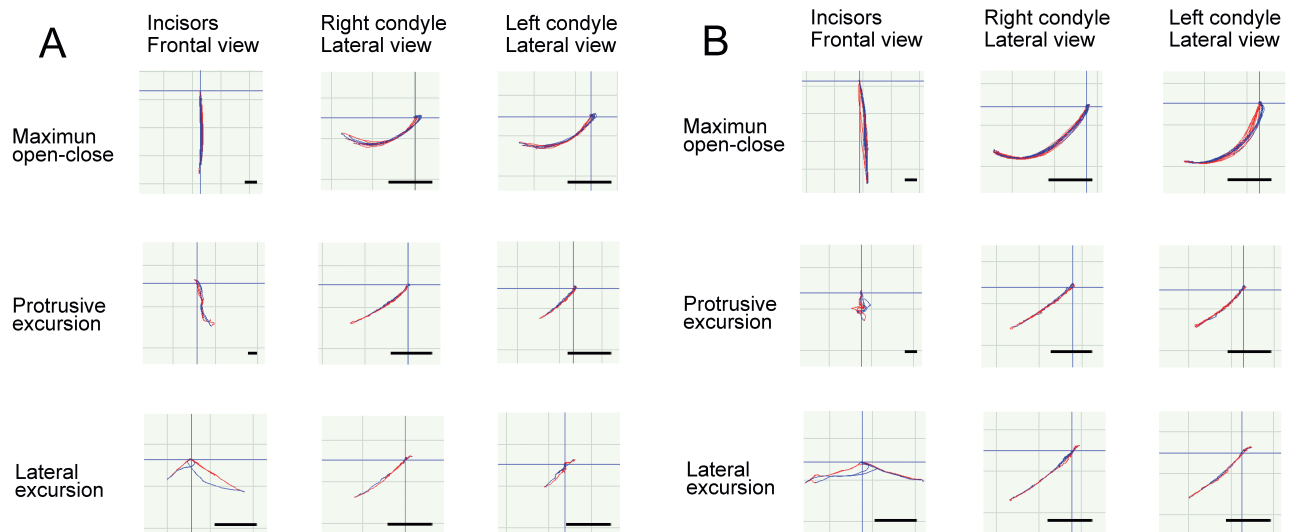
**A**

Variables	Japanese norms (Adult male)	S.D.	Phase 1 Pretreatment	Phase 2 Pretreatment	Phase 2 Posttreatment
<b>Angular (°)</b>					
ANB	3.2	2.38	7.5	7.0	5.5
SNA	81.5	3.29	75.5	77.5	74.5
SNB	78.2	4.02	68.0	70.5	69.0
FMA	28.0	6.08	38.5	33.5	34.0
Mp-SN	34.5	6.05	48.0	42.5	43.0
U1-SN	106.0	7.49	88.5	90.5	86.5
L1-Mp	95.2	6.18	93.0	97.5	97.0
<b>Linear (mm)</b>					
N-Me	135.7	3.98	124.4	136.7	144.6
Me/PP	74.6	3.04	64.7	71.9	77.4
Overjet	3.3	1.01	5.0	3.5	1.5
Overbite	3.3	1.72	6.0	3.5	0.5
U1/PP	32.4	3.08	32.5	34.0	33.5
L1/Mp	48.9	2.61	46.5	48.0	51.0
E-line to Upper lip	-2.5	1.90	5.0	5.0	2.5
E-line to Lower lip	0.9	1.90	5.5	5.5	3.0

**B**



**Fig. 4** Summary of the cephalometric findings. **A**, Cephalometric findings; **B**, Perigon graph. The black line indicates the Phase 1 pretreatment phase, the blue lines indicate the Phase 2 Pretreatment phase, and the red line indicates the Phase 2 Posttreatment phase.



**Fig. 5** Condylar movement and incisal paths recorded using a jaw movement recording system with six degrees of freedom. The red lines indicate the opening phase, and the blue lines indicate the closing phase. **A**, Phase 2 pretreatment; **B**, Posttreatment. Bar: 5mm.

palatally inclined by  $4.0^\circ$  and intruded by 0.5 mm (Fig. 4).

In an evaluation of the patient's movement using a jaw movement recording system with 6 degrees of freedom (Gnathohexagraph system Ver. 1.31; Ono Sokki Ltd., Kanagawa, Japan) [12–14], the condylar head movement during protrusive and lateral excursion was stable with a good locus (Fig. 5, Table 1). Posttreatment functional assessments including occlusal force, occlusal contact area, and electromyographic recording showed no marked changes (data not shown). A posttreatment panoramic radiograph confirmed the good root parallelism without obvious root resorption (Fig. 2C). A posttreatment cephalometric analysis showed a reduction in the ANB angle of  $1.5^\circ$  resulting from relatively greater forward and downward growth of the mandible compared with that of the maxilla. In addition, the occlusal plane angle was reduced by  $2.5^\circ$ , while the FMA angle was maintained (Fig. 3C, Fig. 4). Both the occlusion and facial aesthetics were maintained within acceptable levels over the 12-month postretention period.

## Discussion

Treatment planning in patients with bilateral congenitally missing maxillary canines is challenging, as canines play important roles in aesthetics and a functioning occlusion. Previous studies have debated the criteria for functional occlusion; however, because there is no single predominant type of functional occlusion, there is no evidence-based body of literature to support these different approaches [15, 16]. In order to obtain successful dentofacial aesthetics and a functional outcome, several issues must first be addressed, including the type of malocclusion, the tooth size and shape, the surrounding periodontal tissue and the patient's age, medical history and motivation for seeking treatment [17, 18]. The major advantage of orthodontic space closure and first premolar substitution for missing canines is the stability of the final result. In addition, Zachrisson reported that orthodontic space closure produced better results than prosthetic replacement, and promoted periodontal health without influencing the temporomandibular joint function [19]. Orthodontic space closure was the most preferable option in the present case, considering the patient's skeletal Class II malocclusion and

increased overjet and overbite.

The applicability of orthodontic space closure for missing upper canines is comparable to the applicability of space closure for the missing upper lateral incisors. To optimize functionality in the present case, individualized extrusion, mesial rotation, and crown lingual torque of the upper first premolars were accentuated to eliminate occlusal interference and imitate canine prominence [14, 20]. Lateral and protrusive excursion without interference is an important factor in achieving a functionally stable occlusion. The present patient's condylar movement and incisal pathway of protrusive and lateral excursion were improved after orthodontic treatment (Fig. 5). Gnathological results comparing the three-dimensional (anterior, lateral, and inferior) linear measurements of the jaw border movements confirmed that the movement ranges of the lower incisor and condylar paths showed an increased movement at the maximum jaw opening after treatment. Additionally, the maximum jaw laterotrusion showed a more symmetrical appearance (Table 1). These changes are consistent with previous results that compared the chewing patterns present in deep overbite malocclusions before and after orthodontic treatment [21]. Additionally, the observed functional improvements could be explained by the correction of the canine and second molar scissor-bites.

To the best of our knowledge, this is the first report of a quantitative evaluation of a functional assessment obtained after the treatment of a patient by the substitution of the missing upper canines. The short-term measurements for functional issues were acceptable; however, the long-term measurements require further investigation. With these limitations in mind, we conclude that additional studies are needed, as the long-term functionality of a premolar in place of a canine has yet to be determined. The long-term periodontal health also requires further consideration due to the stress placed on the substituted maxillary first premolars [8].

## Conclusion

In the present case report, a high mandibular plane angle skeletal Class II circumpubertal patient with a Class II division 2 malocclusion with congenitally missing maxillary canines was treated with orthodon-

tic space closure. The findings show that substitution of the first premolars for the canines is effective in attaining a functional occlusion.

**Acknowledgments.** We thank Joshua Chou and Kayo Nagasaka for their insightful comments and support during the writing of this manuscript.

## References

1. Thornton LJ: Anterior guidance: group function/canine guidance. A literature review. *J Prosthet Dent* (1990) 64: 479-482.
2. Reynolds JM: The organisation of occlusion for natural teeth. *J Prosthet Dent* (1971) 26: 56-67.
3. Al-Nimri KS, Bataineh AB and Abo-Farha S: Functional occlusal patterns and their relationship to static occlusion. *Angle Orthod* (2010) 80: 65-71.
4. Kahn AE: The importance of canine and anterior tooth positions in occlusion. *J Prosthet Dent* (1977) 37: 397-410.
5. D'Amico A: Functional occlusion of the natural teeth of man. *J Prosthet Dent* (1961) 11: 899-915.
6. Beyron H: Occlusal relations and mastication in Australian aborigines. *Acta Odontol Scand* (1964) 22: 597-678.
7. Clark JR and Evans RD: Functional occlusion: I. A review. *J Orthod* (2001) 28: 76-81.
8. Nordquist GG and McNeill RW: Orthodontic vs. restorative treatment of the congenitally absent lateral incisor—long term periodontal and occlusal evaluation. *J Periodontol* (1975) 46: 139-143.
9. Leong P and Calache H: Bilateral congenitally missing maxillary canines. A case report. *Aust Dent J* (1999) 44: 279-282.
10. Mirabella D, Giunta G and Lombardo L: Substitution of impacted canines by maxillary first premolars: a valid alternative to traditional orthodontic treatment. *Am J Orthod Dentofacial Orthop* (2013) 143: 125-133.
11. Wada K, Matsushita K, Shimazaki S, Miwa Y, Hasuike Y and Susami R: An evaluation of a new case analysis of a lateral cephalometric roentgenogram. *J Kanazawa Med Univ* (1981) 6: 60-70 (in Japanese).
12. Ishihara Y, Kuroda S, Kawanabe N, Takano-Yamamoto T and Yamashiro T: Intraoral vertical ramus osteotomy improved the stomatognathic function in an elderly patient with mandibular protrusion: a case report. *Acta Med Okayama* (2010) 64: 345-349.
13. Ishihara Y, Kuroda S, Nishiyama A, Sasaki A, Takano-Yamamoto T and Yamashiro T: Functional improvements after orthodontic-surgical reconstruction in a patient with multiple maxillofacial fractures. *Am J Orthod Dentofacial Orthop* (2012) 142: 534-545.
14. Ishihara Y, Kuroda S, Sumiyoshi K, Takano-Yamamoto T and Yamashiro T: Extraction of the lateral incisors to treat maxillary protrusion: Quantitative evaluation of the stomatognathic functions. *Angle Orthod* (2013) 83: 341-354.
15. Rinchuse DJ, Kandasamy S and Sciote J: A contemporary and evidence-based view of canine protected occlusion. *Am J Orthod Dentofacial Orthop* (2007) 132: 90-102.
16. Robertsson S and Mohlin B: The congenitally missing upper lateral incisor. A retrospective study of orthodontic space closure versus restorative treatment. *Eur J Orthod* (2000) 22: 697-710.
17. Al-Anesi SA: Orthodontic treatment for a patient with hypodontia involving the maxillary lateral incisors. *Am J Orthod Dentofacial Orthop* (2011) 139: 690-697.
18. Brough E, Donaldson AN and Naini FB: Canine substitution for missing maxillary lateral incisors: the influence of canine morphology, size, and shade on perceptions of smile attractiveness. *Am J Orthod Dentofacial Orthop* (2010) 138: 705-707.
19. Sachrisson BU, Rosa M and Toreskog S: Congenitally missing maxillary lateral incisors: canine substitution. *Am J Orthod Dentofacial Orthop* (2011) 139: 434-445.
20. Kinser GA and Kokich VO Jr: Managing congenitally missing lateral incisors. Part III: single-tooth implants. *J Esthet Restor Dent* (2005) 17: 202-210.
21. Alexander TA, Gibbs CH and Thompson WJ: Investigation of chewing patterns in deep-bite malocclusions before and after orthodontic treatment. *Am J Orthod* (1984) 85: 21-27.