

Preoperative Evaluation of the Right Upper Lobe Pulmonary Artery by 3D-CT Pulmonary Angiography vs. Thin-Section Multiplanar Reconstruction Images Obtained by Contrast-Enhanced Multidetector-Row CT

Makiko Murota^{a*}, Yuka Yamamoto^a, Katashi Satoh^c, Mariko Ishimura^a,
Masashi Gotoh^b, and Yoshihiro Nishiyama^a

Department of ^aRadiology and ^bGeneral Thoracic Surgery, Faculty of Medicine, Kagawa University, Miki, Kagawa 761-0793, Japan, and
^cDepartment of Nursing, Kagawa Prefectural University of Health Sciences, Takamatu 761-0123, Japan

We compared the effectiveness of 3-dimensional computed tomography pulmonary angiography (3D-CTPA) and thin-section multiplanar reconstruction (MPR) images obtained using contrast-enhanced multidetector row CT (MDCT), in the evaluation of pulmonary artery (PA) branches of the right upper lobe. We studied 127 patients suspected of having lung cancer of the right upper lobe who underwent contrast-enhanced MDCT scans and a right upper lobectomy. We compared the intraoperative findings of the PA branches of the right upper lobe obtained with 3D-CTPA and thin-section MPR images. In 125 (97.7%) patients, one or more PA branches arose from arteries other than the superior trunk. Among 10 (7.9%) patients, a PA branch arose from the middle lobe in one patient and from the superior segment of the lower lobe in the other 9 patients. According to the intraoperative findings, 97.2% and 99.7% of the PA branches were identified by 3D-CTPA and thin-section MPR images, respectively ($p < 0.03$). The single branch missed by both imaging modalities was 1.0 mm in dia. The 8 branches missed only by 3D-CTPA were < 1.4 mm in dia. Both the 3D-CTPA and thin-section MPR images provided precise preoperative information regarding PA branches of the right upper lobe. However, the thin-section MPR images appeared to contribute more to the evaluation of smaller PA branches.

Key words: pulmonary artery, computer-assisted three-dimensional imaging, video-assisted thoracic surgery, anatomy, lung cancer

During pulmonary resection, surgeons occasionally encounter unexpected bleeding from the pulmonary artery (PA). The identification and appropriate treatment of branches of the PA is thus considered one of the key issues for successful surgical resections of the lung. Anatomic variations in the PA

make lung resection more difficult, especially when the separation of the interlobular fissure is incomplete. The anatomy of the hilar structures of the right upper lobe is more complex than that of any other lobe, and arterial anomalies are more common [1]. The preoperative identification of the PA branches in patients would greatly contribute to the safety of lung resec-

tions and the surgeon's ease in performing these surgeries.

Recent developments in multidetector-row computed tomography (MDCT) and MDCT workstations allow the retrieval of thin-section multiplanar reconstruction (MPR) images and three-dimensional (3D) reconstruction images for evaluations of the PA. 3D-CT angiography can be conducted easily and rapidly and provides very useful visual information in various diseases [2]. Several research groups have reported that 3D-CT pulmonary angiography (3D-CTPA) using MDCT may increase the safety of surgical procedures including video-assisted thoracic surgery (VATS) lobectomy and limited resection [3-7]. To the best of our knowledge however, no direct comparison has been made of the imaging of individual PA branches by 3D-CTPA with the images provided by thin-section MPR. The purpose of the present study was to retrospectively compare 3D-CTPA and thin-section MPR images obtained using contrast-enhanced MDCT in the evaluation of PA branches of the right upper lobe before lobectomy.

Patients and Methods

Patients. The ethical committee of Kagawa University approved this retrospective study and waived the requirement to obtain the consent of individual patients (no. 26-067). The cases of 134 consecutive patients suspected of having lung cancer of the right upper lobe who underwent contrast-enhanced MDCT scans and a right upper lobectomy between June 2009 and September 2014 at only Kagawa University Hospital were retrospectively reviewed. Of these 134 patients, 7 were excluded from this study because of technical problems. The final study population was 127 patients (84 men, 43 women; mean age 66.8 years; age range 34-90 years). A VATS lobectomy was performed in 83 patients and an open lobectomy was performed in the other 44 patients.

Contrast-Enhanced MDCT. A 64-slice MDCT scanner (Aquilion 64, Toshiba Medical Systems, Tokyo, Japan) and a 256-slice MDCT scanner (Brilliance iCT, Philips Healthcare, Cleveland, OH, USA) were used. The technical parameters used for the 64-slice MDCT were as follows: a detector row configuration of 0.5 mm, pitch 53, reconstruction increment 0.4 mm, and section thickness 0.5 mm. The

corresponding values for the 256-slice MDCT were 0.625 mm, 53, 0.5 mm and 0.67 mm. These scanning parameters were largely comparable. An X-ray tube (120 kV, 300 mA) were used in all examinations. The examinations were performed with the patient in the supine position during a single breath-hold at end-inspiration.

A dual-head power injector (Dual Shot GX, Nemoto Kyorindo, Tokyo, Japan) was used for all patients for the bolus administration of the contrast material iohexol (Omnipaque 350, Daiichi-Sankyo, Tokyo, Japan) or iopamidol (Iopamiron 300, Bayer Yakuhin, Osaka, Japan) via a cubital vein. In the patients who weighed ≥ 55 kg, 100 mL of the contrast medium iohexol was injected at a rate of 3.3 mL/sec, and the scanning was initiated 18 sec after the injection of contrast medium was started. In the patients who weighed $44 \text{ kg} \leq \text{bodyweight} < 55$ kg, 85 mL of the contrast medium iohexol was injected at a rate of 3.3 mL/sec, and the scanning was initiated 15 sec after the injection of the contrast medium was started. In the patients who weighed < 44 kg, 85 mL of the contrast medium iopamidol was injected at the rate of 3.3 mL/sec, and the scanning was initiated 15 sec after the injection of contrast medium was started. The volume data obtained from the arterial phase were transferred to a workstation (zio STATION, ziosoft, Tokyo, Japan), where the data were converted to a 3D-CT angiography format using the volume-rendering technique.

Image analysis. For the thin-section MPR images, thin-section transverse images and MPR images on coronal and sagittal planes (1-mm slice intervals) were reviewed at a width of 1600 HU and level -200 HU window settings with paging on a viewer (EV Insite, PSP Corp., Tokyo, Japan). The 3D-CTPA images were interpreted by rotating them on the same viewer. The window, level, and opacity of the volumes were subjectively selected to optimize the visualization of the PA.

The right PA first gives off the superior trunk, which supplies the majority of the upper lobe [8, 9]. The arteries of the apical segment almost always arise from the superior trunk [1, 8]. The arteries of posterior and anterior segments arise from the superior trunk, and/or the inferior trunk, and/or the ascending artery [1, 8, 10]. Rarely, the arteries of posterior and anterior segments arise from the arteries of

the superior segment of the lower lobe or middle lobe [1, 8, 10].

In the present study, the number and the origin of the PA branches in the right upper lobe were identified precisely using 3D-CTPA and thin-section MPR images on the same viewer. These images were read with an interval of several days between interpretations. Consensus interpretation of the images was performed by 2 board-certified thoracic radiologists (M.M. and M.I.) who read the images together. We compared the intraoperative findings of the PA branches of the right upper lobe with the preoperatively obtained 3D-CTPA and thin-section MPR images in each patient's case.

For the statistical comparison of the 3D-CTPA and thin-section MPR images, we used Fisher's exact test. P -values < 0.05 were considered to indicate significant differences.

Results

Optimal visualization of the PA branches of the right upper lobe was achieved in all 127 patients. Table 1 shows the branching patterns of the PA of the right upper lobe according to the intraoperative findings. The right PA first gave off the superior trunk in all 127 patients. In all except 2 (97.7%) patients, one or more arteries arose from arteries other than the superior trunk. In 10 (7.9%) patients, the PA branch arose from another lobe (from the middle lobe in one case and from the superior segment of the lower lobe in 9 cases). Of these 9 cases in which the PA branch

arose from the superior segment of the lower lobe, the interlobular fissure was incomplete in one case, and an open lobectomy instead of a VATS lobectomy was thus performed in this case.

According to the intraoperative findings, a total of 325 PA branches were examined. A total of 97.2% (316 of 325) and 99.7% (324 of 325) of these PA branches were precisely identified on preoperative 3D-CTPA and thin-section MPR images, respectively (Table 2). The thin-section MPR's ability to detect PA branches was significantly higher than that of 3D-CTPA images ($p < 0.03$). One branch missed by both the 3D-CTPA and thin-section MPR images was an ascending artery, and it was 1.0mm in dia. Eight branches missed only by 3D-CTPA images were an ascending artery in 7 cases (Fig. 1), and the superior segment of the lower lobe in one case. These 8 missed branches were < 1.4 mm in dia.

Discussion

We directly compared 3D-CTPA and thin-section MPR images using contrast-enhanced MDCT for the evaluation of the PA branching pattern of the right upper lobe before lobectomy. Our findings indicate that the thin-section MPR images provided a better evaluation of smaller PA branches.

Developments in thoracoscopic devices have enabled surgeons to perform anatomic resections through small wounds, such as VATS lobectomy and segmentectomy [11]. However, vascular injury within such minimally invasive surgery can occasionally make

Table 1 The branching patterns of the pulmonary artery (PA) of the right upper lobe according to the intraoperative findings

Branching patterns	Number of patients	
	Total n = 127	
Superior Trunk (1)		2
Superior Trunk (1) + Ascending Artery (1)		55
Superior Trunk (1) + Ascending Artery (2)		27
Superior Trunk (1) + Ascending Artery (1) + Middle Lobe (1)		1
Superior Trunk (1) + Ascending Artery (1) + Superior Segment of Lower Lobe (1)		4
Superior Trunk (1) + Inferior Trunk (1)		3
Superior Trunk (1) + Inferior Trunk (1) + Ascending Artery (1)		25
Superior Trunk (1) + Inferior Trunk (1) + Ascending Artery (2)		5
Superior Trunk (1) + Inferior Trunk (1) + Ascending Artery (1) + Superior Segment of Lower Lobe (1)		2
Superior Trunk (1) + Inferior Trunk (1) + Superior Segment of Lower Lobe (1)		2
Superior Trunk (1) + Superior Segment of Lower Lobe (1)		1

Figures in parentheses are number of branches.

Table 2 Comparison of 3D-CTPA and thin-section MPR images and intraoperative findings of PA branches of the right upper lobe

Origin	Total number of PA branches identified			P Value	
	3D-CTPA images (%)*	Thin-section MPR images (%)*	Intraoperative findings		
Upper lobe	Superior trunk	127 (100)	127 (100)	127	1.0000
	Inferior trunk	37 (100)	37 (100)	37	1.0000
	Ascending artery	143 (94.7)	150 (99.3)	151	0.0363
Middle lobe	1 (100)	1 (100)	1	1.0000	
Superior segment of lower lobe	8 (88.9)	9 (100)	9	1.0000	
Total	316 (97.2)	324 (99.7)	325	0.0205	

*Calculated as a percentage of intraoperative findings in the respective origin category

3D-CTPA, three-dimensional computed tomography pulmonary angiography; MPR, multiplanar reconstruction; PA, pulmonary artery.

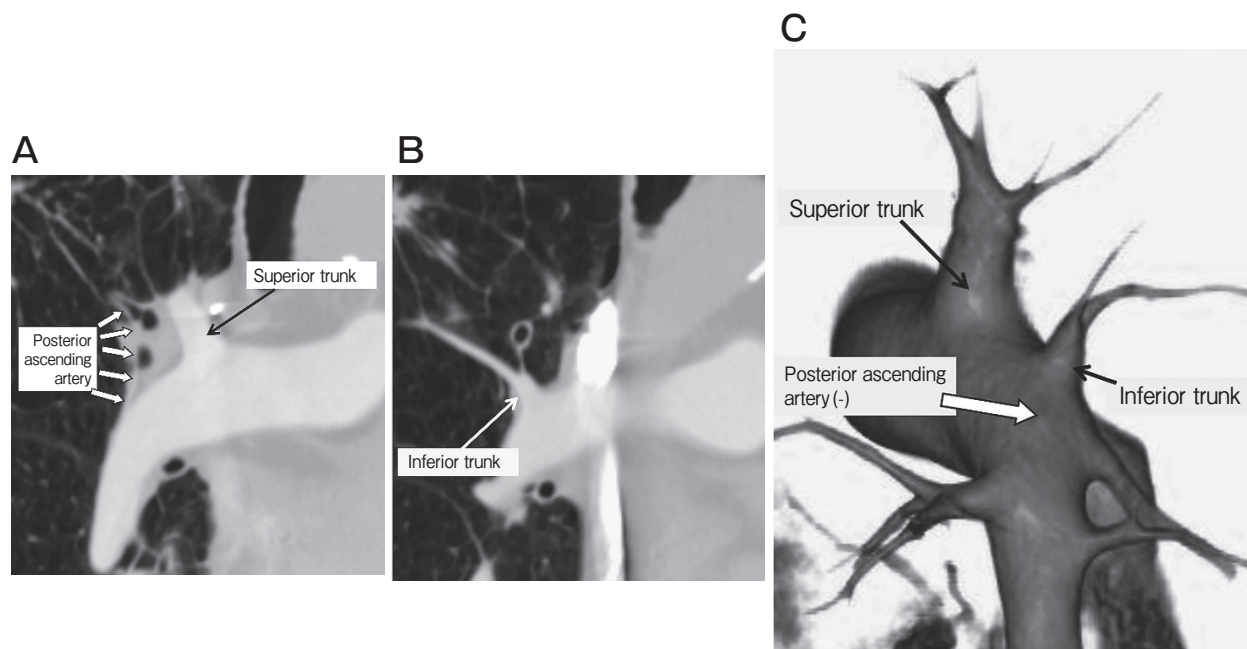


Fig. 1 Coronal multiplanar reconstruction (MPR) and three-dimensional computed tomography pulmonary angiography (3D-CTPA) images of the right pulmonary artery. In these example MPR images (**A**, **B**), the superior trunk, inferior trunk, and ascending artery arising directly from the main pulmonary artery are detected. In the example 3D-CTPA image (**C**), the superior trunk and inferior trunk from the main pulmonary artery are identified but the ascending artery is not detected.

hemostasis difficult and oblige the surgeon to revert to open thoracotomy. In particular, unexpected massive bleeding from an unknown origin could rapidly lead to a critical situation. A VATS requires a more detailed understanding of local anatomy than does conventional open surgery [5]. Since there is considerable complexity and anatomic variation in the PA branching pattern [1], the preoperative identification of the PA branching pattern would make pulmonary resection easier and safer, especially when there is severe interlobar adhesion or an incomplete fissure between

the lobes. Contrast-enhanced MDCT may be useful for the assessment of the PA because it uses 3 types of images: thin-sectional transverse, MPR, and 3D-CTPA [12].

Three-dimensional-CTPA imaging has been a useful investigative tool because it can offer a clear picture that is easy to understand visually and can be used to assess individual vascular variations [3–7]. Coche *et al.* reported that the identification of 96% of the subsegmental arteries could be attained with 3D-CTPA [13]. However, they did not analyze the branching

pattern of the supply artery [13]. Watanabe *et al.* studied 14 patients undergoing anatomic pulmonary resections, and 98% of their PA branches were successfully identified on 3D-CTPA [3]. Two missed branches in their study were less than 1.5mm in dia. [3]. Fukuhara and colleagues also evaluated the branching pattern of the PA using 3D-CTPA in 49 patients undergoing a VATS lobectomy [5]. Their results showed that 95.2% of the PA branches were identified by 3D-CTPA, and 7 undetected branches were less than 2mm in dia. [5]. Akiba *et al.* evaluated PA branches using 3D-CT in 27 patients undergoing a lobectomy or segmentectomy; 95% of the arteries were confirmed by 3D-CT, and the smallest PA dia. detected was 1.2mm [7].

The above-mentioned studies evaluated PA branches of the various lobes together in both lungs [3, 5, 7]. In the present study, we evaluated only PA branches of the right upper lobe—which are more complex than those of any other lobe—in a relatively large patient population. In agreement with the data of the previous studies [3, 5, 7], 97.2% of PA the branches of the right upper lobe were identified by 3D-CTPA in our study. Although 3D-CTPA provided precise preoperative information regarding PA branches, nine vessels < 1.4mm in dia. were missed.

The upper lobe carries “various, complicated patterns of arterial supply” in contrast to the relatively regular patterns of bronchial ramification [1]. Yamashita analyzed the bronchovascular anatomy of 170 specimens and reported that one or more arteries arose from arteries other than the superior trunk in 94.1% [8]. In the present study, one or more arteries also arose from arteries other than the superior trunk in 97.7% of the 127 cases. Moreover, in 7.9% of the cases, PA branches arose from another lobe. If there are arteries other than the superior trunk that supply blood to the upper lobe, they must all be dissected. We found that these vessels were more easily visualized by thin-section MPR imaging compared to 3D-CTPA because they were identified using the lung window display on the thin-section MPR images by the identification of bronchi, fissures, and other anatomic landmarks.

In the present study, 99.7% of PA branches were identified on thin-section MPR images, and eight vessels that were missed by 3D-CTPA could be detected on thin-section MPR images. In a previous study, the

subsegmental (fifth-order) PA could be visualized using MPR images [14]. Ghaye *et al.* investigated the best possible visualization of small arteries using MDCT, and 94% of the subsegmental PA and 74% of the subsubsegmental PA were depicted with images reconstructed at 1.25-mm collimation [15].

Here, the thin-section MPR images provided detailed information about vessels—especially those small in size—in each slice. However, it is usually difficult to grasp the dimensions of these branches in the same direction. On the other hand, surgeons can obtain favorable 3D images that can be rotated 360° in any direction as desired, allowing a thoracoscopic view and the operator’s view [3, 5]. Surgeons must therefore obtain preoperative information about the PA branching pattern using not only 3D-CTPA but also thin-section MPR images.

Ohno *et al.* recently compared non-contrast-enhanced MR angiography and contrast-enhanced MDCT for assessing the pulmonary vasculature in patients with lung cancer before surgical treatment, and their results showed that these 2 imaging techniques could be considered equivalent [16]. Watanabe *et al.* reported that the quality of images obtained 3D-CTPA without contrast medium was almost the same as that with contrast medium [3]. Non-contrast-enhanced MR angiography and 3D-CTPA without contrast medium can be a safe investigative procedure even when the patient has renal failure or asthma or is allergic to contrast medium. Further studies including those of non-contrast-enhanced imaging modalities and their technical improvements are needed to assess the clinical usefulness of this approach in the evaluation of PA branching patterns before pulmonary resection.

In conclusion, in the present study, both 3D-CTPA and thin-section MPR images provided precise preoperative information regarding the PA branching pattern of the right upper lobe. However, the thin-section MPR images appeared to provide better evaluations of smaller PA branches. It is necessary to assess the PA branches of the right upper lobe while taking into consideration branches supplied from other lobes.

References

1. Koshino T, Murakami G, Sato TJ, Tsugane MH, Fujisawa Y, Mawatari T and Abe T: Configurations of the segmental and subsegmental bronchi and arteries in the right upper lobe of the human

- lung with special reference to their concomitant relations and double subsegmental arterial supply. *Anat Sci Int* (2002) 77: 64–73.
2. Remy-Jardin M and Remy J: Spiral CT angiography of the pulmonary circulation. *Radiology* (1999) 212: 615–636.
 3. Watanabe S, Arai K, Watanabe T, Koda W and Urayama H: Use of three-dimensional computed tomographic angiography of pulmonary vessels for lung resections. *Ann Thorac Surg* (2003) 75: 388–392.
 4. Nakamoto K, Omori K, Nezu K and Lung Cancer Project Group of West-Seto Inland Sea, Japan: Superselective segmentectomy for deep and small pulmonary nodules under the guidance of three-dimensional reconstructed computed tomographic angiography. *Ann Thorac Surg* (2010) 89: 877–883.
 5. Fukuhara K, Akashi A, Nakane S and Tomita E: Preoperative assessment of the pulmonary artery by three-dimensional computed tomography before video-assisted thoracic surgery lobectomy. *Eur J Cardiothorac Surg* (2008) 34: 875–877.
 6. Duong PA, Ferson PF, Fuhrman CR, McCurry KR and Lacomis JM: 3D-multidetector CT angiography in the evaluation of potential donors for living donor lung transplantation. *J Thorac Imaging* (2005) 20: 17–23.
 7. Akiba T, Marushima H, Harada J, Kobayashi S and Morikawa T: Importance of preoperative imaging with 64-row three-dimensional multidetector computed tomography for safer video-assisted thoracic surgery in lung cancer. *Surg Today* (2009) 39: 844–847.
 8. Yamashita H: Variations in the pulmonary segments and the bronchovascular trees; in *Roentgenologic Anatomy of the Lung*. Igaku-Shoin, Tokyo (1978) pp72–75.
 9. Otsuji H, Hatakeyama M, Kitamura I, Yoshimura H, Iwasaki S, Ohishi H, Uchida H, Kitamura S and Narita N: Right upper lobe versus right middle lobe: differentiation with thin-section, high-resolution CT. *Radiology* (1989) 172: 653–656.
 10. Stanley C and Kirby T: Technical aspects of lobectomy; in *General Thoracic Surgery*, Shields T, LoCicero J3 and Ponn R, eds. 5th Ed, Lippincott Williams & Wilkins, Philadelphia (2000) pp434–439.
 11. Kaseda S, Aoki T and Hangai N: Video-assisted thoracic surgery (VATS) lobectomy: the Japanese experience. *Semin Thorac Cardiovasc Surg* (1998) 10: 300–304.
 12. Remy J, Remy-Jardin M, Artaud D and Fribourg M: Multiplanar and three-dimensional reconstruction techniques in CT: impact on chest diseases. *Eur Radiol* (1998) 8: 335–351.
 13. Coche E, Pawlak S, Dechambre S and Maldague B: Peripheral pulmonary arteries: identification at multi-slice spiral CT with 3D reconstruction. *Eur Radiol* (2003) 13: 815–822.
 14. Murota M, Satoh K, Yamamoto Y, Kobayashi T and Nishiyama Y: Evaluation of subsegmental pulmonary arteries of the posterior and anterior segments of the right upper lobe using multidetector row computed tomography with multiplanar reconstruction images. *Jpn J Radiol* (2009) 27: 86–90.
 15. Ghaye B, Szapiro D, Mastora I, Delannoy V, Duhamel A, Remy J and Remy-Jardin M: Peripheral pulmonary arteries: how far in the lung does multi-detector row spiral CT allow analysis? *Radiology* (2001) 219: 629–636.
 16. Ohno Y, Nishio M, Koyama H, Yoshikawa T, Matsumoto S, Seki S and Sugimura K: Comparison of assessment of preoperative pulmonary vasculature in patients with non-small cell lung cancer by non-contrast- and 4D contrast-enhanced 3-T MR angiography and contrast-enhanced 64-MDCT. *AJR Am J Roentgenol* (2014) 202: 493–506.