

Original Paper

Management of peritoneal effusion by sealing with a self-assembling nanofiber polypeptide following pelvic surgery

Yoshitaka Kondo¹, Takeshi Nagasaka¹, Satoru Kobayashi², Naoya Kobayashi¹,
and Toshiyoshi Fujiwara¹

¹Department of Gastroenterological Surgery, Okayama University Graduate School of Medicine, Dentistry and Pharmaceutical Sciences, Okayama 700-8558, Japan

²3-Dmatrix, Ltd., Tokyo 102-008, Japan.

Corresponding author: Toshiyoshi Fujiwara, MD, PhD, Department of Gastroenterological Surgery, Okayama University Graduate School of Medicine, Dentistry and Pharmaceutical Sciences, 2-5-1 Shikata-cho, Kita-ku, Okayama 700-8558, Japan. E-mail: toshi_f@md.okayama-u.ac.jp

Key words: Peritoneal effusion; Nanofiber polypeptide; Lymphorrhea; Pelvic surgery.

Short title: Effusion management by nanofiber polypeptide.

ABSTRACT

Background/Aims: PuraMatrix is a synthetic material consisting of 16-amino acid peptides that self-assemble into nanofibers, previously used as a scaffold for functional cell cultures. We conducted a clinical study to determine the safety and sealing properties of PuraMatrix in post-operative lymphorrhea following pelvic surgery in humans. **Methodology:** A total of 20 patients who underwent rectal cancer resection were analyzed. The study group (n = 10) consisted of patients who received PuraMatrix, matched with a control group (n = 10) of patients operated on conventionally. **Results:** During the 2 to 3 month follow-up period, there were no abnormal findings or adverse events in any the patients who received PuraMatrix. We found that the patients who received PuraMatrix had significantly reduced post-operative drainage volumes compared with the patients in the control group. **Conclusions:** PuraMatrix is a safe and effective bio-compatible sealing material for the management of post-operative peritoneal effusion following pelvic surgery.

INTRODUCTION

Post-operative lymphorrhea has been observed following lymphadenectomy during pelvic oncological surgery (1, 2). Rectal dissection results in exposure of the broad raw surface of the presacral space, and lymphatic and/or vascular channels transected during surgery can cause fluid to leak into the abdominal cavity (3). It is very difficult to effectively prevent lymphorrhea because a good field of view of the pelvic viscera is hard to obtain from an anatomical perspective. Peritoneal fluid accumulation is usually asymptomatic and eventually reabsorbed (4); however, it may cause complications including secondary infection, sepsis, chylous ascites, or thrombosis due to compression of blood vessels (5). In particular, ascites increases when associated with chronic liver disease, and frequently induces severe and life-threatening complications due to intestinal bacterial translocation (6). Although, previously, surgeons inserted a drain as a matter of routine, prophylactic drainage of the pelvis has been abandoned because of the risk of intra-abdominal infection as a route for ascending infection (7, 8). Therefore, there is currently need for peritoneal fluid accumulation to be reduced as much as possible following pelvic surgery.

PuraMatrix is a synthetic material consisting of 16-amino acid peptide fragments that self-assemble into a nano-fiber structure (9) (Fig. 1). It has been used as a synthetic extracellular matrix for cell culture. PuraMatrix also has rapid and potent hemostatic effects when applied during experimental surgery in rodents (10). When PuraMatrix comes into contact with blood and tissue fluids, the pH and salt concentrations cause nanofiber formation and gelation that blocks the blood vessels in the hemorrhagic area and generates a hemostatic effect without secondary effects upon the surrounding tissues. The safety and sealing efficacy of PuraMatrix may be superior to those of other topical hemostatic agents that are either

collagenous hemostatic materials produced from bovine collagen or fibrin glue produced from blood preparations, and a source of concern regarding possible viral infections. Moreover, topical hemostatic agents can cause secondary effects on the surrounding tissues during hemostasis such as compression, ablation, vascular contraction, coagulation, or adhesion due to cross-link formation (11, 12).

We hypothesize that post-operative peritoneal fluid accumulation can be reduced when PuraMatrix is used to stop bleeding during pelvic surgery. The aims of this study were to determine the safety and sealing effects of PuraMatrix as a bio-compatible sealing material for peritoneal effusion in patients undergoing rectal cancer surgery.

METHODOLOGY

Patients

The patients were individuals that underwent rectal surgery at Okayama University Hospital, Okayama, Japan, and were enrolled between 2008 and 2009 in a study approved by the Ethical Committee of Okayama University Graduate School of Medicine, Dentistry and Pharmaceutical Sciences, Okayama, Japan. Written informed consent was obtained from all patients before enrollment in the study. The selection criteria was for patients with rectal cancer who were at least 20 years old, were scheduled to undergo a surgical procedure, and had no previous history of use of hemostatic materials at the surgical site. Patients who underwent surgery for rectal cancer and did not receive any conventional hemostatic methods during the same period were selected as a control group.

PuraMatrix preparation

The PuraMatrix hydrogel peptide is a synthetic peptide consisting of a 16-amino acid sequence (AcN-RADARADARADAR ADA-CNH₂) and devoid of animal-derived materials and pathogens and, hence, risk of infection (9). PuraMatrix stock solution (Becton Dickinson Biosciences, Franklin Lakes, NJ) at a concentration of 10 mg peptide/ml was used in this clinical study.

Surgical procedure

During surgery for rectal cancer, after removing as much of the blood as possible, 2 mL PuraMatrix per 5 cm² was applied to the bleeding wound surface followed by another application of 2 mL PuraMatrix per 5 cm². If hemostasis was not obtained, then the above procedure was repeated. After hemostasis was confirmed, excess PuraMatrix was carefully washed off with normal saline (Fig. 2). A closed drain was placed near the area where PuraMatrix was applied. The period of time between immediately after the surgery and 7:00 AM on the following morning is defined as Day 1 after surgery. The drain was removed on Day 4 or when the drainage volume was less than 20 ml. Adverse events and systemic findings were monitored beginning one week before surgery and up to 14 days after surgery during the stay in the hospital. The patients were also followed-up every 4 to 6 months for 2 years in outpatient care.

Assessments

The primary endpoint of the study was the sealing effects of PuraMatrix and the secondary endpoints were safety, amount of bleeding, and time required for hemostasis

during surgery. The sealing efficacy was assessed based on the post-operative drainage volume in a closed drain placed near the area where the hemostatic agent had been dispersed. The hemostatic effects were also evaluated for hemostatic status 5 minutes after the perioperative use of PuraMatrix.

Blood chemistry

Blood samples were obtained on pre-operative day 1 and on post-operative days 1, 4, 7 and 14. Samples were analyzed for CRP (c-reactive protein), WBC (white blood cell), AST (aspartate transaminase), ALT (alanine transaminase), creatinine, and BUN (blood urea nitrogen) by standard laboratory methods.

Statistical analysis

Data were analyzed by Student's t-test or Chi-Square test. $p \leq 0.05$ was considered to be significant.

RESULTS

A total of 20 patients who underwent surgery for rectal cancer were evaluated in this study. Of these, 10 patients received PuraMatrix as a hemostatic agent during surgery. The other 10 patients received no conventional hemostatic agents during the same period and were analyzed as a control group. The clinical characteristics of the patient population are shown in Table 1. In the group for which PuraMatrix was used, the age ranged from 46 years old to 73 years old (average age: 65 years old) with 6 males and 2 females, and none of patients

enrolled in either the PuraMatrix or control groups had any previous history of surgery or use of hemostatic agents at the surgical site. There was no significant difference in age, stage of disease, or location of the cancer between patients who received PuraMatrix and the control group.

During hospitalization, each patient's general status was observed on a daily basis and blood tests were performed on Days 1, 4, and 7 after surgery. No significantly abnormal findings were observed in any of the PuraMatrix-treated patients with regard to CRP, WBC, AST, ALT, creatinine, or BUN (Fig. 3). No patients treated with PuraMatrix experienced significant discomfort and, within the follow-up period of 2 to 3 months after the surgery, there were no complications related to the use of PuraMatrix, suggesting the potential safety of PuraMatrix in human.

In observations conducted 5 minutes after the perioperative use of PuraMatrix, it was confirmed that hemostasis was obtained without fail in all patients. No complications were observed with the perioperative hemostasis, and no postoperative hemorrhaging was observed in any of patients in the study. No significant difference was observed in surgery time, amount of bleeding during surgery, duration of hospitalization, or duration of drain insertion between the PuraMatrix and control groups (Table 2).

The patients treated with PuraMatrix generated significantly less post-operative pelvic drainage fluid compared with patients in the control group ($P < 0.01$) (Fig. 4). The drained fluid from all patients including the control group was clear, not bloody. After the removal of the drain, the patients were found to have no accumulation of ascites either in the PuraMatrix-treated or control groups.

Finally, in order to determine whether PuraMatrix has any homology with known human proteins, we searched a variety of gene databases. We found no homology with any

full-length or partial-length sequences (Table 3).

DISCUSSION

A serious concern during pelvic surgery for rectal cancer is damage to the sacral venous plexus, which can lead to massive bleeding. Therefore the selection of appropriate measures to stop bleeding are extremely important (13). Moreover, once bleeding occurs, there is an increased post-operative drainage volume even after appropriate hemostasis. Although peritoneal fluid accumulation is usually asymptomatic, there is a risk of complications such as infection of the ascitic fluid even in the absence of a contiguous source of infection or an intra-abdominal inflammatory focus (14). The present study investigated the potential application of synthetic peptide fragments that self-assemble into a nano-fiber structure as a bio-compatible sealing material to reduce the post-operative ascitic fluid accumulation after pelvic surgery in human.

PuraMatrix (acetyl-(argininyl-alanyl-aspartyl-alanine)₄-amide; molecular weight: 1,713) is a 16-residue, synthetic peptide solution consisting of a repeat sequence of arginine-alanine-aspartic acid-alanine and has no particular pharmacological activity (9). When the peptides of PuraMatrix come into contact with blood and tissue fluids, the pH and salt concentration of the fluids cause nanofiber self-assembly and gelation, which blocks the blood vessels in the hemorrhagic area and results in a hemostatic effect. The gelation of PuraMatrix is caused only by changes in pH and salt concentration and requires no interaction with biological molecules. PuraMatrix was originally developed as a functional culture medium, but has since been used in experimental animals for wound healing and bone regeneration. Additionally, the efficacy of PuraMatrix as a hemostatic agent has been demonstrated in experimentally-induced injury in rodents. The non-clinical efficacy of

PuraMatrix as a hemostatic material has been verified in rat cortex incision models, rabbit abdominal aortic perforation models, and rabbit liver partial resection models and was shown to be comparable to other hemostatic materials (absorbent local hemostatic materials using collagen) and hemostatic agents (fibrin glue) currently used in clinical settings. These findings led us to examine whether PuraMatrix could seal the disrupted lymphatic tissues and reduce the volume of post-operative peritoneal effusion when used for hemostasis in human.

We found that when hemostasis measures taken during surgery involving compression, suturing, or the like were ineffective or could not be performed, PuraMatrix stopped bleeding during in 10/10 cases. Moreover, there was no bloody drainage from the drain after surgery and there was significantly less drainage volume in the PuraMatrix group over the first few days after surgery. This suggests that PuraMatrix has a long-lasting sealing effect. Furthermore, none of the patients exhibited any obvious adverse events, and in the blood tests performed on Days 1, 4, and 7 after surgery none of the patients had any abnormal values believed to be caused by PuraMatrix. Thus, PuraMatrix is a safe and effective sealing material for preventing lymphorrhea after pelvic surgery.

Compared to other hemostatic or sealing materials, there are significant advantageous properties of PuraMatrix. Firstly, PuraMatrix is a clear material. It does not block the field of view, which is particularly important during endoscopic surgery making it is easy to determine whether the hemostatic effects have been achieved. In contrast, conventional hemostatic or sealing materials can block the surgical field, making application within a narrow field difficult (11, 12). Additionally, other agents might cloud the drainage fluid, whereas no such opacity of the drainage fluid was observed after the use of PuraMatrix. Secondly, PuraMatrix is applied as a solution and only gels when it comes into contact with body fluids, making it easy to apply. In many cases, conventional hemostasis is attempted

with ablation, clips, or solid hemostatic materials that are collagenous and are often difficult to apply during endoscopic surgery (13). In the current study, it was possible to readily apply PuraMatrix through an 8 Fr feeding tube inserted from a 5-mm trocar through the left lower abdomen and guided to the sacrum using a forceps during a laparoscopic high anterior resection. Good hemostasis and sealing was obtained without blocking the field of view. Thirdly, PuraMatrix is a synthetic product and is therefore free of infectious agents; in our study, there were no cases of surgical site infections. In contrast, existing hemostatic sealing materials that are in clinical use are produced from bovine collagen, or fibrin glue produced from blood preparations, leading to concerns regarding possible viral infections. Fourthly, PuriMatrix has no known homology with other signaling proteins.

In conclusion, the present study is the first report indicating the safety and sealing efficacy of PuraMatrix in humans. It is believed that not only will it be a significant case of the clinical application of nanotechnology in the field of surgery, but it will also eliminate the potential risk of infection caused by existing sealing agents that have been used for years, thus leading to improvements in safety for pelvic surgery for rectal cancer.

ACKNOWLEDGEMENTS

We thank Dr. Ann Kyle for editorial assistance. This work was supported in part by grants from the Ministry of Education, Culture, Sports, Science, and Technology of Japan and by grants from the Ministry of Health, Labour, and Welfare of Japan.

DISCLOSURE STATEMENT

All authors state that they have no potential conflicts of interest.

REFERENCES

- 1 Kim WT, Ham WS, Koo KC, Choi YD: Efficacy of octreotide for management of lymphorrhea after pelvic lymph node dissection in radical prostatectomy. *Urology* 2010;**76**:398-401.
- 2 Ghezzi F, Uccella S, Cromi A, Bogani G, Robba C, Serati M, *et al.*: Lymphoceles, lymphorrhea, and lymphedema after laparoscopic and open endometrial cancer staging. *Ann Surg Oncol* 2012;**19**:259-67.
- 3 White M, Mueller PR, Ferrucci JT, Jr., Butch RJ, Simeone JF, Neff CC, *et al.*: Percutaneous drainage of postoperative abdominal and pelvic lymphoceles. *AJR Am J Roentgenol* 1985;**145**:1065-9.
- 4 Benoit L, Boichot C, Cheynel N, Arnould L, Chauffert B, Cuisenier J, *et al.*: Preventing lymphedema and morbidity with an omentum flap after ilioinguinal lymph node dissection. *Ann Surg Oncol* 2005;**12**:793-9.
- 5 Sawhney R, D'Agostino HB, Zinck S, Rose SC, Kinney TB, Oglevie SB, *et al.*: Treatment of postoperative lymphoceles with percutaneous drainage and alcohol sclerotherapy. *J Vasc Interv Radiol* 1996;**7**:241-5.
- 6 Appenrodt B, Lehmann LE, Thyssen L, Gentemann M, Rabe C, Molitor E, *et al.*: Is detection of bacterial DNA in ascitic fluid of clinical relevance? *Eur J Gastroenterol Hepatol* 2010;**22**:1487-94.
- 7 Urbach DR, Kennedy ED, Cohen MM: Colon and rectal anastomoses do not require routine drainage: a systematic review and meta-analysis. *Ann Surg* 1999;**229**:174-80.
- 8 Liu CL, Fan ST, Lo CM, Wong Y, Ng IO, Lam CM, *et al.*: Abdominal drainage after hepatic resection is contraindicated in patients with chronic liver diseases. *Ann Surg* 2004;**239**:194-201.
- 9 Zhang S, Holmes T, Lockshin C, Rich A: Spontaneous assembly of a self-complementary oligopeptide to form a stable macroscopic membrane. *Proc Natl Acad Sci U S A* 1993;**90**:3334-8.
- 10 Ellis-Behnke RG, Liang YX, Tay DK, Kau PW, Schneider GE, Zhang S, *et al.*: Nano hemostat solution: immediate hemostasis at the nanoscale. *Nanomedicine* 2006;**2**:207-15.
- 11 Schonauer C, Tessitore E, Barbagallo G, Albanese V, Moraci A: The use of local agents: bone wax, gelatin, collagen, oxidized cellulose. *Eur Spine J* 2004;**13 Suppl 1**:S89-96.
- 12 Seyednejad H, Imani M, Jamieson T, Seifalian AM: Topical haemostatic agents. *Br J Surg* 2008;**95**:1197-225.

- 13 D'Ambra L, Berti S, Bonfante P, Bianchi C, Gianquinto D, Falco E: Hemostatic step-by-step procedure to control presacral bleeding during laparoscopic total mesorectal excision. *World J Surg* 2009;**33**:812-5.
- 14 Enomoto H, Inoue S, Matsuhisa A, Aizawa N, Imanishi H, Saito M, *et al.*: Development of a new in situ hybridization method for the detection of global bacterial DNA to provide early evidence of a bacterial infection in spontaneous bacterial peritonitis. *J Hepatol* 2012;**56**:85-94.

Figure Legends

FIGURE 1. Structure and gelation of PuraMatrix. (A) PuraMatrix consists of a repeat sequence of arginine-alanine-aspartic acid-alanine. Under physiological pH and salt concentrations, PuraMatrix (B) self-assembles into sheets, (C) forms nanofibers, and then (D) gels. Thus, gelation of PuraMatrix is caused by contact with body fluids and consequent changes in pH and salt concentration; it requires no interaction with biological molecules.

FIGURE 2. Application of PuraMatrix. (A) Proper compression was applied around the bleeding site and as much blood was removed as possible using normal saline and gauze, etc. (B) PuraMatrix (2 ml per 5 cm²) was applied to the bleeding surface, followed by another application of 2 ml per 5 cm² PuraMatrix. If no hemostasis occurred, the above procedure was repeated. After an application, 2 to 3 minutes were allowed for hemostasis. c After hemostasis was confirmed, excess hemostatic material was washed away with normal saline.

FIGURE 3. Blood test data for patients in which PuraMatrix was used (P1 to P10). Blood tests were conducted before surgery and on Days 1, 4, 7, and 14 after surgery for CRP, WBC, AST, ALT, creatinine, and BUN. Case 3 is a subject with multiple hepatic metastases who presented with a neoplastic inflammation reaction before surgery, and improvements relative to the preoperative levels were seen immediately after the surgery. None of the patients presented with AST or ALT levels exceeding 1.5 times the normal ranges observed at our hospital. Cases 4 and 7 are patients with chronic renal failure, but no deterioration was observed in creatinine or BUN levels after the surgery compared to the values before surgery.

FIGURE 4. The post-operative drainage volume of a closed drain placed near the area where the PuraMatrix had been dispersed was evaluated for sealing efficacy. The drainage fluid was collected and the total volume was measured. The drain was removed on Day 4 or when the drainage volume was less than 20 ml. * $P < 0.01$

Fig. 1

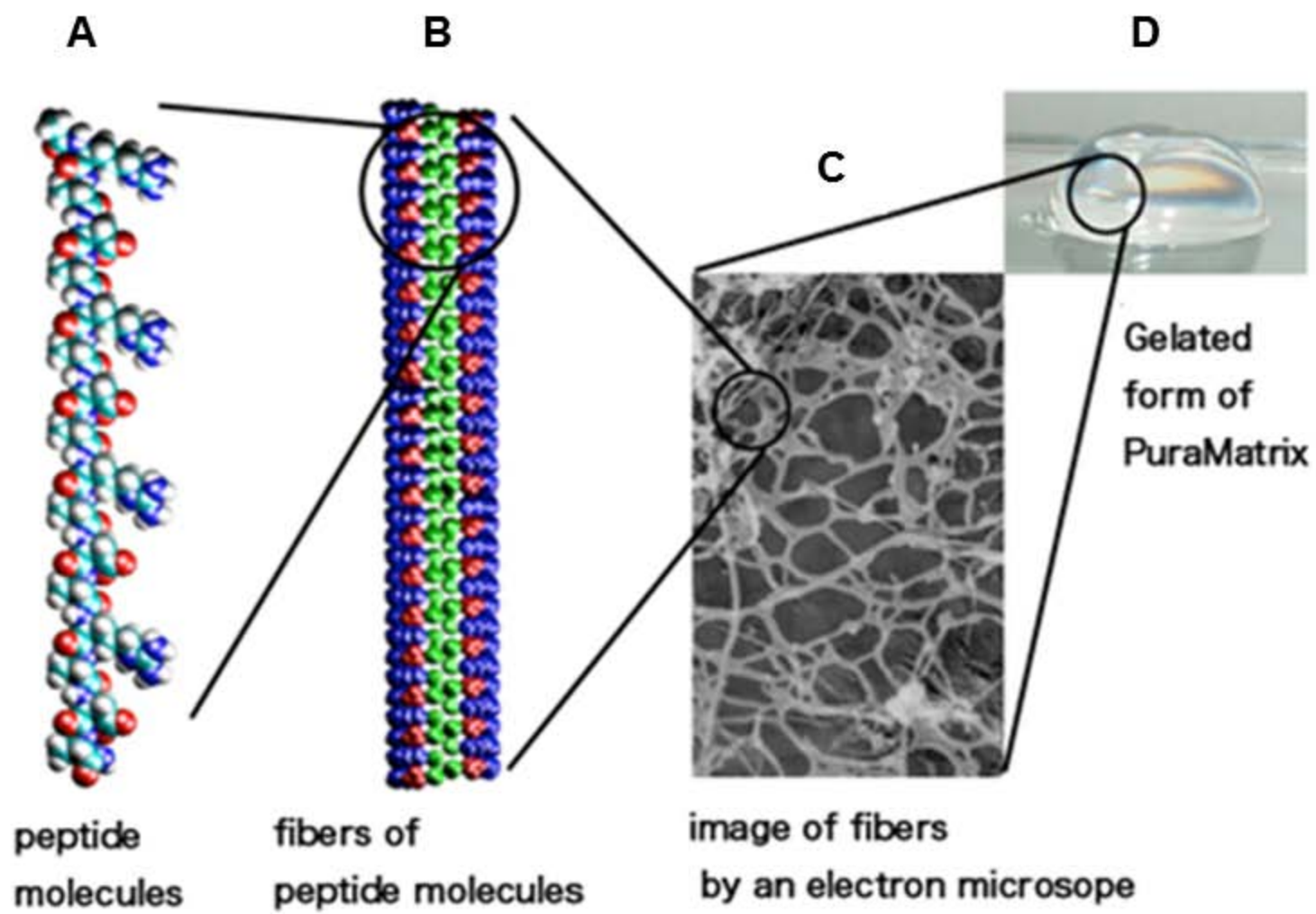
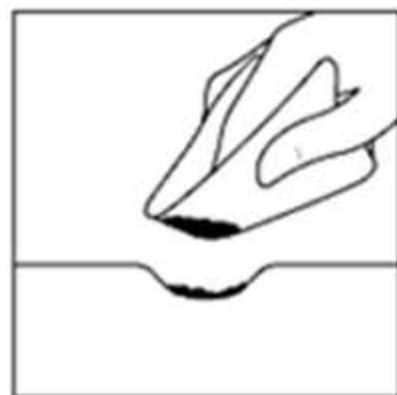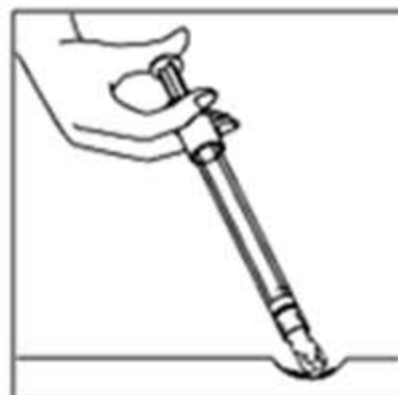


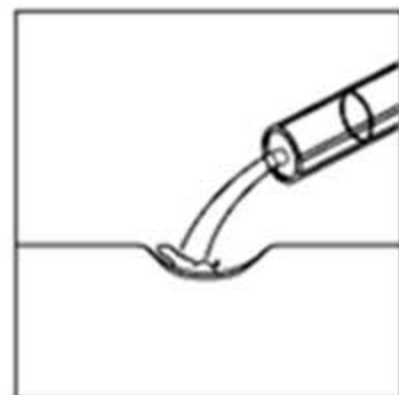
Fig. 2



A



B



C

Fig. 3

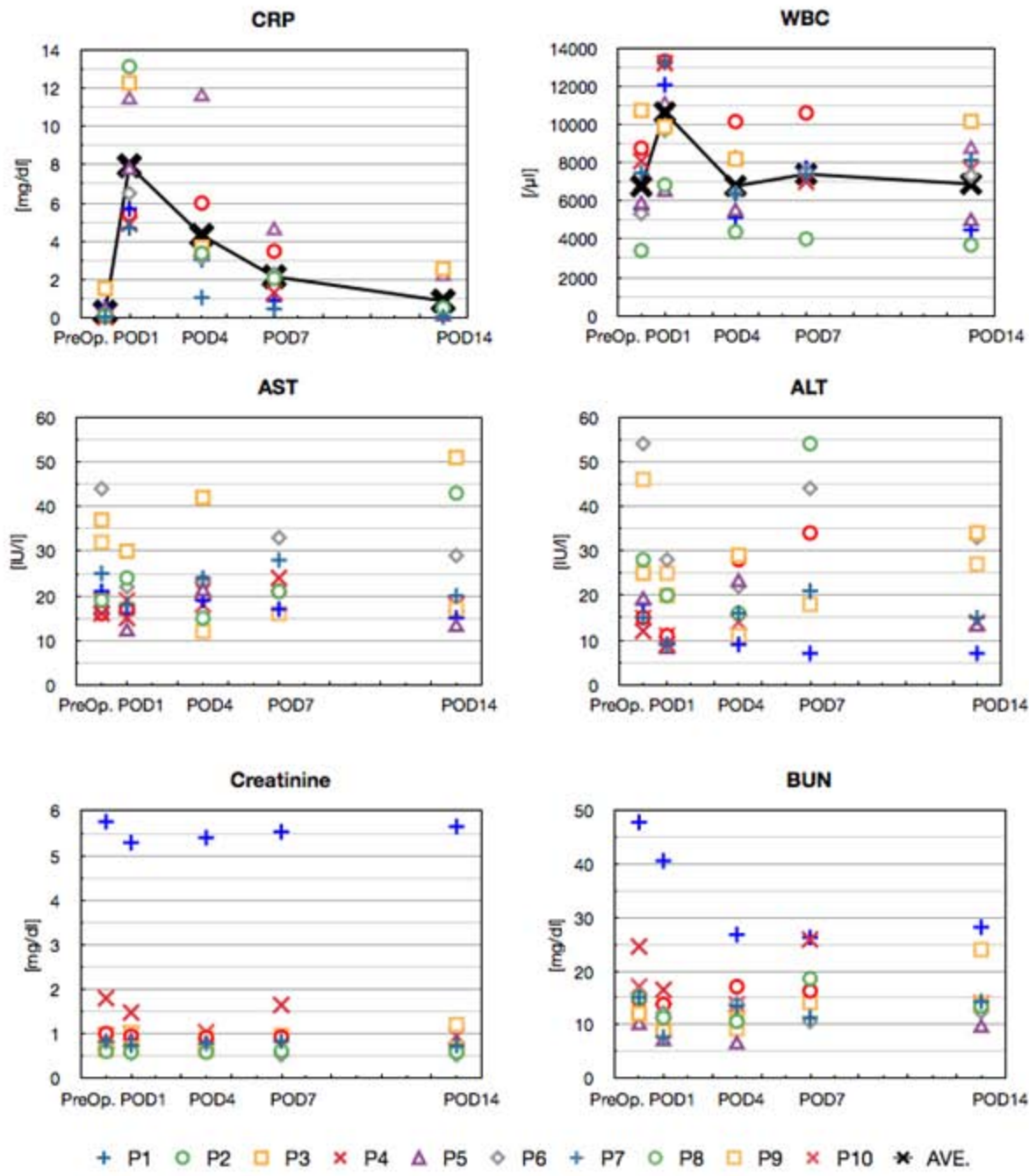


Fig. 4

