

Specific endoscopic features of ulcerative colitis complicated by cytomegalovirus infection

Hideyuki Suzuki, Jun Kato, Motoaki Kuriyama, Sakiko Hiraoka, Kenji Kuwaki, Kazuhide Yamamoto

Hideyuki Suzuki, Jun Kato, Motoaki Kuriyama, Sakiko Hiraoka, Kenji Kuwaki, Kazuhide Yamamoto, Department of Gastroenterology and Hepatology, Okayama University Graduate School of Medicine, Dentistry, and Pharmaceutical Sciences, Okayama 700-8558, Japan

Author contributions: Suzuki H contributed to planning, data collection, statistical analysis, and drafting the manuscript; Kato J performed clinical examination, statistical analysis and drafted the manuscript; Kuriyama M contributed to clinical examination and statistical analysis; Hiraoka S performed clinical examination; Kenji Kuwaki performed statistical analysis; Yamamoto K and Kato J contributed to manuscript direction.

Correspondence to: Jun Kato, MD, Department of Gastroenterology and Hepatology, Okayama University Graduate School of Medicine, Dentistry, and Pharmaceutical Sciences, 2-5-1, Shikata-cho, Kita-ku, Okayama 700-8558, Japan. katojun@cc.okayama-u.ac.jp

Telephone: +81-86-2357219 Fax: +81-86-2255991

Received: November 14, 2009 Revised: January 20, 2010

Accepted: January 27, 2010

Published online: March 14, 2010

Abstract

AIM: To identify specific colonoscopic findings in patients with ulcerative colitis (UC) complicated by cytomegalovirus (CMV) infection.

METHODS: Among UC patients who were hospitalized due to exacerbation of symptoms, colonoscopic findings were compared between 15 CMV-positive patients and 58 CMV-negative patients. CMV infection was determined by blood test for CMV antigenemia. Five aspects of mucosal changes were analyzed (loss of vascular pattern, erythema, mucosal edema, easy bleeding, and mucinous exudates) as well as five aspects of ulcerative change (wide mucosal defect, punched-out ulceration, longitudinal ulceration, irregular ulceration, and cobblestone-like appearance). Sensitivity, specificity, positive predictive value, and negative predictive value of each finding for CMV positivity were determined.

RESULTS: The sensitivity of irregular ulceration for positive CMV was 100%. The specificity of wide mucosal defect was 95%. Punched-out ulceration and longitudinal ulceration exhibited relatively high sensitivity and specificity (more than 70% for each).

CONCLUSION: Specific colonoscopic findings in patients with UC complicated by CMV infection were identified. These findings may facilitate the early diagnosis of CMV infection in UC patients.

© 2010 Baishideng. All rights reserved.

Key words: Cytomegalovirus; Endoscopic findings; Ulcerative colitis

Peer reviewers: Marc Basson, MD, PhD, MBA, Chief of Surgery, John D. Dingell VA Medical Center, 4646 John R. Street, Detroit, MI 48301, United States; Sri P Misra, Professor, Gastroenterology, Moti Lal Nehru Medical College, Allahabad 211001, India

Suzuki H, Kato J, Kuriyama M, Hiraoka S, Kuwaki K, Yamamoto K. Specific endoscopic features of ulcerative colitis complicated by cytomegalovirus infection. *World J Gastroenterol* 2010; 16(10): 1245-1251 Available from: URL: <http://www.wjgnet.com/1007-9327/full/v16/i10/1245.htm> DOI: <http://dx.doi.org/10.3748/wjg.v16.i10.1245>

INTRODUCTION

Ulcerative colitis (UC) is a worldwide, chronic, idiopathic, inflammatory disease of the rectal and colonic mucosa. Patients with UC suffer from abdominal pain, diarrhea with blood, tenesmus, and urgency to defecate. In Japan, the number of patients with UC was reported to be only 4400 in 1980. However, the number has increased sharply in recent years, and was estimated to be approximately 100 000 persons in 2008. This number is thought to

increase by about 5000 persons each year.

Cytomegalovirus (CMV) belongs to the herpes virus group and is prevalent in adults. Primary CMV infection in immunocompetent people is usually asymptomatic, but the virus remains in the white blood cells throughout the life of the host. Clinically significant diseases occur in patients with suppressed cellular immunity, especially in transplant patients, acquired immunodeficiency syndrome (AIDS) patients, and patients undergoing chemotherapy. The disease is usually the result of reactivation of the latent virus rather than reinfection with the virus. Significant CMV disease may occur in various organs such as the retina, lung, and gastrointestinal tract, and the target organ may be related to the etiology of immunosuppression. In the gastrointestinal tract, CMV disease can occur in all locations from the mouth to the rectum, and usually forms ulcers in the mucosa, often accompanied by hemorrhage^[1].

CMV infection has been described as a cause of relapse of inflammatory bowel disease^[2-5]. In particular, CMV infection was observed in UC patients, especially those receiving high-dose corticosteroid therapy^[4-7]. Moreover, CMV infection can exacerbate the disease^[2-5]. Retrospective studies of UC patients have found CMV infection in 5%-21% of surgically resected specimens^[2-4,8]. Steroid resistance is also reported to be one of the characteristics of CMV infection in UC^[6,8]. In recent prospective studies, 25%-81% of patients with steroid-refractory UC were found to harbor the virus^[5-7]. Thus, CMV infection in UC patients can have a severe clinical course and may cause death if appropriate treatment is not given. However, with the development of ganciclovir (GCV) therapy, outcomes have greatly improved^[9].

Therefore, it is necessary to make an early diagnosis of CMV infection in UC patients. Although several different methods have been developed to examine CMV infection, such as histology including immunohistochemistry^[10,11], serology^[10-12], CMV culture^[13,14], polymerase chain reaction (PCR) for CMV genome^[14-16], and CMV antigenemia^[14-16], it is necessary, with regard to clinical aspects, to suspect that UC patients also have CMV infection. In general, the symptoms of UC alone are not sufficient to distinguish exacerbation of UC due to CMV infection from exacerbation of UC unrelated to CMV infection. Specific colonoscopic findings for CMV infection, if any, may facilitate the early diagnosis of CMV infection.

Several reports have examined colonoscopic findings related to CMV infection. However, most of these reports focused on colonoscopic findings in patients with AIDS or in transplant patients^[17,18]. The spectrum of colonoscopic findings in those patients was variable and ranged from patchy erythema, exudates, and microerosions to diffusely edematous mucosa, multiple mucosal erosions, deep ulcers and pseudotumors^[1,13,17-22]. In contrast, colonoscopic findings of UC complicated by CMV infection have rarely been reported. Only a few studies have described findings without confirmation by statistical analysis^[20].

Accordingly, the aim of this study was to identify specific colonoscopic findings in patients with UC complicated by CMV infection. To achieve this, we compared

colonoscopic findings in CMV-positive and -negative patients, and determined the sensitivity, specificity, positive predictive value (PPV) and negative predictive value (NPV) of each specific finding for CMV positivity.

MATERIALS AND METHODS

Patients

This study was a retrospective analysis of medical charts and endoscopic images of UC patients. From January 1999 to August 2007, a total of 200 UC patients were hospitalized in Okayama University Hospital with exacerbation of UC symptoms. We began to routinely examine CMV antigenemia in these patients from 2003. Therefore, of these 200 patients, 111 did not receive a blood test for CMV antigenemia at admission, and 13 did not receive an endoscopic examination. Thus, a total of 76 patients who received both a blood test for CMV antigenemia and an endoscopic examination at admission were analyzed in this study. This study was approved by the institutional review board of Okayama University Graduate School of Medicine, Dentistry, and Pharmaceutical Sciences.

The diseases in these patients were pancolitis or left-sided colitis with moderate or severe activity, based on clinical, endoscopic, and histological findings according to established criteria^[23-25]. Medical charts provided clinical parameters including demographic data such as age, gender, and duration of the disease, as well as disease status such as severity of disease, extent of disease, and medications.

Diagnosis of CMV infection

Diagnosis of CMV infection was determined by CMV antigenemia, which was examined by detecting CMV pp65 antigen in peripheral blood leukocytes using the direct immunoperoxidase technique with horseradish peroxidase-conjugated Fab' fragment of human monoclonal antibody (C7-HRP) and immunofluorescence staining with monoclonal antibodies C10/11. The examinations were performed in the laboratory of SRL Inc. (Tokyo, Japan). We defined a patient as CMV-positive when one or more positive cells of either C7-HRP or C10/11 were detected in more than 10 000 leukocytes (the minimum number of positive cells).

Endoscopic findings

Endoscopic findings were evaluated by examining recorded colonoscopic images and reports. Two aspects of colonic changes were assessed: mucosal change and ulcerative change. Mucosal change was evaluated according to the following five features: easy bleeding, loss of vascular pattern, mucosal edema, erythema, and mucinous exudates. Each item was expressed as "severe" or "not severe" according to the severity of each change. Easy bleeding was defined as bleeding from the fragile membrane due to slight contact of the endoscope. Loss of vascular pattern was loss of visible vessels under the

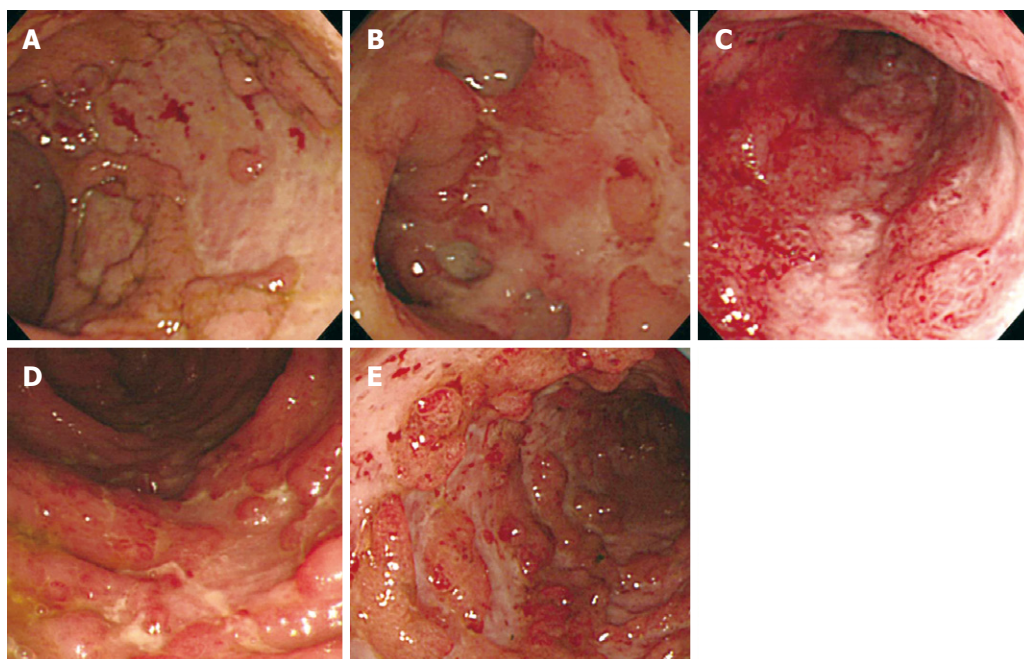


Figure 1 Typical endoscopic findings of ulcerative changes. A: Wide mucosal defect; B: Punched-out ulceration; C: Longitudinal ulceration; D: Irregular ulceration; E: Cobblestone-like appearance.

membrane, generally seen during colonoscopy. Mucosal edema was defined as thick and swollen membrane which pooled fluid. Erythema was red coloration of the membrane composed of dilated veins. Mucinous exudates were exudates composed of blood and pus.

For ulcerative changes, we determined whether or not the following forms of ulceration were observed: wide mucosal defect, punched-out ulceration, longitudinal ulceration, irregular ulceration, and cobblestone-like appearance. A wide mucosal defect was a wide area of this defect with a longitudinal and/or transverse spread, indicating that more than one-fourth of the mucosa in the endoscopic field was defective (Figure 1A). Punched-out ulceration formed an almost round shape of ulceration with clear demarcation (Figure 1B). Longitudinal ulceration had a longitudinal spread along the lumen of the colon (Figure 1C). Irregular ulceration was defined as ulceration with an irregular pattern and a branched shape (Figure 1D). Cobblestone-like appearance was an aggregate of elevated lesions as a result of the changes in the membrane, which looked like half-spheres of subpedunculated polyps with multiple ulceration as seen in Crohn's disease (Figure 1E). Each endoscopic image was evaluated by two (Suzuki H and Kato J) of the authors. If there were any disagreements in these evaluations, a third reviewer (Hiraoka S) made the final evaluation. At the time of interpretation of the images, the CMV antigenemia results were blinded to interpreters. The rate of disagreements between the two authors was less than 5%.

Statistical analysis

Of the clinical characteristics, the χ^2 test and Fisher's exact test were used to compare two discrete variables. The significance of differences for continuous variables was assessed by the Mann-Whitney *U*-test. Of the endoscopic findings, we calculated sensitivity, specificity, PPV, and

NPV for CMV positivity. In addition, odds ratios (OR) with 95% CI were determined by a univariate logistic regression model. The results were considered statistically significant when *P* values were less than 0.05. Statistical analysis of the data was carried out with SAS software version 9.2 (SAS Institute, Cary, NC, USA).

RESULTS

Patients

A total of 76 patients received a blood test for CMV antigenemia and a colonoscopy at admission. Of these, 18 patients were positive for CMV antigenemia, while the remaining 58 patients were negative. Of the 18 CMV-positive patients, symptoms in 3 patients were relatively mild, and those patients entered remission without antiviral therapy. The remaining 15 patients required GCV therapy for a period of two weeks, together with dose reduction of corticosteroids. As a consequence of these treatments, all patients entered remission. Therefore, a comparative analysis was performed on 15 CMV-positive patients *vs* 58 CMV-negative patients.

The clinical characteristics of these 73 patients are shown in Table 1. There were no significant differences in clinical characteristics such as gender, age, duration of disease, disease activity, extent of disease, use of corticosteroids, and use of immunomodulators (azathioprine or mercaptopurine) between CMV-positive and -negative patients. It is noteworthy that all the CMV-positive patients received corticosteroid therapy.

Specific endoscopic findings of UC with CMV infection

To identify specific endoscopic findings of UC complicated by CMV infection, five aspects of mucosal changes (loss of vascular pattern, erythema, mucosal edema, easy bleeding, and mucinous exudates) as well as five aspects of ulcerative change (wide mucosal defect, punched-out

Table 1 Characteristics of enrolled patients

	CMV positive (n = 15)	CMV negative (n = 58)	P value
Gender			
Male	8 (53)	26 (45)	0.55
Female	7 (47)	32 (55)	
Age (yr), median (range)	42 (17-65)	34 (14-81)	0.72
Duration of disease (d), median (range)	528 (15-9358)	1503 (5-10791)	0.40
Disease activity at admission			
Moderate	9 (60)	41 (71)	0.43
Severe	6 (40)	17 (29)	
Extent of disease			
Pancolitis	12 (80)	42 (72)	0.74
Left-sided	3 (20)	16 (28)	
Current use of corticosteroids			
Yes	15 (100)	47 (81)	0.11
No	0 (0)	11 (19)	
Current use of immunomodulators (AZA/6-MP)			
Yes	1 (7)	7 (12)	> 0.99
No	14 (93)	51 (88)	

Data are numbers with percentages in parentheses or medians with ranges in parentheses. CMV: Cytomegalovirus.

ulceration, longitudinal ulceration, irregular ulceration, and cobblestone-like appearance) were analyzed. The sensitivity, specificity, PPV and NPV of each finding for CMV positivity were determined. In addition, univariate logistic regression analyses were performed to determine the OR and 95% CI of each finding (Table 2).

Of the 5 mucosal changes, loss of vascular pattern, edema, and erythema exhibited relatively high sensitivity for CMV positivity (87%, 80%, and 87%, respectively), whereas easy bleeding and mucinous exudates exhibited high specificity (88% and 81%, respectively). Of the 5 ulcerative changes, irregular ulceration showed 100% sensitivity, but relatively low specificity (41%). Wide mucosal defect and cobblestone-like appearance showed relatively high specificity (95% and 83%, respectively), but low sensitivity. The sensitivity and specificity of punched-out ulceration and longitudinal ulceration were both relatively high (punched-out ulceration, sensitivity 80%, specificity 74%, longitudinal ulceration sensitivity 73%, specificity 78%, respectively).

Univariate logistic regression analysis revealed that severe easy bleeding was seen more frequently in CMV-positive patients than in CMV-negative patients (OR = 2.20, 95% CI: 1.14-4.28). Wide mucosal defect (OR = 4.58, 95% CI: 2.21-10.73), punched-out ulceration (OR = 3.39, 95% CI: 1.78-7.46), longitudinal ulceration (OR = 3.09, 95% CI: 1.66-6.26), and cobblestone-like appearance (OR = 2.05, 95% CI: 1.11-3.82) were more frequently observed in CMV-positive patients than in CMV-negative patients.

DISCUSSION

Colonoscopy is generally performed in UC patients who undergo flare-ups. Direct observation of the colon provides detailed information on the disease status and is useful for comprehending the severity of disease, and thus it is an important tool for formulating

treatments. However, although CMV infection can cause poor prognosis in UC patients (i.e. a high chance of colectomy), reports on the specific colonoscopic findings of UC with CMV infection are scarce. Therefore, in this study we analyzed the colonoscopic findings of UC patients with and without CMV infection, and showed that there were specific findings that predicted CMV infection in UC patients.

There have been reports on the endoscopic findings of CMV colitis in AIDS or transplant patients. These findings include patchy erythema, exudates, microerosions, diffusely edematous mucosa, multiple mucosal erosions, or deep ulcers and pseudotumors^[1,13,17-22]. In UC patients, however, the findings would be more complicated, because inflammatory changes due to UC itself in colonic mucosa exists prior to CMV infection. Therefore, in previous studies, no specific endoscopic findings were observed in UC patients with concomitant CMV infection^[6,26]. In contrast, in our study, specific colonoscopic findings of UC with CMV infection were observed; the sensitivity of irregular ulceration was 100%, the specificity of wide mucosal defect was 95%, and the sensitivity and specificity of punched-out ulceration and longitudinal ulceration were both greater than 70%. Therefore, in cases where these colonoscopic findings are seen in UC patients, examination to confirm CMV infection should be performed as soon as possible.

It is known that UC patients with CMV infection, especially those who are compromised by corticosteroid therapy, experience severe symptoms. These patients are likely to undergo colectomy, and CMV infection has been confirmed in 4.6%-25% of patients who have undergone colectomy^[2,3,7,8]. Recently the efficacy of GCV in CMV infection has become widely recognized. Pfau *et al*^[9] considers GCV a beneficial treatment that significantly decreases the mortality rate and the need for surgery. Wada *et al*^[6] found that GCV was effective in 8 (67%) of 12 patients with CMV infection. They

Table 2 The correlations between CMV positivity and endoscopic findings

	CMV positive (n = 15)	CMV negative (n = 58)	Sensitivity (%)	Specificity (%)	PPV (%)	NPV (%)	Odds ratio	95% CI	P value
Easy bleeding									
Severe	6 (40)	7 (12)	40	88	46	85	2.20	1.14-4.28	0.02
Not severe	9 (60)	51 (88)							
Loss of the vascular pattern									
Severe	13 (87)	37 (64)	87	36	26	91	1.92	0.95-5.01	0.11
Not severe	2 (13)	21 (36)							
Edema									
Severe	12 (80)	33 (57)	80	43	27	89	1.74	0.92-3.79	0.11
Not severe	3 (20)	25 (43)							
Erythema									
Severe	13 (87)	39 (67)	87	33	25	90	1.78	0.88-4.64	0.15
Not severe	2 (13)	19 (33)							
Mucinous exudates									
Severe	4 (27)	11 (19)	27	81	27	81	1.25	0.61-2.36	0.51
Not severe	11 (73)	47 (81)							
Wide mucosal defect									
≥ 1/4 field	8 (53)	3 (5)	53	95	72	89	4.58	2.21-10.73	0.0001
< 1/4 field	7 (47)	55 (95)							
Punched-out ulceration									
Yes	12 (80)	15 (26)	80	74	44	93	3.39	1.78-7.46	0.0006
No	3 (20)	43 (74)							
Longitudinal ulceration									
Yes	11 (73)	13 (22)	73	78	46	92	3.09	1.66-6.26	0.0007
No	4 (27)	45 (78)							
Irregular ulceration									
Yes	15 (100)	34 (59)	100	41	31	100	ND	ND	ND
No	0 (0)	24 (41)							
Cobblestone-like appearance									
Yes	7 (47)	10 (17)	47	83	41	86	2.05	1.11-3.82	0.02
No	8 (53)	48 (83)							

PPV: Positive predictive value; NPV: Negative predictive value; 95% CI: 95% confidence interval; ND: Not determined.

also reported that steroid withdrawal improved steroid-resistant UC. Matsuoka *et al.*^[27] reported that most CMV reactivation-positive patients responded to conventional immunosuppressive therapies, however, high values of CMV antigenemia may be an indicator for antiviral treatment regardless of histology. Thus, treatment for UC patients with CMV infection should be different from that for UC patients without CMV infection. Therefore, our findings that predict CMV infection should be useful in therapeutic decision-making for UC patients.

In addition, there are several studies on the prophylactic/pre-emptive therapy of CMV diseases in patients with solid organ transplants, hematopoietic stem cell transplants, and human immunodeficiency virus disease^[27-29]. These reports suggested the importance of early detection of CMV reactivation and early administration of anti-viral drugs before the development of CMV disease. Although no concept of prophylactic therapy has been established for UC patients, early detection and early antiviral therapy may be considered because of the high rate of colectomy in these patients. In this context, early prediction of CMV infection in UC patients by colonoscopy would seem helpful in clinical settings.

There are several methods of detecting CMV infection: histology including immunohistochemistry^[10,11], serology^[10-12], CMV culture^[13,14], PCR for CMV ge-

nome^[14-16], and CMV antigenemia^[14-16]. Each method has advantages and disadvantages for the precise diagnosis of CMV infection. For example, histological examination is a relatively easy method, but the sensitivity is not so high (10%-87%)^[10-12]. Meanwhile, PCR for the CMV genome is very sensitive, but the false-positive rate is relatively high. In our analysis, CMV antigenemia was adopted to detect CMV infection, because examination of CMV antigenemia is relatively sensitive (60%-100%) and easy to measure within a short period^[10,14,16,30]. In addition, this method has been used for monitoring CMV infection in heart transplant recipients, and for the early diagnosis of CMV infection in renal transplant recipients^[29]. Moreover, it has been reported that positive or negative results of CMV antigenemia are a good indication for antiviral therapy^[28,31]. In fact, in our study, 15 (83%) of 18 patients who were positive for CMV antigenemia required antiviral therapy with GCV, and all of these patients entered remission without colectomy. In general, immunohistochemistry is considered the gold standard in the diagnosis of CMV infection. In our cohort, however, among 6 patients with positive CMV antigenemia whose biopsy specimens were immunostained with antibody for CMV, only 3 exhibited positive immunostaining. In addition, although we performed immunostaining in 16 of 58 patients with negative CMV

antigenemia, none of them exhibited positive staining. Therefore, the use of CMV antigenemia for CMV detection in this study was appropriate.

Our study has several limitations. First, CMV infection was determined by CMV antigenemia alone. As described above, there are several methods to detect CMV infection. A combination of these methods may have increased the CMV detection rate. Second, of the 18 CMV antigenemia-positive patients, 15 patients who were given GCV were analyzed in our study. However, it is not certain that all 15 patients really required GCV therapy. Some of these patients may have improved without GCV similar to the remaining 3 patients. Third, this is a retrospective study that relied on the examination of recorded colonoscopic images. Therefore, bias due to patient collection and missed recording of colonoscopic findings may inevitably exist. Finally, this is a relatively small scale study in Japan, and it is possible that the results might differ in patients of other ethnicities from other parts of the world.

In the case of a severe flare-up of UC, the possibility of a concurrent CMV infection causing or worsening colitis should be considered, especially when patients are on immunosuppressive medications that may make them more susceptible to this viral infection. The prognosis of UC cases with CMV infection is considered poor. Thus, CMV infection should be closely investigated in such cases, and anti-CMV treatment (GCV) should be given immediately to reduce the rate of colectomy. The specific colonoscopic findings of patients with UC complicated by CMV infection observed in this study may facilitate early diagnosis and treatment of CMV infection.

COMMENTS

Background

In general, the symptoms of ulcerative colitis (UC) alone are not sufficient to distinguish exacerbation of UC due to CMV infection from exacerbation of UC unrelated to cytomegalovirus (CMV) infection.

Research frontiers

Few studies have reported the colonoscopic findings of UC complicated by CMV infection.

Innovations and breakthroughs

Via retrospective research, authors found specific colonoscopic findings in UC patients with CMV antigenemia.

Applications

Specific colonoscopic findings in patients with UC complicated by CMV infection found in this study may facilitate early diagnosis and treatment of CMV infection.

Peer review

This is a potentially important study that is generally well done, well written, and makes a contribution to the field.

REFERENCES

- 1 **Goodgame RW.** Gastrointestinal cytomegalovirus disease. *Ann Intern Med* 1993; **119**: 924-935
- 2 **Kaufman HS, Kahn AC, Iacobuzio-Donahue C, Talamini MA, Lillemoe KD, Hamilton SR.** Cytomegaloviral enterocolitis: clinical associations and outcome. *Dis Colon Rectum* 1999; **42**: 24-30
- 3 **Takahashi Y, Tange T.** Prevalence of cytomegalovirus infection in inflammatory bowel disease patients. *Dis Colon Rectum* 2004; **47**: 722-726
- 4 **Berk T, Gordon SJ, Choi HY, Cooper HS.** Cytomegalovirus infection of the colon: a possible role in exacerbations of inflammatory bowel disease. *Am J Gastroenterol* 1985; **80**: 355-360
- 5 **Cottone M, Pietrosi G, Martorana G, Casà A, Pecoraro G, Oliva L, Orlando A, Rosselli M, Rizzo A, Pagliaro L.** Prevalence of cytomegalovirus infection in severe refractory ulcerative and Crohn's colitis. *Am J Gastroenterol* 2001; **96**: 773-775
- 6 **Wada Y, Matsui T, Matake H, Sakurai T, Yamamoto J, Kikuchi Y, Yorioka M, Tsuda S, Yao T, Yao S, Haraoka S, Iwashita A.** Intractable ulcerative colitis caused by cytomegalovirus infection: a prospective study on prevalence, diagnosis, and treatment. *Dis Colon Rectum* 2003; **46**: S59-S65
- 7 **Kambham N, Vij R, Cartwright CA, Longacre T.** Cytomegalovirus infection in steroid-refractory ulcerative colitis: a case-control study. *Am J Surg Pathol* 2004; **28**: 365-373
- 8 **Cooper HS, Raffensperger EC, Jonas L, Fitts WT Jr.** Cytomegalovirus inclusions in patients with ulcerative colitis and toxic dilation requiring colonic resection. *Gastroenterology* 1977; **72**: 1253-1256
- 9 **Pfau P, Kochman ML, Furth EE, Lichtenstein GR.** Cytomegalovirus colitis complicating ulcerative colitis in the steroid-naive patient. *Am J Gastroenterol* 2001; **96**: 895-899
- 10 **de la Hoz RE, Stephens G, Sherlock C.** Diagnosis and treatment approaches of CMV infections in adult patients. *J Clin Virol* 2002; **25** Suppl 2: S1-S12
- 11 **Beaugerie L, Cywiner-Golenzer C, Monfort L, Girard PM, Carbonnel F, Ngô Y, Cosnes J, Rozenbaum W, Nicolas JC, Châtelet FP, Gendre JP.** Definition and diagnosis of cytomegalovirus colitis in patients infected by human immunodeficiency virus. *J Acquir Immune Defic Syndr Hum Retrovirol* 1997; **14**: 423-429
- 12 **Kishore J, Ghoshal U, Ghoshal UC, Krishnani N, Kumar S, Singh M, Ayyagari A.** Infection with cytomegalovirus in patients with inflammatory bowel disease: prevalence, clinical significance and outcome. *J Med Microbiol* 2004; **53**: 1155-1160
- 13 **Meyers JD, Ljungman P, Fisher LD.** Cytomegalovirus excretion as a predictor of cytomegalovirus disease after marrow transplantation: importance of cytomegalovirus viremia. *J Infect Dis* 1990; **162**: 373-380
- 14 **Boivin G, Handfield J, Toma E, Murray G, Lalonde R, Tevere VJ, Sun R, Bergeron MG.** Evaluation of the AMPLICOR cytomegalovirus test with specimens from human immunodeficiency virus-infected subjects. *J Clin Microbiol* 1998; **36**: 2509-2513
- 15 **Mazzulli T, Drew LW, Yen-Lieberman B, Jekic-McMullen D, Kohn DJ, Isada C, Moussa G, Chua R, Walmsley S.** Multicenter comparison of the digene hybrid capture CMV DNA assay (version 2.0), the pp65 antigenemia assay, and cell culture for detection of cytomegalovirus viremia. *J Clin Microbiol* 1999; **37**: 958-963
- 16 **Rowshani AT, Bemelman FJ, van Leeuwen EM, van Lier RA, ten Berge IJ.** Clinical and immunologic aspects of cytomegalovirus infection in solid organ transplant recipients. *Transplantation* 2005; **79**: 381-386
- 17 **Wilcox CM, Chalasani N, Lazenby A, Schwartz DA.** Cytomegalovirus colitis in acquired immunodeficiency syndrome: a clinical and endoscopic study. *Gastrointest Endosc* 1998; **48**: 39-43
- 18 **Battaglino MP, Rockey DC.** Cytomegalovirus colitis presenting with the endoscopic appearance of pseudomembranous colitis. *Gastrointest Endosc* 1999; **50**: 697-700
- 19 **Ljungman P, Griffiths P, Paya C.** Definitions of cytomegalovirus infection and disease in transplant recipients. *Clin Infect Dis* 2002; **34**: 1094-1097
- 20 **Nishimoto Y, Matsumoto T, Suekane H, Shimizu M, Mikami Y, Iida M.** Cytomegalovirus infection in a patient

- with ulcerative colitis: colonoscopic findings. *Gastrointest Endosc* 2001; **53**: 816-818
- 21 **Falagas ME**, Griffiths J, Prekezes J, Worthington M. Cytomegalovirus colitis mimicking colon carcinoma in an HIV-negative patient with chronic renal failure. *Am J Gastroenterol* 1996; **91**: 168-169
 - 22 **Roskell DE**, Hyde GM, Campbell AP, Jewell DP, Gray W. HIV associated cytomegalovirus colitis as a mimic of inflammatory bowel disease. *Gut* 1995; **37**: 148-150
 - 23 **Lennard-Jones JE**. Classification of inflammatory bowel disease. *Scand J Gastroenterol Suppl* 1989; **170**: 2-6; discussion 16-19
 - 24 **Gower-Rousseau C**, Salomez JL, Dupas JL, Marti R, Nuttens MC, Votte A, Lemahieu M, Lemaire B, Colombel JF, Cortot A. Incidence of inflammatory bowel disease in northern France (1988-1990). *Gut* 1994; **35**: 1433-1438
 - 25 **Truelove SC**, Witts LJ. Cortisone in ulcerative colitis; final report on a therapeutic trial. *Br Med J* 1955; **2**: 1041-1048
 - 26 **Sakamoto I**, Shirai T, Kamide T, Igarashi M, Koike J, Ito A, Takagi A, Miwa T, Kajiwara H. Cytomegalovirus enterocolitis in an immunocompetent individual. *J Clin Gastroenterol* 2002; **34**: 243-246
 - 27 **Matsuoka K**, Iwao Y, Mori T, Sakuraba A, Yajima T, Hisamatsu T, Okamoto S, Morohoshi Y, Izumiya M, Ichikawa H, Sato T, Inoue N, Ogata H, Hibi T. Cytomegalovirus is frequently reactivated and disappears without antiviral agents in ulcerative colitis patients. *Am J Gastroenterol* 2007; **102**: 331-337
 - 28 **Manteiga R**, Martino R, Sureda A, Labeaga R, Brunet S, Sierra J, Rabella N. Cytomegalovirus pp65 antigenemia-guided pre-emptive treatment with ganciclovir after allogeneic stem transplantation: a single-center experience. *Bone Marrow Transplant* 1998; **22**: 899-904
 - 29 **Bernabeu-Wittel M**, Pachón-Ibáñez J, Cisneros JM, Cañas E, Sánchez M, Gómez MA, Gentil MA, Pachón J. Quantitative pp65 antigenemia in the diagnosis of cytomegalovirus disease: prospective assessment in a cohort of solid organ transplant recipients. *J Infect* 2005; **51**: 188-194
 - 30 **Mori T**, Okamoto S, Matsuoka S, Yajima T, Wakui M, Watanabe R, Ishida A, Iwao Y, Mukai M, Hibi T, Ikeda Y. Risk-adapted pre-emptive therapy for cytomegalovirus disease in patients undergoing allogeneic bone marrow transplantation. *Bone Marrow Transplant* 2000; **25**: 765-769
 - 31 **Boeckh M**, Gooley TA, Myerson D, Cunningham T, Schoch G, Bowden RA. Cytomegalovirus pp65 antigenemia-guided early treatment with ganciclovir versus ganciclovir at engraftment after allogeneic marrow transplantation: a randomized double-blind study. *Blood* 1996; **88**: 4063-4071

S- Editor Tian L L- Editor Webster JR E- Editor Ma WH