

## New Large Bowel Segmentation on Plain Abdominal Radiography in Comparison with the Conventional Method

Kiminari Sawa\*, Takaaki Mizushima, Koki Matsushita, Akinori Shirahige, Koji Ochi, and Norio Koide

Central Clinical Laboratory of Medicine, Okayama University Graduate School of Medicine,  
Dentistry and Pharmaceutical Sciences, Okayama 700-8558, Japan

Plain abdominal radiography is a very basic examination and plays an important role in primary care. The objectives of this study were to clarify colon distributions on plain abdominal radiographs. Forty-three healthy volunteers underwent gastric fluoroscopy, and 2 hours later, plain abdominal radiography in the supine position. A region of interest (ROI) was defined uniformly on each X-ray image to divide the image into 600 zones. The area corresponding to the large bowel within the ROI was divided into 4 segments (ascending colon, transverse colon, descending colon, and sigmoid colon + rectum). The percentage of barium in each segment relative to the total volume of barium used was calculated to evaluate the percent ROI occupancy. The large bowel covered 76.7% of the entire ROI, with the percent duplication being 55%. The duplicated area corresponded to the transverse colon region. When the method proposed by Arhan *et al.* was used, the percentage of the colon actually present in each segment relative to that determined theoretically was 99.6% for the right colon segment, 92.2% for the left colon segment, and 92.2% for the sigmoid/rectal segment. However, in cases in which the transverse colon descended partially from the fifth lumbar vertebra, the percentage occupied by the sigmoid colon + rectum decreased to 57.2%. We applied a new large bowel segmentation method especially for patients with ptosis, by devising a line joining the lateral side of the right lesser pelvis and the lower ends of both sacroiliac joints.

**Key words:** large bowel, segmentation, plain abdominal radiograph, classification method, primary care

Plain abdominal radiographic examinations in primary care clinics are an important aspect of medical care. According to a report by the Ministry of Health, Labour and Welfare, Japanese medical institutions number approximately 100,000 clinics (and about 9,000 hospitals)\*\*. Plain abdominal radiography examinations account for about 50% of examinations that can be done in a clinic, while computed tomogra-

phy (CT) and magnetic resonance imaging (MRI) examinations account for no more than 5%. In addition, plain abdominal radiography is a cheaper examination than CT or MRI. \*\*See the general condition of medical facilities investigation and hospital reports of the Ministry of Health, Labour and Welfare, at Japanese medical institutions (<http://www.go.jp/toukei/saikin/hw/iryosd/05/kekka1-3.htm> accessed December/2010). Plain abdominal radiography is the most basic diagnostic imaging method for the abdominal region. It facilitates the diagnosis of conditions such as ileus, gastrointestinal perforation, and ure-

Received December 9, 2010; accepted December 8, 2011.

\*Corresponding author. Phone: +81-86-235-7265; Fax: +81-86-235-7269  
E-mail: kim-sawa@mvf.biglobe.ne.jp (K. Sawa)

terolithiasis, by identifying the presence of signs of abdominal gas, calcification, *etc.* Arhan *et al.* proposed a method of dividing the large bowel into 3 segments on the basis of the osseous landmarks recognizable on a plain abdominal radiograph and measured the colorectal transit time using radiopaque markers. Their method is widely used for diagnosing the causes of constipation and irritable bowel syndrome [1–3].

However, our literature search revealed no studies evaluating the usefulness of the method reported by Arhan *et al.*, the usefulness of other methods of colorectal bowel segmentation on plain abdominal radiographs, or numerical analysis of the percentage of the large bowel distribution in X-ray-based segments. To our knowledge, there are no reports on methods suitable for ptotic patients.

Barium enema is one of the diagnostic methods used for visualizing the large bowel on a plain abdominal radiograph, but the distribution of the large bowel on barium enema images cannot be regarded as physiological because the images are obtained under the influences of scopolamine and massive air inflow.

To resolve these shortcomings of the conventional method, we recently analyzed plain abdominal radiographs obtained after oral barium intake as well as gastric fluoroscopy images to delineate large bowel segments on the images and analyze the percentage of large bowel distributions on plain abdominal radiographs. This study aimed to estimate large bowel segmentation on a plain abdominal radiograph, in order to show how fractionation of such segmentation could be a part of primary care, as a way of compensating for deficiency of the method reported by Arhan *et al.*

## Materials and Methods

Gastric fluoroscopy was performed at a hospital affiliated with Okayama University, by using Barytgen-Deluxe (Fushimi Pharmaceutical Co., Ltd., Kagawa, Japan) as the contrast material and X-ray film (Konica Minolta Holdings, Inc., Tokyo, Japan). We studied 43 healthy volunteers (29 men and 14 women; ages 32–58 years) who were free of gastroenterological abnormalities based on gastric fluoroscopy and free of other abnormalities by hematological tests, abdominal ultrasonography, and abdominal CT. All subjects gave informed consent and were enrolled in this study. Two h after gastric fluoroscopy, the

subjects underwent abdominal radiography in the supine position. A region of interest (ROI) was defined on the obtained radiographs. The upper end of the first lumbar vertebra (1) and the roof of the acetabula of both hip joints (2) served as the upper and lower horizontal axes, respectively. The lateral side of the right iliac wing (3) and the lateral side of the left iliac wing (4) served as the vertical axes. The area between horizontal axes (1) and (2) and that between vertical axes (3) and (4) were divided into 20 equal parts. To cover the entire large bowel, the upper and lower ends of the ROI were extended by 5 equal portions in both the upper and lower directions. In this way, a total of 600 zones were established (coordinate axes: A through T and 1 through 30) (Fig. 1).

Four physicians divided the ROI area representing the large bowel into the ascending colon, transverse

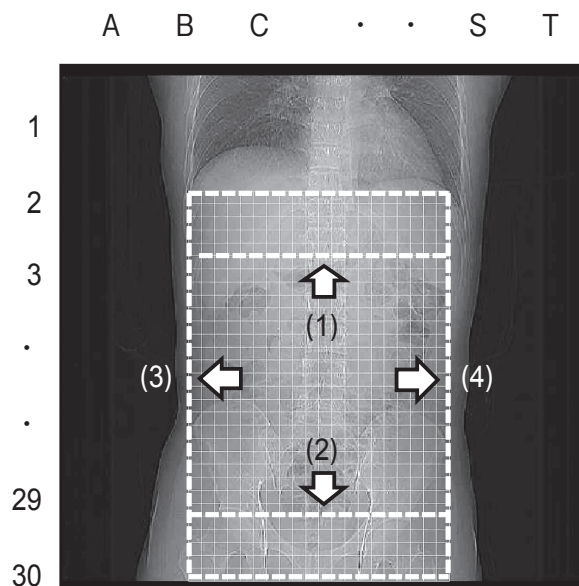


Fig. 1 The region of interest (ROI) was delineated on the obtained plain abdominal radiograph. The upper end of the first lumbar vertebra (1) and the roofs of the acetabulae of both hip joints (2) served as the upper and lower horizontal axes, respectively. The lateral side of the right wing (3) and the lateral side of the left iliac wing (4) served as the vertical axes. The area between horizontal axes (1) and (2) and that between vertical axes (3) and (4) were divided into 20 equal parts. To cover the entire large bowel, the upper and lower ends of the ROI were extended by 5 equal parts in both the upper and lower directions. In this way, a total of 600 zones were established (coordinate axes: A through T and 1 through 30).

colon, descending colon, and sigmoid colon + rectum. The hepatic flexure bordered the ascending colon and transverse colon, the splenic flexure bordered the transverse colon and descending colon, and the pelvic brim was designated as the boundary between the descending and sigmoid colon. The percentage of the barium distribution in each segment was numerically calculated, and the percentage of ROI occupancy was evaluated for each of the 4 large bowel segments, using Vector Works 10. (Nemetschek Vectorworks Inc., Columbia, MD, USA.) We divided the individuals into 2 groups: ptosis-free, in which the entire transverse colon was located above the fifth lumbar vertebra, and ptotic, in which the transverse colon was partially located below the fifth lumbar vertebra. We compared the percentages of the colon actually present in the sigmoid/rectal segment in the ptotic and ptosis-free groups.

To overcome difficulty in cases with ptosis of the transverse colon, we modified the method proposed by

Arhan *et al.* Instead of defining the segments by the line joining the fifth lumbar vertebra and the right and left subpelvic openings, we defined 3 segments by the line joining the lateral side of the right lesser pelvis and the lower ends of both sacroiliac joints.

### Results

Each segment of the large bowel is graphically represented in Fig. 2 and the distribution is provided below.

Ascending colon: Distributed between coordinates A through H and 1 through 25. The distribution percentage was 28.2% (169/600) of the ROI, with the percent ROI occupancy being 27.9%.

Transverse colon: Distributed between coordinates B through T and 1 through 25. The distribution percentage was 60.2% (361/600) of the ROI, with the percent ROI occupancy being 39.2%. Thus, there was a discrepancy between the distribution percentage and

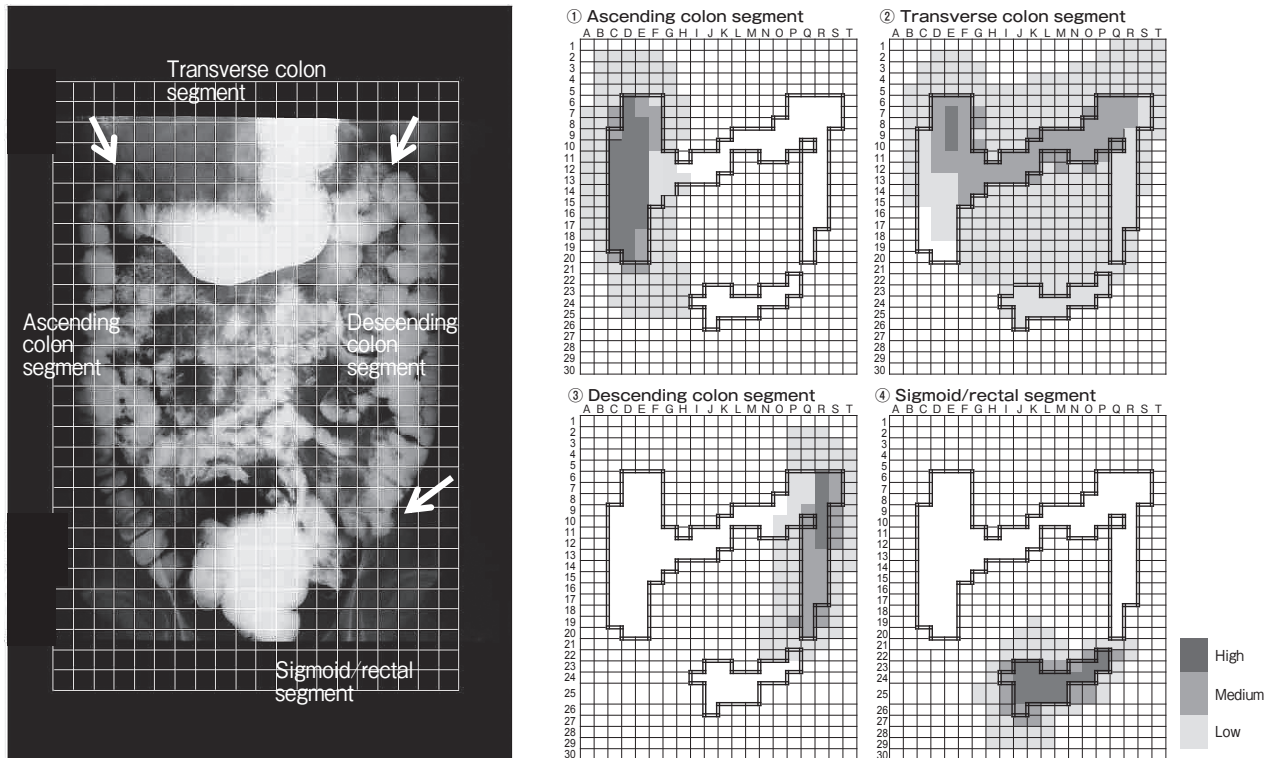


Fig. 2 Abdominal radiography with barium and percentage of distribution and percentage occupancy by 4 segments within the region of interest (ROI). Background: Distribution graph for mean ( $\mu$ ) + SD ( $1\sigma$ ) or more. Percentage of distribution and percentage occupancy by 4 segments shown in each figure. ①Ascending colon segment ②Transverse colon segment ③Descending colon segment ④ Sigmoid/rectal segment.

percent occupancy.

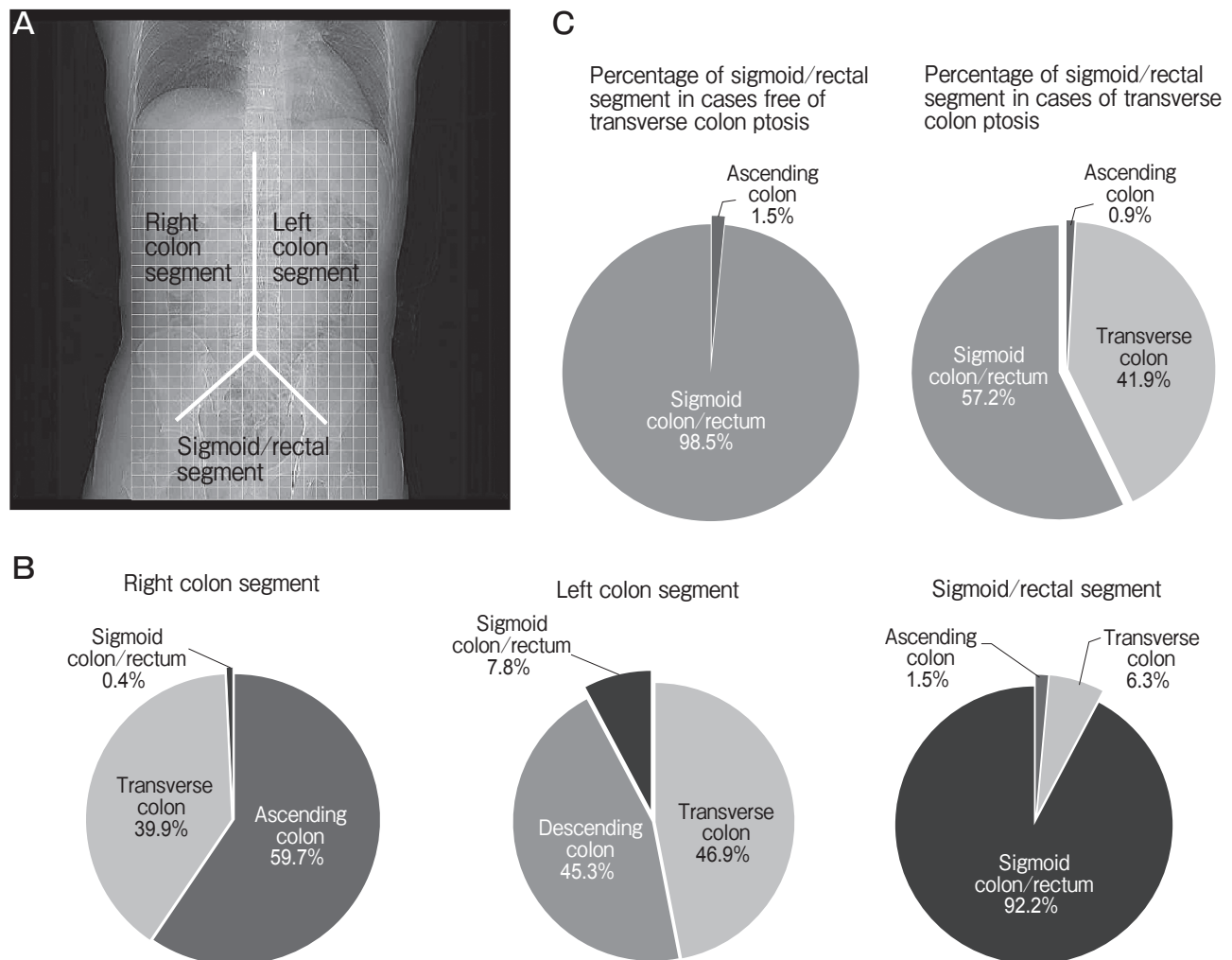
**Descending colon:** Distribution between coordinates N through T and 1 through 22. The distribution percentage was 18.0% (108/600) of the ROI, with the percent ROI occupancy being 17.1%.

**Sigmoid colon + rectum:** Distribution between coordinates G through R and 19 through 29. The distribution percentage was 12.5% (75/600) of the ROI, with the percent ROI occupancy being 15.8%.

For the entire large bowel, the distribution per-

centage was 76.7% of the ROI, including 55% duplications. Duplications were mostly attributable to the transverse colon. *Comparison with the classification method reported by Arhan et al.* (Fig. 3A)

The classification method reported by Arhan *et al.* involves dividing the large bowel into 3 segments: the right colon segment included the ascending colon (59.7%), transverse colon (39.9%) and sigmoid colon + rectum (0.4%); the left colon segment comprised of the transverse colon (46.9%), descending colon (45.3%)



**Fig. 3** With the conventional method proposed by Arhan *et al.* (A), the percentages of the colon actually present in each segment were 99.6% for the right colon segment, 92.2% for the left colon segment, and 92.2% for the sigmoid/rectal segment (B). The overall percentage of the sigmoid colon/rectum in the sigmoid/rectal segment was 92.2%. However, when individuals were divided into 2 groups (the ptosis-free group, where in the transverse colon was completely located above the fifth lumbar vertebra and the ptotic group, wherein the transverse colon was partially located below the fifth lumbar vertebra), the percentage of sigmoid colon + rectum in the sigmoid/rectal segment was 98.5% in the ptosis-free group, but was only 57.2% in the ptotic group (C).

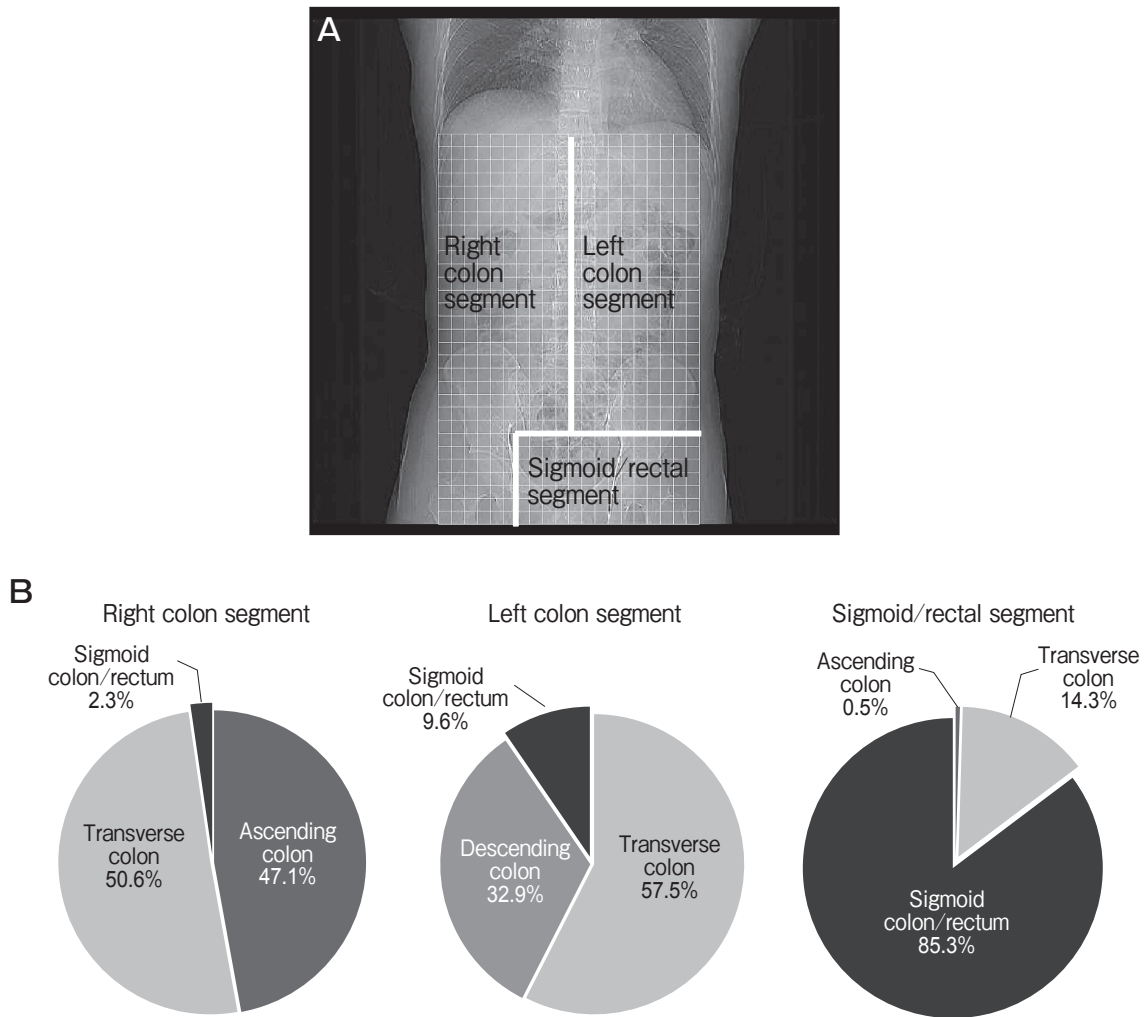
and sigmoid colon + rectum (7.8%); and the sigmoid/rectal segment, composed of the sigmoid colon + rectum (92.2%), transverse colon (6.3%) and ascending colon (1.5%).

The percentages of the actual colon in each segment relative to those determined theoretically were 99.6% for the right colon segment, 92.2% for the left colon segment and 92.2% for the sigmoid/rectal segment (Fig. 3B).

The locations of the transverse colon, however, varied greatly among individuals. The individuals were divided into 2 groups: ptosis-free (29 men, 10 women),

in which the transverse colon was completely located above the fifth lumbar vertebra, and ptotic (4 women) in which the transverse colon was partially located below the fifth lumbar vertebra; the percentage of sigmoid colon + rectum occupancy in the sigmoid/rectal segment was 98.5% in the ptosis-free group, but only 57.2% in the ptosis group (Fig. 3C).

With this new method (Fig. 4A), the percentage of distribution was 97.7% for the right colon segment, 90.4% for the left colon segment, and 85.3% for the sigmoid/rectal segment (Fig. 4B).



**Fig. 4** In the new method of classification, the 3 segments (right colon segment, left colon segment, and sigmoid/rectal segment) are defined by the line joining the spinous process and the lower end of both sacroiliac joints and the line vertical to the lateral side of the right lesser pelvis (A). With this method, the percentage of colonic distribution was 97.7% for the right colon segment, 90.4% for the left colon segment, and 85.3% for the sigmoid/rectal segment (B).

## Discussion

Diagnostic imaging has advanced remarkably in the past few years. Gamma-scintigraphy, MRI and wireless capsule endoscopy now allow accurate diagnosis of the causes of constipation and irritable bowel syndrome [4-6]. However, these new modalities require specialized devices, are expensive, and are indicated in a limited number of conditions, making it difficult to utilize them for primary care. Plain abdominal radiography is much more feasible in primary care facilities.

We also described a method for large bowel segmentation on plain abdominal radiographs, which can be applied even in cases with ptosis of the transverse colon. Bouchoucha and Thomas *et al.* conducted error analyses and reported that large bowel segmentation using conventional methods may be erroneous in the presence of ptosis of the transverse colon [7]. Pomerri *et al.* demonstrated that use of the barium tracetechnique markedly resolves the anatomical problems related to the colon [8]. The new method reported in this study facilitates overcoming the problems of conventional methods, without requiring corrective calculation or barium doses. In the present study, ptosis of the transverse colon was detected only in women; it was found in 9% of all subjects (28.6% of women). According to the report by Saunders *et al.*, in 29% of the Western population and 10% of the Oriental population, the transverse colon extends to the level of the lesser pelvis [9]. Sadahiro *et al.* performed barium enema studies and reported total colon length and transverse colon length to be greater in women than in men and that the entire colon length tended to increase with age, regardless of the individual's gender [10]. The prevalence of ptosis of the transverse colon varies according to race, gender and age, but overall, it is a common condition. In Arhan's study, subjects were healthy and nearly all ptosis-free in the transverse colon, such that their classification method is useful in patients free of transverse colon ptosis, but the obtained results may be erroneous if applied to cases with ptosis of the transverse colon extending to the level of the lesser pelvis.

In conclusion, the classification method proposed

by Arhan *et al.* is useful for patients without ptosis of the transverse colon, but the results may be erroneous if applied to cases with ptosis of the transverse colon extending to the level of the lesser pelvis. Thus, the method proposed by Arhan *et al.* may not always be suitable for evaluating patients with chronic constipation and abdominal pain, which can be caused by transverse colon ptosis. To overcome this difficulty in cases with ptosis of the transverse colon, we modified the method proposed by Arhan *et al.* This new method appears to be useful for evaluating cases with ptosis of the transverse colon.

**Acknowledgments.** We thank Mr. Teruo Akiyama for his excellent technical abdominal photography.

## References

1. Arhan P, Devroede G, Jehannin B, Lanza M, Faverdin C, Dornic C, Persoz B, Tetreault L, Perey B and Pellerin D: Segmental colonic transit time. *Dis Colon Rectum* (1981) 24: 625-629.
2. Bouchoucha M, Devroede G, Arhan P, Strom B, Weber J, Cugnenc PH, Denis P and Barbier JP: What is the meaning of colorectal transit time measurement? *Dis Colon Rectum* (1992) 35: 773-782.
3. Metcalf AM, Phillips SF, Zinsmeister AR, MacCarty RL, Beart RW and Wolff BG: Simplified assessment of segmental colonic transit. *Gastroenterology* (1987) 92: 40-47.
4. Buhmann S, Kirchoff C, Ladurner R, Mussack T, Reiser MF and Lienemann A: Assessment of colonic transit time using MRI: a feasibility study. *Eur Radiol* (2007) 17: 669-674.
5. Hasler WL, Saad RJ, Rao SS, Wilding GE, Parkman HP, Koch KL, McCallum RW, Kuo B, Sarosiek I, Sitrin MD, Semler JR and Chey WD: Heightened colon motor activity measured by a wireless capsule in patients with constipation: relation to colon transit and IBS. *Am J Physiol Gastrointest Liver Physiol* (2009) 297: G1107-1114.
6. Lundin E, Graf W, Garske U, Nilsson S, Maripuu E and Karlborn U: Segmental colonic transit studies: comparison of a radiological and a scintigraphic method. *Colorectal Dis* (2007) 9: 344-351.
7. Bouchoucha M and Thomas SR: Error analysis of classic colonic transit time estimates. *Am J Physiol Gastrointest Liver Physiol* (2000) 279: G520-G527.
8. Pomerri F, Frigo AC, Grigoletto F, Dodi G and Muzzio PC: Error count of radiopaque markers in colonic segmental transit time study. *AJR Am J Roentgenol* (2007) 189: W56-W59.
9. Saunders BP, Masaki T, Sawada T, Halligan S, Phillips RK, Muto T and Williams CB: A preoperative comparison of Western and oriental colonic anatomy and mesenteric attachments. *Int J Colorectal Dis* (1995) 10: 216-221.
10. Sadahiro S, Ohmura T, Yamada Y, Saito T and Taki Y: Analysis of length and surface area of each segment of the large intestine according to age, sex and physique. *Surg Radiol Anat* (1992) 14: 251-257.