

## Clinical Accuracy of Three-Dimensional Fluoroscopy (IsoC-3D)-Assisted Upper Thoracic Pedicle Screw Insertion

Yoshihisa Sugimoto\*

Yasuo Ito<sup>†</sup>

Masao Tomioka<sup>‡</sup>

Tetsuya Shimokawa\*\*

Yasuyuki Shiozaki<sup>††</sup>

Tetsuro Mazaki<sup>‡‡</sup>

Masato Tanaka<sup>§</sup>

\*Department of Orthopaedic Surgery, Kobe Red Cross Hospital,

<sup>†</sup>Department of Orthopaedic Surgery, Kobe Red Cross Hospital,

<sup>‡</sup>Department of Orthopaedic Surgery, Hyogo Emergency Medical Center,

\*\*Department of Orthopaedic Surgery, Kobe Red Cross Hospital,

<sup>††</sup>Department of Orthopaedic Surgery, Kobe Red Cross Hospital,

<sup>‡‡</sup>Department of Orthopaedic Surgery, Kobe Red Cross Hospital,

<sup>§</sup>Department of Orthopaedic Surgery, Okayama University Hospital,

# Clinical Accuracy of Three-Dimensional Fluoroscopy (IsoC-3D)-Assisted Upper Thoracic Pedicle Screw Insertion

Yoshihisa Sugimoto, Yasuo Ito, Masao Tomioka, Tetsuya Shimokawa, Yasuyuki Shiozaki, Tetsuro Mazaki, and Masato Tanaka

## Abstract

Correct screw placement is especially difficult in the upper thoracic vertebrae. At the cervicothoracic junction (C7-T2), problems can arise because of the narrowness of the pedicle and the difficulty of using a lateral image intensifier there. Other upper thoracic vertebrae (T3-6) pose a problem for screw insertion also because of the narrower pedicle. We inserted 154 pedicle screws into 78 vertebrae (C7 to T6) in 38 patients. Screws were placed using intraoperative data acquisition by an isocentric C-arm fluoroscope (Siremobile Iso-C3D) and computer navigation. Out of 90 pedicle screws inserted into 45 vertebrae between C7 and T2, 87 of the 90 (96.7%) screws were classified as grade 1 (no perforation). Of 64 pedicle screws inserted into 33 vertebrae between T3 and T6, 61 of 64 (95.3%) screws were classified as grade 1. In this study, we reduced pedicle screw misplacement at the level of the C7 and upper thoracic (T1-6) vertebrae using the three-dimensional fluoroscopy navigation system.

**KEYWORDS:** Iso-C3D, three-dimensional fluoroscopy, navigation, upper thoracic, pedicle screw

## Original Article

**Clinical Accuracy of Three-Dimensional Fluoroscopy (IsoC-3D)-Assisted Upper Thoracic Pedicle Screw Insertion**Yoshihisa Sugimoto<sup>a\*</sup>, Yasuo Ito<sup>a</sup>, Masao Tomioka<sup>b</sup>, Tetsuya Shimokawa<sup>a</sup>,  
Yasuyuki Shiozaki<sup>a</sup>, Tetsuro Mazaki<sup>a</sup>, and Masato Tanaka<sup>c</sup><sup>a</sup>Department of Orthopaedic Surgery, Kobe Red Cross Hospital, Kobe 651-0073, Japan,<sup>b</sup>Department of Orthopaedic Surgery, Hyogo Emergency Medical Center, Kobe 651-0073, Japan, and<sup>c</sup>Department of Orthopaedic Surgery, Okayama University Hospital, Okayama 700-8558, Japan

Correct screw placement is especially difficult in the upper thoracic vertebrae. At the cervicothoracic junction (C7-T2), problems can arise because of the narrowness of the pedicle and the difficulty of using a lateral image intensifier there. Other upper thoracic vertebrae (T3-6) pose a problem for screw insertion also because of the narrower pedicle. We inserted 154 pedicle screws into 78 vertebrae (C7 to T6) in 38 patients. Screws were placed using intraoperative data acquisition by an isocentric C-arm fluoroscope (Siremobil Iso-C3D) and computer navigation. Out of 90 pedicle screws inserted into 45 vertebrae between C7 and T2, 87 of the 90 (96.7%) screws were classified as grade 1 (no perforation). Of 64 pedicle screws inserted into 33 vertebrae between T3 and T6, 61 of 64 (95.3%) screws were classified as grade 1. In this study, we reduced pedicle screw misplacement at the level of the C7 and upper thoracic (T1-6) vertebrae using the three-dimensional fluoroscopy navigation system.

**Key words:** Iso-C3D, three-dimensional fluoroscopy, navigation, upper thoracic, pedicle screw

**A**lthough pedicle screw fixation is an essential part of reconstruction in spinal disorders, screw misplacement can result in neurologic and vascular injury [1]. Correct screw placement is especially difficult in the upper thoracic vertebrae. For instance, at the cervicothoracic junction (C7-T2), problems can arise because of the narrowness of the pedicle, difficulty in determining the entry point using an AP image intensifier, and obstruction by the patient's shoulder when a lateral image intensifier is used [2-4]. Other upper thoracic vertebrae (T3-6) pose a problem for screw insertion due to the narrowness of the pedicle rather than the lack of visibility

with a lateral intensifier [5, 6].

Recently, several authors reported on the usefulness of a spinal navigation system that improves accuracy of pedicle screw insertion [7-11]. Navigation systems have made it possible for intraoperative, three-dimensional assessment (axial, sagittal, and coronal) of the pedicle screw trajectory. Conventional CT-based image guidance and three-dimensional fluoroscopy are major navigation systems for spinal instrumentation. Three-dimensional fluoroscopy is the newest navigation system and is superior to conventional CT-based image guidance because anatomic registration is not required [8, 12, 13]. Furthermore, this system is able to update the intraoperative real-time position of the spine.

In this study, we retrospectively assessed the accuracy of C7 and upper thoracic (T1-6) pedicle

Received January 18, 2010; accepted February 17, 2010.

\*Corresponding author. Phone: +81-86-223-9727; Fax: +81-86-235-7273  
E-mail: yoshihisa64@hotmail.com (Y. Sugimoto)

screw insertions that were placed using the three-dimensional fluoroscopy navigation system.

### Materials and Methods

We inserted 154 pedicle screws into 78 vertebrae (C7 to T6) in 38 consecutive patients consisting of 21 men and 17 women with an average age at examination of 56 years (range, 21 to 87 years old). Twenty-three patients had spinal trauma, 12 had degenerative disorders, and 3 presented with metastatic bone tumors. Screws that were inserted into vertebrae with burst fractures or pedicle fractures were excluded, as were vertebrae with tumor invasion. None of the patients had scoliosis with vertebral rotation.

We grouped the 78 vertebrae into those at the cervicothoracic junction (C7, T1, and T2) or other upper thoracic vertebrae (Th3-6). Ninety pedicle screws were placed into vertebrae between C7 and T2, while 64 screws were placed between T3-T6.

The technique used for all pedicle screws was as follows: The screws were placed using intraoperative data acquisition by an isocentric C-arm fluoroscope (Siremobil Iso-C3D, Siemens Medical, Erlangen, Germany) and computer navigation by the Stealth Station (Medtronic Surgical Navigation Technologies, Louisville, CO, USA). All patients were placed on a radiolucent carbon table using a carbon frame and a headholder, and a dynamic reference arc (DRA) was attached to the spinous process of interest. The C-arm then acquired multiple successive images as it performed an automated 190° rotation around the patient (12cm field of view). During this period, the surgeon can step away from the operating field to reduce radiation exposure. After image acquisition, the fluoroscope workstation generated axial, sagittal, and coronal reconstructions of the image anatomy.

Screw trajectory planning proceeded in a manner similar to that used for standard CT-based image guidance.

Proper screw size was determined by intra-operative navigation data. When we measured pedicle width using conventional axial CT during preoperative planning, we sometimes assessed the width as though it was smaller than the actual width because an axial CT slice can shift above or below the actual center of the pedicle. We can choose the accurate pedicle screw diameter and trajectory by a voluntary slice using 3D data. We usually registered 2 to 3 vertebra levels at the same time. If there was intervertebral instability, we registered each vertebra separately across the unstable disc level. The pedicle screw diameter we used was 4.0mm or more.

Postoperative fine cut (1.25mm) CT was obtained in all patients. All instrumented levels were scanned with the CT gantry segmentally oriented parallel to the pedicle screws. Screw placement was graded on CT as follows: grade 1, screw threads cut just into the cortex; grade 2, screw perforation of the cortex by up to 2mm; and grade 3, screw perforation of the cortex by > 2mm [8]. Screw perforation in the direction of the disc was assessed using reconstructed sagittal CT. Postoperative CT was assessed by 2 orthopaedic surgeons and one radiologist.

For the purpose of statistical analysis, Fisher's exact tests were calculated, and a value of  $p < 0.05$  was regarded as significant.

### Results

Out of 90 pedicle screws inserted into 45 vertebrae between C7 and T2, 87 of the 90 (96.7%) screws were classified as grade 1 (no pedicle perforation), and 3 of 90 (3.3%) screws as grade 2 (Table 1).

Table 1 Pedicle screw placement which was graded on CT

	cervicothoracic junction			other upper thoracic			
	C7	Th1	Th2	Th3	Th4	Th5	Th6
grade 1	41	30	16	19	17	15	10
grade 2	3	-	-	1	2	-	-
grade 3	-	-	-	-	-	-	-
disc perforation	-	-	-	-	-	-	-
total	44	30	16	20	19	15	10

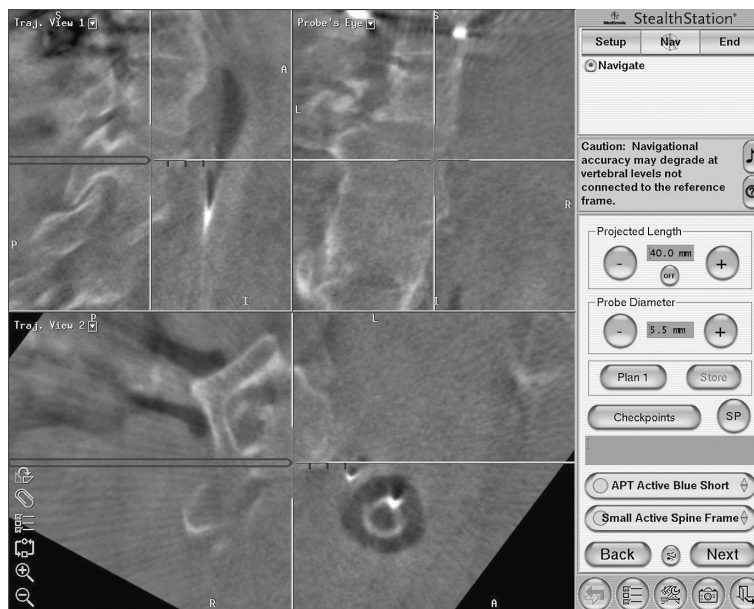


Fig. 1 Th1 pedicle screw insertion using three-dimensional fluoroscopy (IsoC-3D). We can correctly determine the entry point and screw direction using three-dimensional fluoroscopy and the navigation system.

Clinically, significant screw deviation in the present study was considered grade 3, but this occurred in none of the placements.

Of 64 pedicle screws inserted into 33 vertebrae between T3 and T6, 61 of 64 (95.3%) were classified as grade 1, and 3 of 64 (4.7%) as grade 2. No screws were classified as grade 3. The perforation rate between the cervicothoracic junction (C7, T1, and T2) and other upper thoracic vertebrae (T3–6) was not significantly different.

In reconstructed sagittal CT, none of the 154 pedicle screws perforated in the direction of the disc. Complications such as neurological injury, vascular injury, and dural tearing were not observed in any patients.

## Discussion

Several authors have reported that navigation systems reduced pedicle screw perforation compared with a freehand technique [7–9]. Kotani *et al.* reported that the pedicle screw perforation rate in scoliosis patients was 11% in a freehand technique group and 1.8% in a CT-based navigation system group [9]. Rajasekaran *et al.* assessed 478 thoracic pedicle screws inserted in patients with spinal defor-

mity and found 54 (23%) pedicle breaches in the non-navigation group, compared to only 5 (2%) in the navigation group (Iso-C3D) [8].

Correct screw placement can be especially difficult in the upper thoracic vertebrae. Guzey *et al.* reported that 20.3% of 113 upper and middle thoracic pedicle screws were misplaced (27.4% for T2 to T5 screws, and 14.5% for T6 to T8 screws) using fluoroscopy [14].

At the cervicothoracic junction (C7–T2), problems can arise during screw insertion because of the narrowness of the pedicles, difficulty in determining the entry point using an AP image intensifier, and obstruction by the patient's shoulder when a lateral image intensifier is used [2–4]. However, we determined the entry point and screw direction using three-dimensional fluoroscopy (Fig. 1). Out of 90 pedicle screws inserted into 45 vertebrae between C7 and T2, 87 (96.7%) were classified as grade 1 (no pedicle perforation), and 3 (3.3%) were classified as grade 2.

For the other upper thoracic vertebrae (T3–6), insertion difficulties arise because of the narrowness of the pedicles rather than the lack of visibility when a lateral intensifier is used. McLain *et al.* reported that 25% of T1 pedicles, 17% of T2 pedicles, 42% of T3 pedicles, 61% of T4 pedicles, 67% of T5

pedicles, and 75% of T6 pedicles were narrower than 5.5mm [5]. In this study, 61 of 64 (95.3%) screws placed into T2 to T6 vertebrae were classified as grade 1. The perforation rate between the cervico-thoracic junction (C7, T1, and T2) and other upper thoracic vertebrae (T3–6) was not significantly different. Clinically, we considered grade 3 a significant screw deviation in the present study, but none of the screw placements fell into this grade. Rajasekaran *et al.* reported that 16 of 72 (22%) pedicle screws placed at the level of the upper thoracic spine using fluoroscopy perforated, while 0 of 86 (0%) screws perforated using three-dimensional fluoroscopy (IsoC3D) [8]. Our data support their results.

Three-dimensional fluoroscopy offers a number of advantages over traditional CT-based navigation systems. First, anatomic registration is not required. As a result, three-dimensional fluoroscopy has the potential for percutaneous screw placement [12]. Second, the images used for navigation are obtained with the patient in the desired surgical position. This can be particularly important in cases of spinal instability where the preoperative CT data may not reflect the actual intraoperative anatomic relationships, potentially leading to navigation error. Finally, the isocentric C-arm can be used to generate an intraoperative post-procedural CT image to verify the accuracy of screw placement.

There are some disadvantages of the IsoC-3D navigation system. Image quality is sometimes suboptimal, especially in obese or osteopenic patients. An additional concern is cost, which would include 3D fluoroscopy, the navigation system, a carbon bed, and a carbon Mayfield headholder. Because of these limitations, there is no comparison group in this study, such as a free-hand insertion group.

## References

1. Neo M, Sakamoto T, Fujibayashi S and Nakamura T: The clinical risk of vertebral artery injury from cervical pedicle screws inserted in degenerative vertebrae. *Spine* (2005) 30: 2800–2805.
2. Schizas C, Theumann N and Kosmopoulos V: Inserting pedicle screws in the upper thoracic spine without the use of fluoroscopy or image guidance. Is it safe? *Eur Spine J* (2007) 16: 625–629.
3. Kuntz C 4th, Maher PC, Levine NB and Kurokawa R: Prospective evaluation of thoracic pedicle screw placement using fluoroscopic imaging. *J Spinal Disord Tech* (2004) 17: 206–214.
4. Hart RA, Hansen BL, Shea M, Hsu F and Anderson GJ: Pedicle screw placement in the thoracic spine: a comparison of image-guided and manual techniques in cadavers. *Spine* (2005) 30: E326–331.
5. McLain RF, Ferrara L and Kabins M: Pedicle morphometry in the upper thoracic spine: limits to safe screw placement in older patients. *Spine* (2002) 27: 2467–2471.
6. Zeiller SC, Lee J, Lim M and Vaccaro AR: Posterior thoracic segmental pedicle screw instrumentation: evolving methods of safe and effective placement. *Neurol India* (2005) 53: 458–465.
7. Laine T, Lund T, Ylikoski M, Lohikoski J and Schlenzka D: Accuracy of pedicle screw insertion with and without computer assistance: a randomised controlled clinical study in 100 consecutive patients. *Eur Spine J* (2000) 9: 235–240.
8. Rajasekaran S, Vidyadhara S, Ramesh P and Shetty AP: Randomized clinical study to compare the accuracy of navigated and non-navigated thoracic pedicle screws in deformity correction surgeries. *Spine* (2007) 32: E56–64.
9. Kotani Y, Abumi K, Ito M, Takahata M, Sudo H, Ohshima S and Minami A: Accuracy analysis of pedicle screw placement in posterior scoliosis surgery: comparison between conventional fluoroscopic and computer-assisted technique. *Spine* (2007) 32: 1543–1550.
10. Ito Y, Sugimoto Y, Tomioka M, Hasegawa Y, Nakago K and Yagata Y: Clinical accuracy of 3D fluoroscopy-assisted cervical pedicle screw insertion. *J Neurosurg Spine* (2008) 9: 450–453.
11. Ito Y, Kai N, Hasegawa Y, Nakago K, Toda K and Yagata Y: Clinical study for registration-free 3D-navigation with isocentric 3D C-arm. *Seikei geka* (2005) 56: 1495–1500 (in Japanese).
12. Holly LT and Foley KT: Percutaneous placement of posterior cervical screws using three-dimensional fluoroscopy. *Spine* (2006) 31: 536–540.
13. Euler E, Heining S, Riquarts C and Mutschler W: C-arm-based three-dimensional navigation: a preliminary feasibility study. *Comput Aided Surg* (2003) 8: 35–41.
14. Guzey FK, Emel E, Hakan Seyithanoglu M, Serdar Bas N, Ozkan N, Sel B, Aycan A and Alatas I: Accuracy of pedicle screw placement for upper and middle thoracic pathologies without coronal plane spinal deformity using conventional methods. *J Spinal Disord Tech* (2006) 19: 436–441.