

## Poorly Differentiated Adenocarcinoma with Signet-ring Cell Carcinoma of the Extrahepatic Bile Duct in a 42-year-old Japanese Female: A Case Report

Sho Ogata\*      Akifumi Kimura<sup>†</sup>      Kazuo Hatsuse<sup>‡</sup>  
Junji Yamamoto\*\*      Hideyuki Shimazaki<sup>††</sup>  
Kuniaki Nakanishi<sup>‡‡</sup>      Toshiaki Kawai<sup>§</sup>

\*Department of Pathology and Laboratory Medicine, National Defense Medical College,

<sup>†</sup>Department of Surgery III, National Defense Medical College,

<sup>‡</sup>Department of Surgery III, National Defense Medical College,

\*\*Department of Surgery III, National Defense Medical College,

<sup>††</sup>Department of Laboratory Medicine, National Defense Medical College,

<sup>‡‡</sup>Department of Pathology and Laboratory Medicine, National Defense Medical College,

<sup>§</sup>Department of Pathology and Laboratory Medicine, National Defense Medical College,

# Poorly Differentiated Adenocarcinoma with Signet-ring Cell Carcinoma of the Extrahepatic Bile Duct in a 42-year-old Japanese Female: A Case Report

Sho Ogata, Akifumi Kimura, Kazuo Hatsuse, Junji Yamamoto, Hideyuki Shimazaki, Kuniaki Nakanishi, and Toshiaki Kawai

## Abstract

Poorly differentiated adenocarcinoma without papilla or tubule formation of the extrahepatic bile duct is rare. Here we present a case (a 42-year-old Japanese woman) without either pancreatobiliary maljunction or liver disease. The patient had obstructive jaundice. Imaging studies revealed a bile duct tumor obstructing the common bile duct and invading the surrounding tissues. Pathologic examination revealed a dense periductal growth of poorly differentiated adenocarcinoma containing signet-ring cells, but without papilla or tubule formation in the extrahepatic bile duct. The tumor cells directly invaded the pancreatic parenchyma and the portal vein. In the extrahepatic bile duct, poorly differentiated adenocarcinoma may be established as a distinct clinicopathologic entity if the tumors are characterized by: 1) the absence of papilla or tubule formation, 2) Asian preponderance, 3) occurrence at a younger age than is usual for patients with biliary cancers, and 4) an aggressive mural invasiveness.

**KEYWORDS:** adenocarcinoma, bile duct cancer, signet-ring cell carcinoma

*Case Report***Poorly Differentiated Adenocarcinoma with Signet-ring Cell Carcinoma of the Extrahepatic Bile Duct in a 42-year-old Japanese Female: A Case Report**Sho Ogata<sup>a\*</sup>, Akifumi Kimura<sup>b</sup>, Kazuo Hatsuse<sup>b</sup>, Junji Yamamoto<sup>b</sup>,  
Hideyuki Shimazaki<sup>c</sup>, Kuniaki Nakanishi<sup>a</sup>, and Toshiaki Kawai<sup>a</sup>*Departments of <sup>a</sup>Pathology and Laboratory Medicine, <sup>b</sup>Surgery III, and  
<sup>c</sup>Laboratory Medicine, National Defense Medical College, Tokorozawa, Saitama 359-8513, Japan*

Poorly differentiated adenocarcinoma without papilla or tubule formation of the extrahepatic bile duct is rare. Here we present a case (a 42-year-old Japanese woman) without either pancreatobiliary maljunction or liver disease. The patient had obstructive jaundice. Imaging studies revealed a bile duct tumor obstructing the common bile duct and invading the surrounding tissues. Pathologic examination revealed a dense periductal growth of poorly differentiated adenocarcinoma containing signet-ring cells, but without papilla or tubule formation in the extrahepatic bile duct. The tumor cells directly invaded the pancreatic parenchyma and the portal vein. In the extrahepatic bile duct, poorly differentiated adenocarcinoma may be established as a distinct clinicopathologic entity if the tumors are characterized by: 1) the absence of papilla or tubule formation, 2) Asian preponderance, 3) occurrence at a younger age than is usual for patients with biliary cancers, and 4) an aggressive mural invasiveness.

**Key words:** adenocarcinoma, bile duct cancer, signet-ring cell carcinoma

**A**lthough a poorly differentiated carcinoma component is usually admixed with better-differentiated carcinomas in cancers of the extrahepatic bile duct, a poorly differentiated carcinoma without papilla or tubule formation in this duct is considered to be rare. Here we present a poorly differentiated biliary cancer in a 42-year-old Japanese female and discuss its clinicopathological character.

**Case Report**

A 42-year-old Japanese woman was transferred to

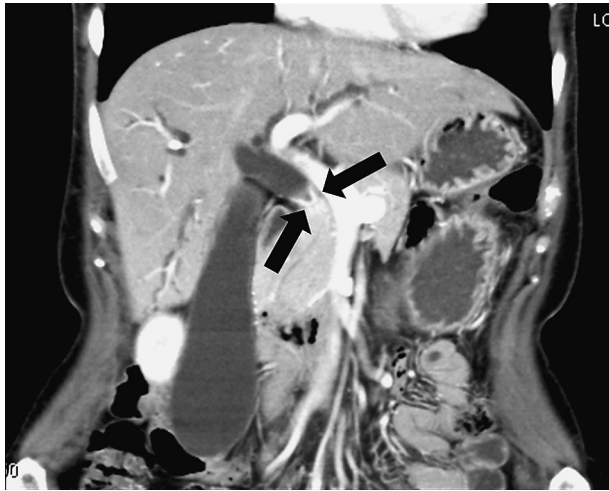our hospital because of suspected common bile duct (CBD) malignancy. She had no specifically relevant past or family history or history of travel to areas where liver flukes are prevalent. On physical examination, she had slight icterus and was positive for Courvoisier's sign. Abdominal computed tomography demonstrated a bile duct stricture in the CBD accompanied by a proximal dilatation of the bile tract (Fig. 1). There was no evidence of pancreatobiliary maljunction, gallstones, or liver disease. Serum laboratory data revealed slight elevations in the values for transaminases, total- and direct-bilirubins, carbohydrate antigen 19-9, and Span-1. A preoperative diagnosis of bile duct cancer was established.

During the operation, a hard consistency was felt in the pancreas head and along the bile duct. Neither

Received May 26, 2009; accepted August 11, 2009.


\*Corresponding author. Phone: +81-4-2995-1505; Fax: +81-4-2996-5192  
E-mail: [sogata@ndmc.ac.jp](mailto:sogata@ndmc.ac.jp) (S. Ogata)

distant metastasis nor other primary cancers were found. A subtotal stomach-preserving pancreaticoduodenectomy was performed. The wall of the portal vein (PV) was adhering too tightly to be detached from the tumor, and so it was resected concomitantly.



**Fig. 1** Abdominal computed tomography demonstrated a contrast-enhanced bile duct tumor (arrows) accompanied by a proximal dilatation of the biliary tract.

On gross inspection of the resected specimen, the CBD had a thick whitish wall and a narrow lumen (Fig. 2A). Histology of the tumor revealed solid and infiltrative growth by round tumor cells displaying distinct nucleoli and intracytoplasmic lumina or intracytoplasmic mucus deposition (Figs. 2B, C). No papilla or tubule formation by cancer cells was evident. Most cancer cells were immunoreactive for anti-cytokeratin (CK) 7 and anti-p53 antibodies, but not for anti-CK 20 antibody. Periductal cancer cells extended along the bile duct beyond the level of the junction between the common hepatic duct (CHD) and the cholecystic duct (CD), but did not involve the ampulla. Cancer cells had also invaded the pancreatic parenchyma and the PV wall, and had metastasized to the lymph nodes attached to the nearby common hepatic artery. The final diagnosis was poorly differentiated adenocarcinoma of the extrahepatic bile duct (UICC T4N1M0). The patient was not discharged until the 36<sup>th</sup> post-operative day because of a concomitant pancreatic fistula and delayed gastric emptying. However, no signs of recurrence were observed during a 6-month follow-up at the outpatient clinic.



**Fig. 2** **A**, On the cut surface of the pancreas head (a, most proximal; g, most distal), a whitish tumor of the CBD (interrupted circles) extended to the CHD and the CD, and also to the PV (bars). Scale divisions represent 5mm each. **B**, **C**, Histologically, the cancer involved CBD, and most cancer cells displayed signet-ring features or had intracytoplasmic lumina (hematoxylin-eosin; scale bars indicate 1mm in **B** and 20µm in **C**).

## Discussion

To date, only one bile duct and 15 ampullary cases featuring poorly differentiated carcinoma without papilla or tubule formation have been reported in the English-language literature [1-5]. Of these: 1) Half the cases were from Asian countries; 2) some of the ampullary cases were in relatively young patients [1-3]; and 3) 2 cases, including a CBD cancer case, exhibited rapid cancer growth [2, 4]. The present case was also from an Asian country, and the cancer was found in the early part of the 5th decade of life, younger than is usual for patients with biliary cancers. Moreover, the cancer cells had penetrated into the PV wall, a growth pattern that is relatively uncommon among biliary cancers. Thus, we suggest that in the extrahepatic bile duct, poorly differentiated adenocarcinoma may be established as a distinct clinicopathologic entity if the tumors are characterized by: 1) histologically, an absence of papilla or tubule formation; 2) an Asian preponderance; 3) occurrence at a younger age than is usual for patients with biliary cancers; and 4) an aggressive mural invasiveness.

In the present case, immunohistochemistry for CK 7/20 and p53 was performed. Although the CK 7/20 immunoprofiles were not reported for the 16 purely poorly differentiated biliary and ampullary cancers described previously, this CK 7-positive and CK 20-negative pattern is similar to that found in the pancreatobiliary type of conventional biliary cancers [6]. In contrast, intestinal-type ampullary cancers are usually positive for CK 20, and are associated with a better prognosis than pancreatobiliary-type ampullary cancers [7]. In the present case, despite the CK 7-positive and CK 20-negative pattern, no signs of recurrence were observed during a 6-month follow-up. We detected immunoreactivity for p53 in most of the cancer cells. Usually in biliary cancer, p53 expression is suppressed in intraepithelial precancerous lesions, but is upregulated in invasive cancers [8]. Thus, p53 expression may be helpful for making a differential diagnosis between these lesions. However, we found no intraepithelial precancerous lesions.

It is well known that the only curative treatment

for the present cancer is surgical resection. To date, there are no evidence-based chemotherapy regimens either for the treatment of unresectable cancers or as postoperative adjuvant therapy [9]. Therefore, we have simply followed up the patient, and she has fortunately remained well, without signs of tumor recurrence.

In conclusion, we have presented here a rare bile duct cancer consisting solely of poorly differentiated adenocarcinoma, and we have discussed its characteristics, including those that may make it possible to establish poorly differentiated adenocarcinoma in the extrahepatic bile duct as a distinct clinicopathologic entity.

## References

1. Purohit RC, Kant K, Bhargave N, Kothari N and Purohit V: Signet ring cell carcinoma of ampulla of Vater in a young adult. *Indian J Gastroenterol* (2005) 24: 222-223.
2. Nabeshima S, Kishihara Y, Nabeshima A, Yamaga S, Kinjo M, Kashiwagi S and Hayashi J: Poorly differentiated adenocarcinoma with signet-ring cells of the Vater's ampulla, without jaundice but with disseminated carcinomatosis. *Fukuoka Igaku Zasshi* (2003) 94: 235-240.
3. Gao JM, Tang SS, Fu W and Fan R: Signet-ring cell carcinoma of ampulla of Vater: contrast-enhanced ultrasound findings. *World J Gastroenterol* (2009) 15: 888-891.
4. Hiraki M, Yakushiji H, Hashiguchi K, Harada S, Okada K, Goto Y, Ikeda H, Mori D, Tokonaga O and Miyazaki K: Signet ring cell carcinoma of the lower bile duct with rapid growth: report of a case. *Hepatogastroenterology* (2007) 54: 1922-1924.
5. Akatsu T, Aiura K, Takahashi S, Kameyama K, Kitajima M and Kitagawa Y: Signet-ring cell carcinoma of the ampulla of Vater: report of a case. *Surg Today* (2007) 37: 1110-1114.
6. Duval JV, Savas L and Banner BF: Expression of cytokeratin 7 and 20 in carcinomas of the extrahepatic biliary tract, pancreas, and gallbladder. *Arch Pathol Lab Med* (2000) 124: 1196-1200.
7. Roh YH, Kim YH, Lee HW, Kim SJ, Roh MS, Jeon JS and Jung GJ: The clinicopathologic and immunohistochemical characteristics of ampulla of Vater carcinoma: the intestinal type is associated with a better prognosis. *Hepatogastroenterology* (2007) 54: 1641-1644.
8. Nakanishi Y, Zen Y, Kondo S, Ito T, Inatsu K and Nakanuma Y: Expression of cell cycle-related molecules in biliary premalignant lesion: biliary intraepithelial neoplasia and biliary intraductal papillary neoplasm. *Hum Pathol* (2008) 39: 1153-1161.
9. Anderson C and Kim R: Adjuvant therapy for resected extrahepatic cholangiocarcinoma: a review of the literature and future directions. *Cancer Treat Rev* (2009) 35: 322-327.