

Acta Medica Okayama

Volume 57, Issue 3

2003

Article 8

JUNE 2003

Absence of scalenus anterior muscle.

Shinichiro Murakami* Kanji Horiuchi[†] Chugo Yamamoto[‡]

Aiji Ohtsuka** Takuro Murakami^{††}

*Okayama University,

[†]Okayama University,

[‡]Okayama University,

**Okayama University,

^{††}Okayama University,

Absence of scalenus anterior muscle.*

Shinichiro Murakami, Kanji Horiuchi, Chugo Yamamoto, Aiji Ohtsuka, and
Takuro Murakami

Abstract

A rare anomaly of the scalenus muscles is described. In this case, the right scalenus anterior muscle was absent. As a substitute for this muscle, some aberrant muscle slips arose from the lower vertebrae and descended in front of the ventral rami of the lower cervical nerves. These aberrant slips then ran between the ventral rami of the eighth cervical and first thoracic nerves, and were fused with the right scalenus medius muscle. Thus, the subclavian artery and vein ran in front of the aberrant slips, together with the ventral ramus of the first thoracic nerve. The aberrant muscle slips issued 2 accessory bundles. One bundle ran between the ventral rami of the fourth and fifth cervical nerves and was fused with the scalenus medius muscle; the other bundle ran between the ventral rami of the fifth and sixth cervical nerves and was fused with the scalenus medius muscle.

KEYWORDS: scalenus anterior muscle, scalenus medius muscle, ventral rami of the lower cervical nerves, ventral ramus of the first thoracic nerve, subclavian artery and vein

Case Report

Absence of Scalenus Anterior Muscle

Shinichiro Murakami, Kanji Horiuchi, Chugo Yamamoto, Aiji Ohtsuka,
and Takuro Murakami*

*Department of Human Morphology, Okayama University Graduate School of Medicine
and Dentistry, Okayama 700-8558, Japan*

A rare anomaly of the scalenus muscles is described. In this case, the right scalenus anterior muscle was absent. As a substitute for this muscle, some aberrant muscle slips arose from the lower vertebrae and descended in front of the ventral rami of the lower cervical nerves. These aberrant slips then ran between the ventral rami of the eighth cervical and first thoracic nerves, and were fused with the right scalenus medius muscle. Thus, the subclavian artery and vein ran in front of the aberrant slips, together with the ventral ramus of the first thoracic nerve. The aberrant muscle slips issued 2 accessory bundles. One bundle ran between the ventral rami of the fourth and fifth cervical nerves and was fused with the scalenus medius muscle; the other bundle ran between the ventral rami of the fifth and sixth cervical nerves and was fused with the scalenus medius muscle.

Key words : scalenus anterior muscle, scalenus medius muscle, ventral rami of the lower cervical nerves, ventral ramus of the first thoracic nerve, subclavian artery and vein

The scalenus anterior muscle arises from the anterior tubercles of the transverse processes of the lower cervical vertebrae, and is inserted into the scalenus tubercle of the first rib [1, 2]. This paper describes a rare case of anomaly in which the scalenus anterior muscle is absent.

Case Report

This anomaly of the scalenus muscle was found in an 89-year-old Japanese female who died of heart failure. She had no history of surgical procedures. She was fixed conventionally by arterial perfusion with 10% formalin and subsequently dehydrated with 50% ethanol. Dissections were performed in a 1999 clinical anatomy course

for medical students at Okayama University Medical School.

The right scalenus anterior muscle was absent. As a substitute for this muscle, some aberrant muscle slips arose from the anterior tubercles of the transverse processes of the fourth to seventh vertebrae, and descended in front of the ventral rami of the fifth to eighth cervical nerves (Figs. 1, 2). The aberrant muscle slips then ran between the ventral rami of the eighth cervical nerve and the first thoracic nerve, and were fused into the right scalenus medius muscle (Figs. 1, 2). Thus, the ventral ramus of the first thoracic nerve, together with the right subclavian artery and vein, ran in front of the aberrant muscle slips just above the first rib (Figs. 1, 2).

The aberrant muscle slips issued 2 accessory bundles. One bundle ran between the ventral rami of the fourth and fifth cervical nerves and was fused with the right scalenus medius muscle; the other bundle was fused with this muscle between the ventral rami of the fifth and sixth

Received December 17, 2002; accepted February 10, 2003.

*Corresponding author, Phone: +81-86-235-7088; Fax: +81-86-235-7095
E-mail: em2kai@md.okayama-u.ac.jp (T. Murakami)

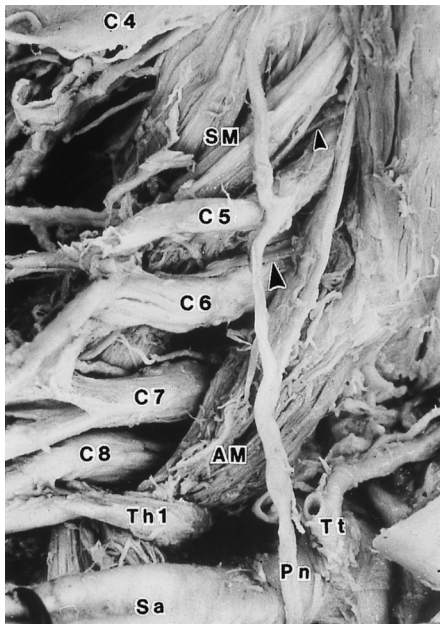


Fig. 1 Ventral view of the dissected right neck. Note that the scalenus anterior muscle is absent. As a substitute for this muscle, some aberrant muscle slips (AM) descend in front of the ventral rami of the lower (the fifth to eighth) cervical nerves (C5-C8), and run between the ventral rami of the eighth cervical nerve (C8) and the first thoracic nerve (Th1) to be fused into the scalenus medius muscle (SM) or to be inserted in the first rib. One of these aberrant muscle slips issues 2 accessory bundles, one of which is fused into the scalenus medius muscle over the ventral ramus of the fifth cervical nerve (C5) (small arrowhead), the other between the ventral rami of the fifth and sixth cervical nerve (C5 and C6) (large arrowhead). C4, ventral ramus of the fourth cervical nerve; C7, ventral ramus of the seventh cervical nerve; Sa, subclavian artery; Tt, thyrocervical trunk; Pn, phrenic nerve.

cervical nerves (Figs. 1, 2).

No anomalies were found in the origins and insertions of the scalenus medius muscle. Neither marked anomalies in the formations of the brachial plexus nor marked anomalies in the branching and running patterns of the subclavian artery and vein were found.

Discussion

This paper describes a rare case of anomaly in which the right scalenus anterior muscle was absent. To our knowledge, there have been few previous case reports of such an anomaly or of the absence of the scalenus anterior muscle [2, 3]. In our previous case of absence of the scalenus anterior muscle, 2 aberrant muscle slips arose

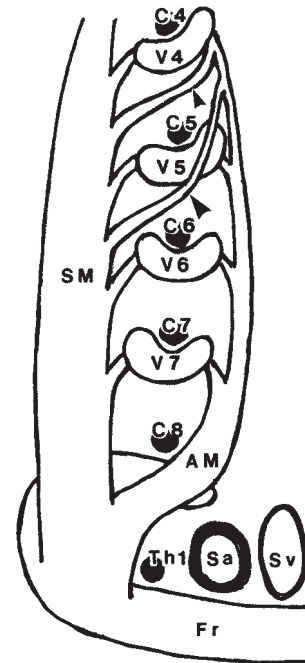


Fig. 2 Schematic diagram of aberrant muscle slips (AM) as observed in Fig. 1 (lateral view). Fr, first rib; Sv, subclavian vein; V4-V7, the fourth-seventh vertebrae. For other abbreviations, see the legend for Fig. 1.

from the sixth and seventh vertebrae and descended between the ventral rami of the seventh and eighth cervical nerves to be fused into the scalenus medius muscle [4]. Thus, in our previous case, the ventral rami of the seventh and eighth cervical nerves ran in front of the scalenus medius muscle, together with the ventral ramus of the first thoracic nerve, the subclavian artery, and the subclavian vein.

There have been many reports of anomalous muscle slips between the scalenus anterior and the scalenus medius muscles [3, 4]. These anomalous slips sometimes arose from the scalenus medius muscle and ran into the scalenus anterior muscle [4]. Such anomalous slips can also arise from the scalenus anterior muscle and run into the scalenus medius muscle [4]. The aberrant muscle slips observed in the present case may be well developed remnants of such anomalous slips between the scalenus medius and scalenus anterior muscles.

The proximity of the scalenus anterior muscle to the brachial plexus and the subclavian artery and vein can give rise to compression syndromes [5]. Aberrant slips or bundles, including those observed in the present paper,

may also compress the brachial plexus or the ventral rami of the lower cervical nerves, causing similar compression syndromes [4, 5].

References

1. Eisler P: Mm. Scaleni; in Bardeleben Handbuch der Anatomie des Menschen. 2, II, 1 (Die Muskeln des Stammes), Eisler P ed, Gustav Fischer, Jena (1912) pp 298-310 (in German).
2. Salmons S: Lateral vertebral muscles; in Gray's Anatomy, Bannister LH, Berry MM, Collins P, Dyson M, Dussek JE and Ferguson MWJ eds, Churchill Livingstone, New York (1995) pp 808-809.
3. Forster A: Beitrag zur Morphologie des Scalenusystems und des sterno-costalis. Zschr Morph Anthropol (1916) 19: 271-352 (in German).
4. Yamamoto C: Typological interrelationships of the human scalenus muscles, brachial plexus and subclavian artery. Okayama Igakkai Zasshi (JOMA) (1992) 104: 205-209 (in Japanese with English abstract).
5. Katirji B and Hardy RW Jr: Classic neurogenic thoracic outlet syndrome in a competitive swimmer: A true scalenus anticus syndrome. Muscle Nerve (1995) 18: 229-233.