

Acta Medica Okayama

Volume 28, Issue 4

1974

Article 4

AUGUST 1974

Studies on the factors inducing metastasis of breast cancer to lymph node. I. Lymph flow in the thoracic wall

Schinichiro Matsuo*

*Okayama University,

Copyright ©1999 OKAYAMA UNIVERSITY MEDICAL SCHOOL. All rights reserved.

Studies on the factors inducing metastasis of breast cancer to lymph node. I. Lymph flow in the thoracic wall*

Schinichiro Matsuo

Abstract

The mode of lymph flow from the breast to the regional lymph node was studied using $^{113}\text{SbAu}$ colloid, to ascertain the concept of lymph node of Groups 1, 2, and 3. Lymph flow through the internal mammary nodes was found to be abundant. Especially so when $^{113}\text{SbAu}$ colloid was injected into the lower half of the breast, there was observed more abundant flow than that to axillary lymph nodes. Therefore, it was concluded that regardless of the site of occupation of a tumor, internal mammary nodes should be considered to be of Group 1. Lymph flow through the subclavian nodes proved to be always less than that to the axillary nodes or internal mammary nodes. The rate of the lymph flow appearance on the scintigram was about 20%. Whether the subclavian nodes should be classified as Group 1 or 2 should be further studied. The rate of supraclavicular node visualization was below 3%. Therefore, the supraclavicular nodes should be considered to be Group 2. When these results are applied to the current rule of handling of breast cancer, discrepancy occurs in the Stage number and R-number.

*PMID: 4140676 [PubMed - indexed for MEDLINE] Copyright ©OKAYAMA UNIVERSITY MEDICAL SCHOOL

**STUDIES ON THE FACTORS INDUCING METASTASIS
OF BREAST CANCER TO LYMPH NODE
I. LYMPH FLOW IN THE THORACIC WALL**

Schinichiro MATSUO

*Department of Surgery, Okayama University Medical School,
Okayama, Japan (Director: Prof. S. Tanaka)*

Received for publication, January 7, 1974

Abstract: The mode of lymph flow from the breast to the regional lymph node was studied using ^{198}Au colloid, to ascertain the concept of lymph node of Groups 1, 2, and 3. Lymph flow through the internal mammary nodes was found to be abundant. Especially so when ^{198}Au colloid was injected into the lower half of the breast, there was observed more abundant flow than that to axillary lymph nodes. Therefore, it was concluded that regardless of the site of occupation of a tumor, internal mammary nodes should be considered to be of Group 1. Lymph flow through the subclavian nodes proved to be always less than that to the axillary nodes or internal mammary nodes. The rate of the lymph flow appearance on the scintigram was about 20%. Whether the subclavian nodes should be classified as Group 1 or 2 should be further studied. The rate of supraclavicular node visualization was below 3%. Therefore, the supraclavicular nodes should be considered to be Group 2. When these results are applied to the current rule of handling of breast cancer, discrepancy occurs in the Stage number and R-number.

The lymphatic system of the breasts indicates the pathway of the progress of breast cancer which is extremely important. Studies on metastasis of breast cancer to the lymph nodes have been carried out by many investigators in the past and numerous reports are available on the lymphatic system. Japanese Research Society for Mammary Cancer has classified the regional lymph nodes of the breast into three groups, 1, 2, and 3 (1). Mode of lymph nodes metastasis, however, is variable individually and various modes of recurrence are also noted.

Assessment of lymph flow within the thoracic wall is quite important in order to clarify the mode of metastasis of breast cancer to the lymph node and to decide the methods of radical operation and prognosis. For the dynamic observation of lymph flow within the thoracic wall with reference to mammary gland, radioisotopes were used to measure the radioactivity taken up to the lymph nodes from the body surface. Scintigram was further used to classify the regional lymph nodes.

MATERIALS AND METHODS

Materials: This study is based on 108 mammary glands taken from 66 patients with diseases of the breast operated at the Department of Surgery, Okayama University Medical School. Mastopathia was found in 56, and fibroadenoma in ten. Age ranged from 24 to 67 years old. The radioisotopes used in the present study were as follows.

1) ^{198}Au Aurcoscan (Dainabot), ^{198}Au colloid, 500 $\mu\text{Ci}/\text{ml}$, specific radioactivity above 4 mCi/ml. Total concentration 0.125 mg/ml, average particle 25 $\mu\mu$., preservative, etc. glucose 50 mg/ml, sodium citrate 0.2 mg/ml, gelatin 4 mg/ml, benzylalcohol 0.9%.

2) Hyaluronidase (Mochida), containing 500 units hyaluronidase.

3) Instruments and conditions for measurement.

(1) cpm Measurement in lymph nodes, set at a level above 100 KeV by the integral method. Scintillator: 2' ϕ \times 2' probe ND-451 type; collimeter: 1' straight collimeter; scaler: Aloka Highspeed scaler RDS-1; directed vertically to the skin and measurement carried out at one cm from the skin.

(2) Scintillation scan on thoracic wall. Toshiba Universal scintillation scanner; scintillator: 5' ϕ \times 2' - x_2 RDA-107-4 85 hole, F = 10 cm; superior and inferior confrontation system.

^{198}Au colloid, 150 μCi and 200 units of hyaluronidase, are made into one ml solution to be injected into the mammary gland. Injection was carried out at sites A, B, C, D and E of the mammary gland, as shown in the Fig. 1. At six

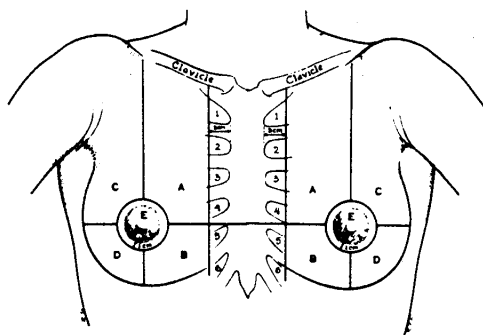


Fig. 1. Injection Sites of ^{198}Au on Breast (A. B. C. D. E.)
A. B. C. D. E.: point of introducing of ^{198}Au

hours after injection, scintillator was placed over the site of injection, the lateral axillary lymph node group (1a), the medial axillary lymph node group (1b), the subclavian lymph node group (2), and the internal mammary node group (3), [this is further subdivided into the second intercostal space (3 upper) and fourth intercostal space (3 inferior)] for measurement of cpm. At 48 hours after the injection, scintillation scan of the thoracic wall was carried out. Apart from these, ^{198}Au colloid was injected into the mammary gland in cases of breast cancer. After radical operation, slices were prepared with the

muscle and fascia of the inherent portion of the pectoralis major muscle and pectoralis minor muscle, as well as the removed lymph nodes. Staining with gold (2) and iron (3) was carried out to study the mode of transport of gold particles to the lymph nodes and the mode of uptake into the lymph nodes.

Decision on the time of scintillation scan on the thoracic wall and cpm measurement in the lymph nodes: As a preliminary experiment, cpm in each lymph node was measured 1, 2, 6, 24 and 48 hours after injection of ^{198}Au colloid into the mammary gland. The changes are as shown in Fig. 2. In each lymph node,

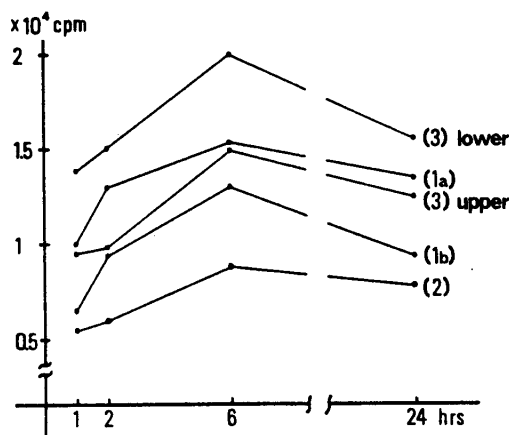


Fig. 2. Changes of CPM in each lymph node group

- (3) lower: fourth internal mammary
- (1a): brachial lymph node
- (3) upper: second internal mammary
- (1b): central lymph node
- (2): subclavian lymph node

cpm showed the maximum value six hours for the diffusion of ^{198}Au colloid injected into the mammary gland. Consequently, the lymph flow was compared between each site after six hours (relative error of the measured cpm, less than 0.01). Thoracic wall was tested by scintillation scan 6, 24, 48 and 72 hours after injection of ^{198}Au colloid. After 48 hours, the most distinct pictures of lymph nodes were noted. Scintigram for lymph nodes was, therefore, obtained 48 hours later.

RESULTS

1) *Comparison of cpm six hours after injection of ^{198}Au colloid:* Regardless of the sites of injection A, B, C, D and E, the flow of ^{198}Au colloid may be classified into three types: the type where predominant flow is directed to the lateral or medial lymph nodes (type I); the type where approximately equal amount flows to the axillary lymph nodes and internal mammary nodes (type II); and the type where predominant flow is directed to the internal

mammary nodes (type III). The predominant flow is directed to the axillary lymph nodes from C, E and to the internal mammary nodes from B, D. From A, an equal flow to both appears to take place. From each of these sites, however, a considerable flow was noted to the internal mammary nodes. Cpm in the subclavian nodes was lower than in any other sites, without remarkable characteristics. (Table 1)

TABLE I LYMPH FLOW OF THORACIC WALL FROM MAMMARY GLAND

Type of Lymph Flow	A	B	C	D	E	total
I lateral or medial	7 (38.9)	4 (16.7)	11 (55.0)	6 (28.6)	19 (76.0)	47 (43.5)
II axillary & internal mammary	4 (22.2)	8 (33.3)	3 (15.0)	3 (14.3)	3 (12.0)	21 (19.5)
III internal mammary	7 (38.9)	12 (50.0)	6 (30.0)	12 (57.1)	3 (12.0)	40 (37.0)
total	18	24	20	21	25	108

() %

2) *Mutual relationship of cpm among different sites*: According to statistical formula, the presence or the absence of mutual correlation was studied on 1a and 1b, 1a and 2, 1a and 3, 1b and 2, 1b and 3, and 2 and 3. Significant correlation ($P < 0.01$) was noted between 1a and 1b, but not in the other combinations.

3) *Findings of the scintigram*: Lymph nodes are described as spots of variable sizes on the scintigram. The pathway of lymph flow was found as a stream with width frequently having the number of striking points greater than that of lymph nodes. In all cases, the characteristic pattern of lymph nodes in group 1a, 1b and (3) was visualized. Picture of the subclavian lymph nodes (2) was visualized in 17 of 108, and the supraclavicular lymph nodes (4) in three. No lymph node behind the sternal manubrium (5d), however, was visualized. Picture of the left to right shunt was noted in two cases in the internal mammary node group. In both cases, right to left shunt was noted at the level of the first intercostal space. The lymphatic stream within the thoracic wall was classified according to the region in the scintigram, as shown in Fig. 3.

4) *Findings of gold staining of the tissue*: Numerous gold granules were noted between muscle and fat tissues, muscle and fascia, and in the lymphatic vessel between muscle fibers, and no homogeneous scattering was noted. Most of them appear to reach the lymph nodes via the tissue space or the lymphatic vessels. Within the lymph nodes, pictures of uptake by reticulum cell and

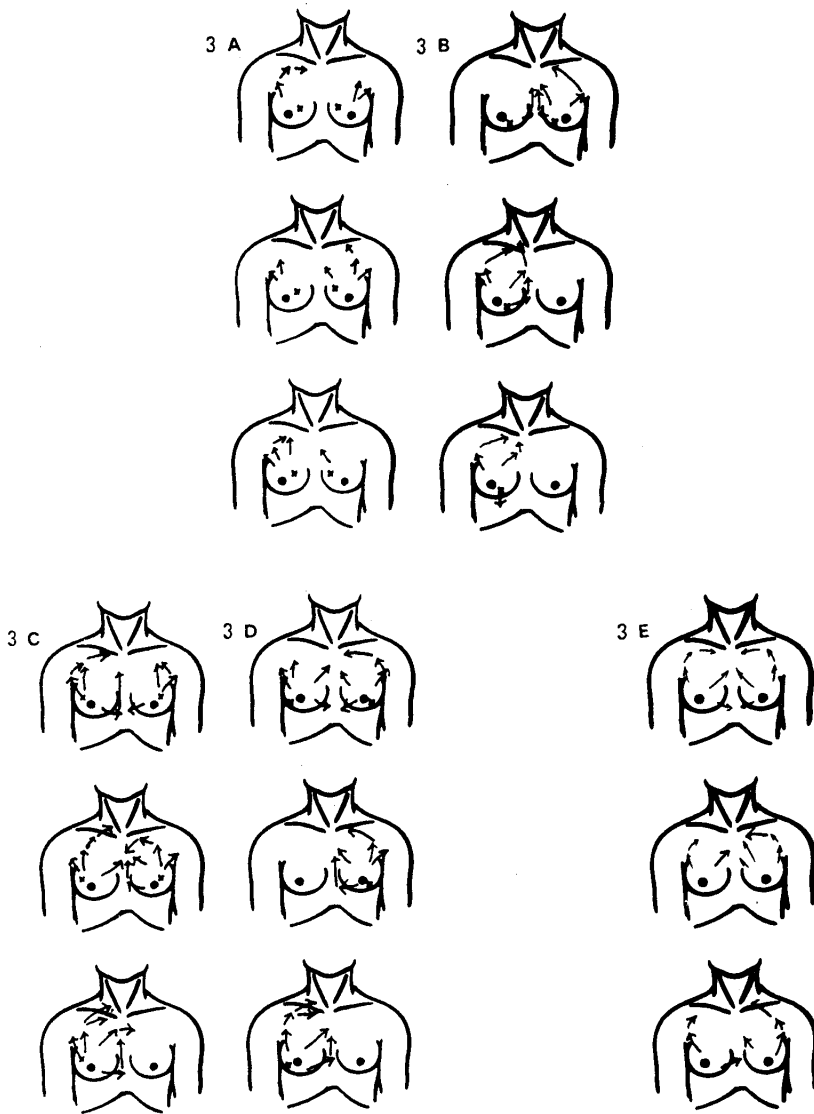


Fig. 3-A and B Diagrammatic representation of lymph flow as revealed by introducing ^{198}Au into A and B points

x : point of introducing of ^{198}Au Arrows : lymph flow

Fig. 3-C and D Diagrammatic representation of lymph flow as revealed by introducing ^{198}Au into C and D

x : point of introducing ^{198}Au Arrows : lymph flow

Fig. 3-E Diagrammatic representation of lymph flow as revealed by introducing ^{198}Au into E

x : point of introducing ^{198}Au Arrows : lymph flow

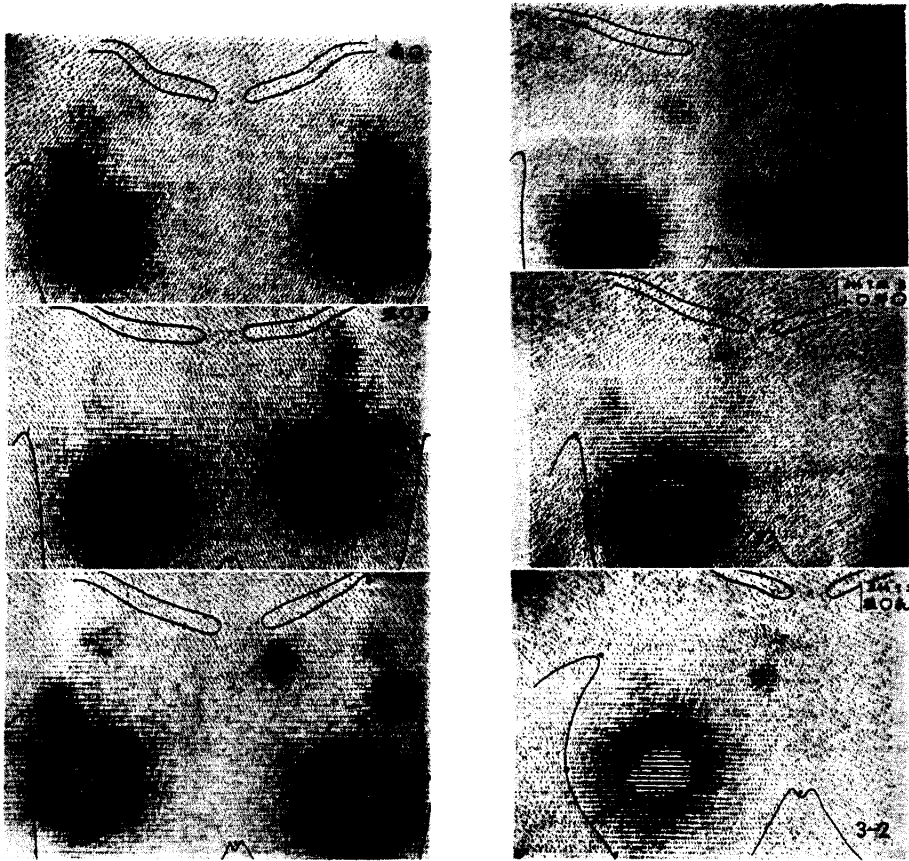


Fig. 3-1. Scintigram of the breast taken 48 hours after the introduction of ^{198}Au at the point of A

A: see Fig. 1

x: injection point, o: nipple

Fig. 3-2. Scintigram of the breast taken 48 hours after the introduction of ^{198}Au at the point of B

B: see Fig. 1

x: injection point, o: nipple

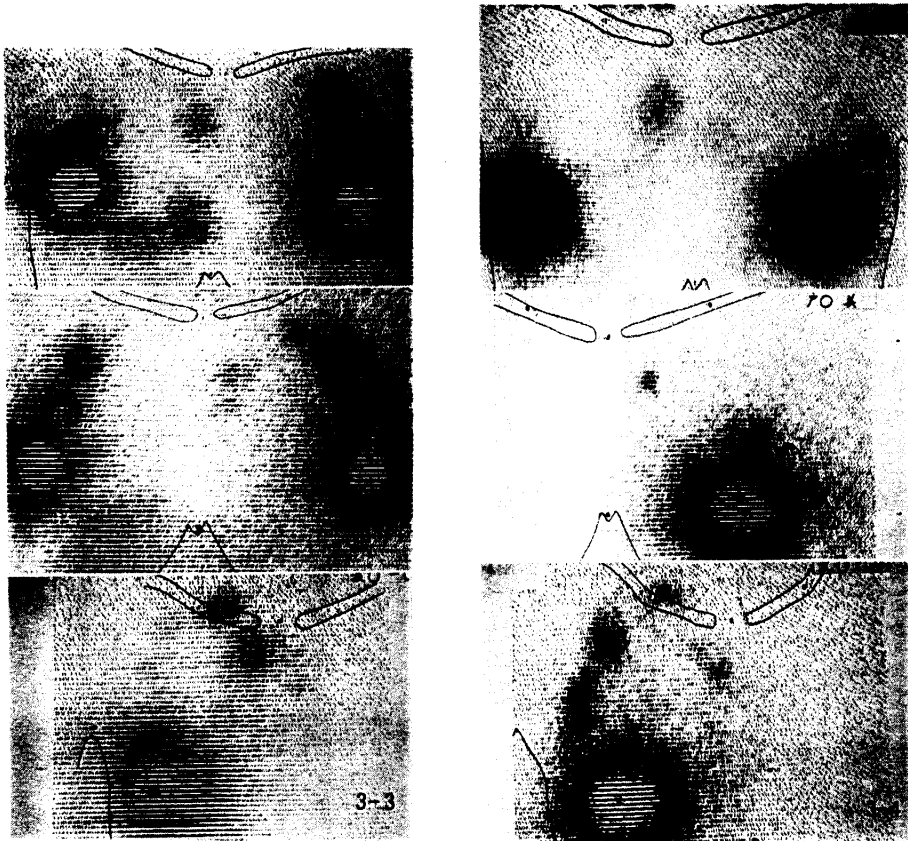


Fig. 3-3. Scintigram of the breast taken 48 hours after the introduction of ^{198}Au at the point of C

C: see Fig. 1

x: injection point, o: nipple

Fig. 3-4. Scintigram of the breast taken 48 hours after the introduction of ^{198}Au at the point of D

D: see Fig. 1

x: injection point, o: nipple

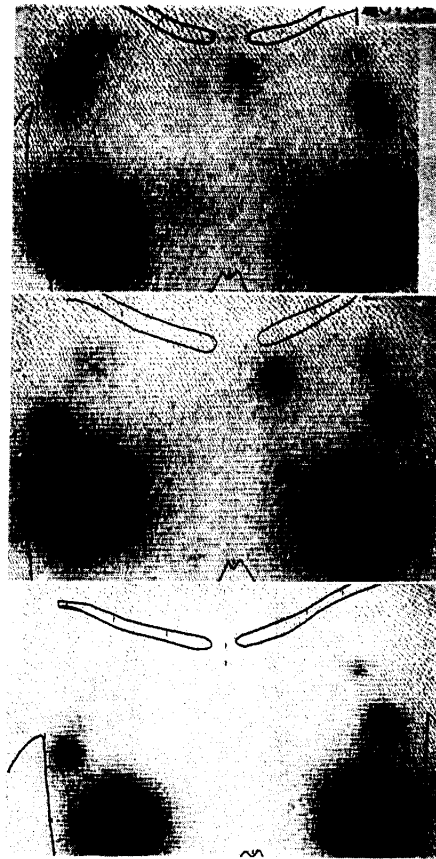

Fig. 3-5. Scintigram of the breast taken 48 hours after the introduction of ^{198}Au at the point of E

E: see Fig. 1

x: injection point, o: nipple

histiocytes were noted. Iron staining was carried out along with gold stain to rule out the presence of iron particles (Fig. 4).

DISCUSSIONS

As the numerous studies on metastasis of breast cancer to the lymph nodes in the past indicate, the anatomical pattern is quite complex and varies from case to case, without a unification as a whole. Such a complexity is due to the influence of stereostructure of the breast, changes due to mensual cycle,

Fig. 4. Gold staining of the tissues taken after ^{198}Au injection

1. Gold particles between muscle fiber bundles ($\times 40$)
2. Gold particles on the surface of muscle fiber ($\times 40$)
3. Gold particles in reticulum cells and histiocytes ($\times 40$)

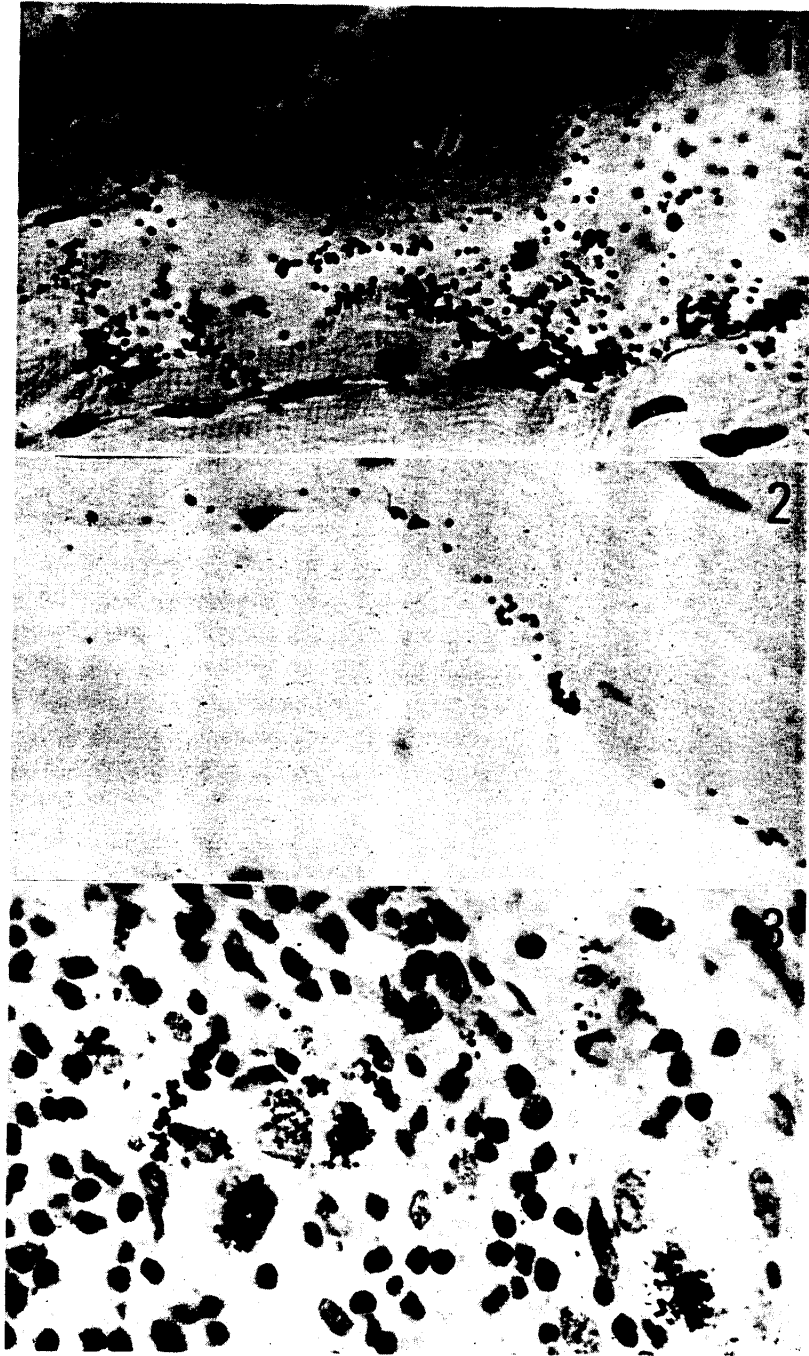

Fig. 4

pregnancy, lactation, and senile degeneration, and pathological changes due to mastitis, mastopathy and breast cancer. As to the lymph flow and distribution of lymph nodes related to mammary glands, detailed studies on autopsied cases by TURNER-WARWICK (4), HULTBORN (5), LARSEN (6), PUTTI (7), ARÃO (8), ROUVIERE (9), are available. With respect to the metastasis of breast cancer to lymph nodes, studies of HANDLEY (10), HAAGENSEN (11), and ANDREASSEN, (12) are available.

While these workers studied the mode of lymph node metastasis by patho-anatomical method, ^{198}Au colloid was used in the present study for dynamic studies on lymph flow through the chest wall. Uptake of ^{198}Au colloid into the lymph nodes was studied by scintigram. On the other hand, the ability of the lymph nodes to catch the cancer cell differs from the active phagocytosis of Au colloid, India ink, charcoal powder and bacteria, so that many of the cancer cells leave the glands after streaming through them. In the lymph nodes with abundant lymph flow, however, the frequency of embedding of cancer cells expected to increase.

In the general rules of Mammary Cancer Research Society, the lymph nodes related to the mammary glands are classified into groups 1, 2 and 3 for the medial and lateral side of the breast respectively (1), partially depending upon the frequency of carcinomatous metastasis and prognosis. HANDLEY (10), URBAN (13), ANDREASSEN (12), and others demonstrated metastasis to the internal mammary nodes along the internal mammary artery in a considerably high proportion, emphasizing that these belong to the lymph nodes of the first group.

In the present study, ^{198}Au was used to study the lymph flow. Even when the site of injection of ^{198}Au colloid was divided into the medial and lateral aspects of the breast, no remarkable difference was noted. Flow is mainly directed to the axillary lymph node group from the injection sites C and E, while more lymph flows to the internal mammary nodes from B and D. From A, the flow takes place equally to both. This was significantly different between the upper and lower halves of the breast, rather than between the medial and lateral halves. This is in agreement with the report of HAAGENSEN (11) on poorer prognosis of cancer of the lower half of the breast than the upper part. Regardless of the site of injection of ^{198}Au colloid, the flow into the internal mammary nodes was noted more frequently than into the axillary lymph node. Classification into group 1 or 2 by site whether the tumor is located in the medial or lateral region does not, therefore, appear reasonable.

Consequently, the internal mammary nodes should be considered to be the first group lymph nodes regardless of the site of occupation by the tumor.

As to the subclavian lymph nodes, cpm after six hours was extremely low compared to the axillary and internal mammary nodes, 0.8-2.0 when the cpm at the site of injection was taken as 100. No changes of cpm was noted by the site of injection. They appeared as spots on the scintigram in 17 cases. The small size of the lymph node naturally contributes to this phenomenon and the flow also appears to be small. Entire absence of correlation between the adjoining medial group of axillary lymph node (1b) and internal mammary node group (3) might indicate the presence of independent pathway leading to the subclavian nodes.

The rate of appearance of subclavian lymph nodes as spots on the scintigram was $16.4 \pm 3.5\%$ ($P < 0.05$) and even the highest possibility does not exceed 20%. Whether the subclavian lymph nodes should be defined as Group 1 lymph nodes or Group 2 lymph nodes requires further study.

No significant difference was noted between cpm in the supraclavicular lymph nodes and that on other parts of the trunk after six hours. In only three cases, they appeared as weak spots on the scintigram. The rate of appearance on the scintigram is $3.6 \pm 1.8\%$ ($P < 0.08$) and the highest possibility, 5.4%. It is extremely rare to see metastasis to the supraclavicular nodes at the time of operation. Consequently, the supraclavicular lymph node group probably belong to the second group lymph node of the breast. Lymph nodes behind the sternal manubrium were not at all visualized on the scintigram. In the statistical analysis, however, possibility of appearance as much as 1.0% ($P < 0.01$) still remains.

TABLE 2 LYMPH NODE GROUP RELATED
TO MAMMARY GLAND

lymph node group	
1	axillary lymph node (1) Rotter's lymph node (5a) internal mammary node (3)
2	subclavicular node (2) Halsted's node (5b) supraclavicular node (4)
3	retromanubrium sterni node (5d)

(): lymph node number ruled by Japanese Research Society for Mammary Cancer

At the time of operation, however, the lymph nodes behind the manubrium sterni can almost never be palpated. They may be noted only in recurrent cases and cases of stage IV, so that they probably should be classified as Group 3 lymph nodes. Table 2 summarizes these findings.

The degree of removal of lymph nodes was defined as described above to determine N-number, and this was applied to the current rule on the handling of breast cancer.

Acknowledgement: The author expresses sincere gratitude to Prof. S. TANAKA of our Department for kind encouragement and advices and is indebted to Dr. Yasuhisa YAMAMOTO and Dr. Yasuhiro FUJII for the guidance throughout the present series of study.

REFERENCES

1. Japanese Research Society for Mammary Cancer: The general rules for mammary cancer in clinic and pathology, Kanahara-Shuppan, Tokyo, 1971 (in Japanese)
2. ROBERTS, W. J.: Recherche de l'or dans les tissus animaux par la méthode du développement physique. *Bull. histol. appl.* **12**, 344-361, 1935
3. KANEKO, H.: Soshiki-Hyohon, p.63, Igaku-shoin, Tokyo 1970 (in Japanese)
4. TURNER-WARWICK, R. T.: The lymphatics of the breast. *Brit. J. Surg.* **46**, 574-582, 1959
5. HULTBORN, K. A., LARSSON, and RAGNHULT, I.: The lymph drainage from the breast to the axillary and parasternal lymph nodes, studied with the aid of colloidal Au¹⁹⁸. *Acta Radiol.* **43**, 52-61, 1955
6. LARSEN, R. R., SAWYER, K. C., SAWYER, R. B. and TORRES, R. C.: Occult carcinoma of the breast. *Amer. J. Surg.* **107**, 553-559, 1964
7. PUTTI, F.: Ricerche anatomiche sui linfonodi mammari interni. *Chirurgia Italiana* **7**, 161-172, 1953
8. ARÃO, A. and ABRAO, A.: Estudo anatômico da cadeia ganglionar mamária interna em 100 casos. *Rev. paulista de Med.* **45**, 317, 1954 (referred from Diseases of the Breast edited by Haagensen, C. D., 1971, p. 45)
9. ROUVIER, H.: Anatomie des Lymphatiques de l'Homme. Paris, Masson, 1932
10. HANDLEY, R. S. and THACKRAY, A. C.: Invasion of internal mammary lymph nodes in carcinoma of the breast. *Brit. Med. J.* **1**, 61-66, 1954
11. HAAGENSEN, C. D.: Diseases of the Breast, Chapter 1, The internal mammary lymph nodes, p. 43-52, 1971
12. ANDREASSEN, M., DAHL-IVERSEN, E. and SØRENSEN, B.: Glandular metastases in carcinoma of the breast; results of a more radical operation. *Lancet* **1**, 176-178, 1954
13. URBAN, J. A.: Surgical excision of internal mammary nodes for breast cancer. *Brit. J. Surg.* **51**, 209-212, 1964