

Acta Medica Okayama

Volume 46, Issue 2

1992

Article 11

APRIL 1992

Mechanical circulatory support with a centrifugal pump after open heart surgery.

Kozo Ishino* Taiji Murakami† Shunji Kawakami‡
Toshiyuki Dohi** Hiroyuki Irie†† Hironobu Nakayama‡‡
Yoshimasa Seono§ Shigeru Teramoto¶

*Okayama University,

†Okayama University,

‡Okayama Red Cross Hospital,

**Dohi Hospital,

††Okayama University,

‡‡Okayama University,

§Okayama University,

¶Okayama University,

Mechanical circulatory support with a centrifugal pump after open heart surgery.*

Kozo Ishino, Taiji Murakami, Shunji Kawakami, Toshiyuki Dohi, Hiroyuki Irie, Hironobu Nakayama, Yoshimasa Seono, and Shigeru Teramoto

Abstract

Since December 1988, a centrifugal ventricular assist device (VAD) was used to support the circulation in 5 patients who could not be weaned from cardiopulmonary bypass (CPB) or developed cardiogenic shock after removal from CPB. Three patients required a left VAD, one needed a right VAD. One patient had biventricular support using a centrifugal left VAD and a diaphragm type right VAD. The duration of the centrifugal VAD support ranged from 6 to 136 (mean 72)h. All patients were weaned from the VAD, but only 2 patients were discharged from the hospital. Two patients died of multiple organ failure, and one died of cardiogenic shock caused by intractable arrhythmia. Infection occurred in all non-survivors, and 2 of them developed renal failure. We conclude that the centrifugal VAD is effective to recover a failing ventricle. The factors related to the unsuccessful recovery were delayed start of the VAD support and major complications such as infection as infection and renal failure.

KEYWORDS: ventricular assist device, centrifugal pump, cardiogenic shock, infection, renal failure

*PMID: 1575059 [PubMed - indexed for MEDLINE]

Copyright (C) OKAYAMA UNIVERSITY MEDICAL SCHOOL

Mechanical Circulatory Support with a Centrifugal Pump after Open Heart Surgery

Kozo Ishino*, Taiji Murakami, Shunji Kawakami^a, Toshiyuki Dohi^b, Hiroyuki Irie, Hironobu Nakayama, Yoshimasa Senoo and Shigeru Teramoto

Second Department of Surgery, Okayama University Medical School, Okayama 700, ^aOkayama Red Cross Hospital, Okayama 700, and ^bDohi Hospital, Mihara 723, Japan

Since December 1988, a centrifugal ventricular assist device (VAD) was used to support the circulation in 5 patients who could not be weaned from cardiopulmonary bypass (CPB) or developed cardiogenic shock after removal from CPB. Three patients required a left VAD, one needed a right VAD. One patient had biventricular support using a centrifugal left VAD and a diaphragm type right VAD. The duration of the centrifugal VAD support ranged from 6 to 136 (mean 72) h. All patients were weaned from the VAD, but only 2 patients were discharged from the hospital. Two patients died of multiple organ failure, and one died of cardiogenic shock caused by intractable arrhythmia. Infection occurred in all non-survivors, and 2 of them developed renal failure. We conclude that the centrifugal VAD is effective to recover a failing ventricle. The factors related to the unsuccessful recovery were delayed start of the VAD support and major complications such as infection and renal failure.

Key words : ventricular assist device, centrifugal pump, cardiogenic shock, infection, renal failure

Despite improved myocardial protection, low cardiac output as a result of intraoperative myocardial injury remains one of the major causes of death following cardiac surgery. Appropriate use of volume loading, inotropic agents, rhythm control, and intra-aortic balloon pump (IABP) will make survival of many these patients possible. However, a small percentage of patients develop ventricular failure refractory to the above therapy. Temporary ventricular assist devices (VADs) are capable of completely replacing total ventricular function for several days; thus there

is time for recovery of any reversible myocardial injury. This report is a summary of our experience with use of a centrifugal VAD in 5 cardiac surgical patients in whom it was evident that survival was not otherwise possible.

Materials and Methods

Description of the device and technique for insertion. The centrifugal pump (Bio-Pump, Biomedicus, Inc., Minneapolis, MN, USA) was a vortex pump constructed of valveless acrylic rotor cones magnetically coupled to an external drive motor. This design generates a nonpul-

* To whom correspondence should be addressed.

satile flow depending on its preload, afterload and motor speed. One type of the cannulae (National Cardiovascular Center, Osaka, Japan) had a smooth blood-contacting surface coated with segmented polyurethane, and a Dacron graft formed the end of the outflow cannula which permitted a standard anastomosis to the aorta or pulmonary artery. Other types of cannulae were the standard USCI aortic cannula and venous cannula (William Harvey, Inc., Santa Ana, CA, USA).

For left ventricular support, the Dacron graft of the infusion cannula was anastomosed end-to-side to the ascending aorta. The withdrawal cannula was placed into the left atrium through the cuff which was sutured to the left atrial appendage or just posterior to the interatrial groove near the origin of the right upper pulmonary vein. For support of the right ventricle, the infusion cannula was anastomosed to the pulmonary artery or positioned into it through a purse-string suture, with the withdrawal cannula inserted directly into the right atrium through a cuff or a purse-string suture. The inflow and outflow cannulae exited the mediastinum through the sternotomy incision and connected to the centrifugal pump by Tygon tubing (Morton, Inc., Akron, OH, USA). Therefore the sternum was open, but the skin was approximated. The VAD lines were insulated against heat loss with bandages.

After weaning from cardiopulmonary bypass (CPB) heparin was completely reversed with protamine. During the VAD support, the activated clotting time (ACT) was maintained between 150 and 200 sec with an intermittent intravenous heparin infusion. In order to preclude a thrombus formation, the pump-head was initially changed every 24h, but during the latter half of the study it was changed every 48h.

Indication of the centrifugal VAD. The VAD was used in the patients who met a predetermined set of shock criteria derived from the studies of Norman *et al.* (1): cardiac index less than 2.0 l/min/m² and systolic blood pressure less than 90 mmHg, despite an optimal preload level, maximum inotropic support, and IABP support.

Weaning from the centrifugal VAD. When systolic arterial pressure had been stabilized above 100 mmHg for 24h, the dose of catecholamine infusion was reduced as much as possible, and pump flow was then decreased to a minimum of 1.0 to 1.5 l/min. When pump-on/pump-off data obtained during planned interruption of the VAD of up to one min were satisfactory in conjunction with hemodynamic stability at a minimum VAD flow for at least 24h, elective decannulation was

performed in an operating room and was followed by standard sternotomy closure.

Results

Since December 1988, the centrifugal VAD was used in 5 patients, aged 22–64 (mean 51) years, after cardiac surgery. Two patients were men and 3 were women. Preoperative characteristics of the patients are listed in Table 1. Three patients had valvular heart disease, one had an annuloaortic ectasia, and one had an ischemic heart disease. Preoperative cardiac function measured by cardiac catheterization and echocardiography was severely impaired in 2 patients and normal in 3 patients. One patient was in New York Heart Association (NYHA) functional class IV, 3 patients were in III, and one patient was in II.

Operative data are listed in Table 2. Operations were performed with standard CPB technique and moderate hypothermia (28 °C). After the ascending aorta was clamped, cold crystalloid cardioplegic solution (St. Thomas' Hospital solution) was delivered into the aortic root. Additional cardioplegic solution was administered every 30 min during the ischemic period, and myocardial protection was also obtained by topical cooling with ice slush in the pericardial cradle. Two patients underwent aortic valve replacement, and in the one patient coronary artery bypass grafting was added. Aortic root replacement by

Table 1 Patients' data before operation

Patient no.	Age	Sex	Diagnosis	C.I. (l/min/m ²)	EF (%)	NYHA class
1	22	M	AAE	1.82	25	IV
2	58	F	AS & MS	2.99	65	III
3	58	M	OMI	2.96	83	III
4	54	F	AS	2.50	74	II
5	64	F	AS	2.11	38	III

C.I.: cardiac index, EF: ejection fraction, NYHA: New York Heart Association, AAE: annuloaortic ectasia, AS: aortic stenosis, MS: mitral stenosis, OMI: old myocardial infarction.

Cabrol's procedure was performed in one patient, mitral and aortic valve replacements in one patient, and triple coronary artery bypass grafting in one patient.

At the end of the planned operative procedure attempts were made to remove all patients from CPB using volume loading, inotropic agents, and atrioventricular pacing. In case 1 the IABP was placed before CPB and in the other patients the IABP was inserted as an adjunctive effort to wean the patient from CPB. The VAD was used in 3 patients (cases 1, 2 and 3) because they could not be weaned from CPB. Two of them had been maintained on partial CPB for 5 h before the VAD support. Although 2 patients were removed from CPB without a VAD, the one (case 4), however, returned to the operating room after 8 h for insertion of a VAD because the cardiac function deteriorated progressively in the

intensive care unit (2) and the other patient (case 5) required a VAD after removal of CPB because of a right ventricular asystole due to the right coronary artery dissection. In both patients, the VAD was inserted without reinstating CPB. In all patients, systolic arterial pressure before VAD support was at less than 80 mmHg. Excluding case 4, the duration from aortic declamping to initiation of the VAD support ranged from 37 to 420 (mean 236) min.

Results of the VAD supports are listed in Table 3. Three patients received the centrifugal left VAD (LVAD, Fig. 1A), one received the centrifugal right VAD (RVAD, Fig. 1B), and one received a biventricular assist device (BVAD, Fig. 1C) using a centrifugal pump for the left side and a diaphragm pump for the right. In case 1 the centrifugal LVAD was converted to a pusher-plate pump 43 h later because the long

Table 2 Types and conditions of operation

Patient no.	Operation	Aortic clamp time (min)	CPB time (min)	Syst. blood pressure before VAD support (mmHg)	Aortic declamp to VAD support (min)
1	Ao root replace	229	412	65	37
2	AVR, MVR Ao root enlarge	178	1st 243 2nd 300	62	359
3	CABG (3)	237	1st 422 2nd 300	73	420
4	AVR	139	375	72	1230
5	AVR Ao root enlarge CABG (1)	113	189	45	128

CPB: cardiopulmonary bypass, Ao root replace: aortic root replacement, AVR: aortic valve replacement, MVR: mitral valve replacement, Ao root enlarge: aortic root enlargement, CABG: coronary artery bypass grafting (number of vessels grafting).

Table 3 Results of ventricular assist device (VAD) support

Patient no.	Type of support	Type of device	Duration of support (h)	C.I. before weaning (l/min/m ²)	Weaned	Outcome
1	LVAD	Centrifugal	43	2.47	Yes	Death (POD 62)
		↓ Pusher-plate	55			
2	BVAD	L: Centrifugal R: Diaphragm	87 205	3.34	Yes	Death (POD 59)
3	LVAD	Centrifugal	136	3.66	Yes	Death (POD 64)
4	LVAD	Centrifugal	88	2.97	Yes	Alive
5	RVAD	Centrifugal	6	1.89	Yes	Alive

POD: postoperative days, LVAD: left VAD, BVAD: biventricular assist device, RVAD: right VAD.

term support was expected to recover the left ventricular function. Total duration of the VAD support ranged from 6 to 205 (mean 107)h; the centrifugal pump had been used for 6 to 136 (mean 72)h. All patients could be weaned from the VAD and 2 patients were discharged from the hospital. Two patients (cases 1 and 2) died of multiple organ failure and one patient (case 3) died of cardiogenic shock caused by sudden onset of complete heart block.

Complications are listed in Table 4. Infection occurred most commonly. Non-survivors were intubated throughout the postoperative course, and 2 patients (cases 2 and 5) had pneumonia. In 2 patients (cases 2 and 4) bleeding and the sheer

volume of space filled by the cannulae made the wound closure impossible. Case 2 developed sepsis several days after the VAD weaning and case 1 had mediastinitis, which developed into septicemia. Two patients (cases 1 and 4) required

Table 4 Complications observed in patients supported with ventricular assist device

	No. of patients	No. of survivors
Infection	3	0
Renal failure (dialysis)	2	0
Bleeding	2	1
Perioperative infarct	1	0
DIC	1	0

DIC: disseminated intravascular coagulation.

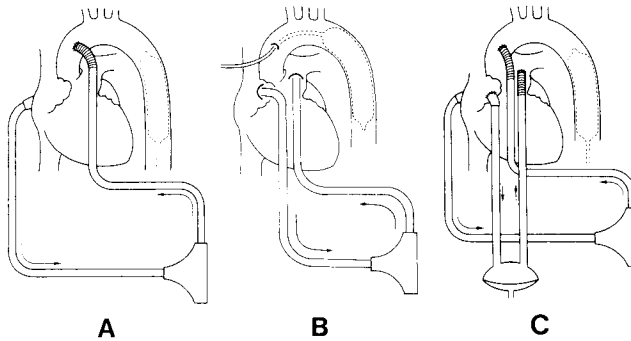


Fig. 1 Type of the mechanical ventricular support. A: Left ventricular assist device (LVAD) + intra-aortic balloon pump (IABP), B: right VAD (RVAD) + IABP, C: biventricular assist device (BVAD) + IABP.




Fig. 2 Thrombus on the rotor impeller of the centrifugal pump after 48h perfusion in case 3.

mediastinal reexplorations for bleeding, which were done in the intensive care unit and revealed bleeding around the left atrial cannulation sites. Renal failure requiring dialysis developed in 2 patients (cases 1 and 2) while on the VAD support. Patients whose condition had been complicated by infection or renal failure were all non-survivors. Perioperative myocardial infarction occurred in case 1, who consequently could not be weaned from the IABP. Case 3 had disseminated intravascular coagulation (DIC). Although coagulation defects were recognized in some of the other patients, the defects were of diverse origin and therefore not indicative of DIC.

Thrombus was found in only one pump. In the second pump used in case 3 a huge thrombus formed on the rotor impeller after 48h perfusion with a flow of 1.0 to 1.5 l/min despite the fact that the ACT was maintained longer than 200 sec (Fig. 2).

The two survivors have now been followed up for 15 to 18 months. These patients currently have no cardiac symptoms and are in NYHA functional class I.

Discussion

With growing experience of the clinical application of postcardiotomy VADs, it has become apparent that successful use of the VAD is associated with better control of postoperative bleeding and aggressive treatment of right ventricular failure, and that infection, renal failure requiring dialysis and perioperative myocardial infarction are highly predictive of death (3,4, 5). The bleeding in 2 patients was caused by technical failure of the drainage cannulation. Infection and renal failure were also fatal complications in our series. Case 1 had a renal dysfunction preoperatively, which developed into irreversible renal failure during the VAD support. He also had a mediastinitis, possibly caused by multiple reexplorations for bleeding. Although he was weaned from the VAD, the myocardial func-

tion did not recover because of perioperative infarction in the left ventricle. The BVAD patient also developed renal failure while on the VAD support and had pneumonia followed by sepsis. Hypotension before the VAD support might contribute to the renal failure in this case.

The determination of which VAD (left, right, or both) should be inserted is based on an intraoperative assessment of left and right ventricular function. Pennock *et al.* (6) and Pennington *et al.* (3) explained how to diagnose predominant or balanced ventricular failure. However, it is more difficult to recognize the failing ventricle using only pressure measurement on CPB. Our idea of using VAD for postcardiotomy shock is first to unload the left ventricle. If this fails despite volume loading and maximum inotropic support, RVAD is then added to ensure an adequate blood return to the left side. In case 2, LVAD flow achieved initially a maximum of 0.6 l/min with an elevation in right atrial pressure to 22mmHg and the RVAD was then assembled. In case 5 treated with an isolated RVAD and IABP, right ventricular failure was determined visually by the contractility.

Assessment of ventricular recovery and decision-making in preparation for weaning were based on the monitored hemodynamic variables. We judged the initiation of functional recovery of the failing ventricle using a characteristic function of the centrifugal blood pump; with a constant motor speed, pump flow decreased automatically depending on the elevation of afterload (systemic or pulmonary artery pressure). When the patient had received anticoagulants, the periods off the pump for evaluation of cardiac function were permitted for as long as 1 min. When there was evidence of progressive sustained improvement of ventricular function, the VAD flow was decreased in stages to as low as 1.0 to 1.5 l/min and was maintained for 24h before removal of the VAD.

One of the important lessons we have learned in this series concerns the management of thrombus formation in the centrifugal pump. Of total

12 pumps, one pump had a huge thrombus after 48h perfusion with the pump flow of 1.0 to 1.5 l/min. Magovern *et al.* recommended the omission of heparin, to maintain flow above 2 l/min and to change the pump head every 24h in order to prevent bleeding or formation of microthrombus (7). Joyce *et al.* fully heparinized the patient when the pump flow was reduced to 1.5 l/min (5). On the other hand, Golding *et al.* used the centrifugal VAD as a bridge to cardiac transplantation for 31 days maintaining the ACT at 150 sec by a continuous heparin infusion and emphasized that the pump head should be changed only when there is evidence of malfunction (8).

The most important determinant in our results was the length of delay before the use of the device. In this series the VAD was applied in 4 emergency cases, in 2 of which, patients required prolonged CPB for 5h before initiation of the VAD support and neither was a long-term survivor. It would appear that multiple attempts to wean the patient from CPB result in further ischemic myocardial injury and also in other organ dysfunction. It should be kept in mind that earlier application of VAD is necessary for patients' survival.

References

1. Norman JC, Cooley DA, Igo SR, Hibbs CW, Johnson MD, Bennett JG, Fuqua JM, Trono R and Edmonds CH: Prognostic indices for survival during postcardiotomy intra-aortic balloon pumping. *J Thorac Cardiovasc Surg* (1977) **74**, 709-720.
2. Ishino K, Kawakami S, Furutani S, Imai S, Nakayama H, Murakami T, Senoo Y and Teramoto S: Successful use of the centrifugal ventricular assist device for postcardiotomy cardiogenic shock. *Acta Med Okayama* (1991) **45**, 315-320.
3. Pennington DG, Kanter KR, McBride LR, Kaiser GC, Barner HB, Miller LW, Naunheim KS, Fiore AC and Willman VL: Seven years' experience with the Pierce-Donachy ventricular assist device. *J Thorac Cardiovasc Surg* (1988) **96**, 901-911.
4. Parascandola SA, Pae Jr. WE, Davis PK, Miller CA, Pierce WS and Waldhausen JA: Determinants of survival in patients with ventricular assist devices. *Trans Am Soc Artif Intern Organs* (1988) **34**, 222-228.
5. Joyce LD, Kiser JC, Eales F, King RM, Toninato CJ and Hansen J: Experience with the Sarns centrifugal pump as a ventricular assist device. *Trans Am Soc Artif Intern Organs* (1990) **36**, M619-M623.
6. Pennock JL, Pierce WS, Wisman CG, Bull AP and Waldhausen JA: Survival and complications following ventricular assist pumping for cardiogenic shock. *Ann Surg* (1983) **198**, 469-478.
7. Magovern GJ, Park SB and Maher TD: Use of a centrifugal pump without anticoagulants for postoperative left ventricular assist. *World J Surg* (1985) **9**, 25-36.
8. Golding LA, Stewart RW, Sinkewich M, Smith W and Cosgrove D: Nonpulsatile ventricular assist bridging to transplantation. *Trans Am Soc Artif Intern Organs* (1988) **34**, 476-479.

Received December 20, 1991; accepted February 6, 1992.