

Acta Medica Okayama

Volume 22, Issue 3

1968

Article 4

JUNE 1968

Experimental study on vascular graft. II. Replacement of inferior vena cava and abdominal aorta with the autogenous segment of small intestine submucosa

Shigemi Egusa*

*Okayama University,

Copyright ©1999 OKAYAMA UNIVERSITY MEDICAL SCHOOL. All rights reserved.

Experimental study on vascular graft. II. Replacement of inferior vena cava and abdominal aorta with the autogenous segment of small intestine submucosa*

Shigemi Egusa

Abstract

Replacement of abdominal vena cava with a fresh autogenous substitute, the segment of small intestinal submucosa, was attempted in 15 animals. Five segments were prepared from the intestine smeared with iodine tincture, and reinforced with a steel coil externally in the entire length and a steel or polyethylene ring at the anastomosis. Thoracoabdominal long implantation was done in three animals, of which one with the intestinal segment devoid of mucosa, and the other two with the submucosa. Replacement of abdominal vena cava with the submucosa taken out of the intestinal segment preserved for nine days in 1% mercurochrome solution, or 0.1 % acrinolum solution was done in one animal each. In these two a coil and two rings were also applied. Replacement of abdominal aorta with the double layer tube of a reconstructed submucosa and another very porous Tetoron gauze was done in two animals, each coupled with the abdominal vena cava replacement at the same time. Of these experiments, aorta replacements were nearly patent in both. The abdominal vena cava replacements made of the submucosa treated with iodine tincture were patent in three. The one that was preserved in acrinolum showed moderate constriction. Most of the others were also observed for a long period of time but these all occluded in spite of the initial patency which was revealed at three to seven days in cavograms, and the time of the occlusion was not determined. The internal surface of the segment of submucosa, being implanted, is covered in the first stage with the deposition of fibrin, which is subsequently organized into a fibrous layer, in the same manner as that of the synthetic graft. Another disadvantage of this substitute is its readily collapsible tendency. Infection is preventable in the experiment. The substitute seems to be useful for the replacement of aorta and for the short segment of vena cava.

*PMID: 4239073 [PubMed - indexed for MEDLINE] Copyright ©OKAYAMA UNIVERSITY
MEDICAL SCHOOL

EXPERIMENTAL STUDY ON VASCULAR GRAFT
II. REPLACEMENT OF INFERIOR VENA CAVA AND ABDONINAL
AORTA WITH THE AUTOGENOUS SEGMENT OF
SMALL INTESTINAL SUBMUCOSA*

Shigemi EGUSA

*Department of Surgery, Okayama University Medical School,
Okayama, Japan (Director: Prof. T. Sunada)*

Received for publication, April 18, 1968

Replacement of blood vessel is desirable to be made with an auto-genous one but it is not actually possible to obtain such material for a large blood vessel. For this reason, as a new, hitherto not described, blood vessel substitute, the fresh submucosa of autogenous small intestine has been experimentally studied by the author for the past few years.

The structure of small intestine is not identical among different species of animals, and with dogs it is found to be as follows: Mucosa is excluded from this study because of possible infection. The intestine devoid of mucosa is thick and its tendency to flatten is not sufficiently opposed by a relatively low pressure in venous circulation. Serosa is very thin and feeble, hence is not suitable for a blood vessel substitute. Muscle layer is relatively thick and it is difficult to separate it without breaking because its fibers are apt to loosen. The submucosa, including submucous muscle lamina, is very thin, smooth, elastic, pliable and semilucid. The adhesion between mucosa and submucosa is so firm that the dissection into the layers is impossible but mucosa is easily scraped off with a knife and fingers. The present paper deals with the studies on the implanatation of the segment of submucosa inclusive of submucous muscle lamina and the segment of intestine devoid of mucosa.

MATERIALS AND METHODS

Twenty adult mongrel dogs, weighing 8 to 15 kg, were anesthetized with intravenous pentobarbital sodium 25 to 30 mg per kg. In the early experiments the segment of submucosa were prepared as follows. An excised intestinal segment was immediately put into sterilized physiological saline solution, where it was inverted inside out and mucosa was scraped off within a few minutes with a knife and fingers.

* Read at the 65th General Meeting of the Japanese Society for Surgery, Tokyo, April 1965.

The remaining submucosa was washed atraumatically for several minutes. In the later experiments the excised intestinal segment was smeared once with iodine tincture and a few minutes later was placed into sterilized physiological saline solution, followed by the same treatment as above mentioned. In one instance the excised intestinal segment was preserved in 1% mercurochrome saline solution for nine days before the transference into the saline solution for the treatment as above mentioned. In another instance 0.1% acrinolum saline solution was used instead of the mercurochrome solution. At the operation penicillin 400,000 units and streptomycin 0.5 g were spread over the operation field. In the later experiments the same dose of these antibiotics was intramuscularly administered every day for four consecutive days. No anticoagulant was used either during or after operation.

Group A: Replacement of abdominal inferior vena cava was attempted with the segment of fresh submucosa in five animals. Abdominal vena cava was exposed through the midline incision, and after the excision of the segment about 3 cm in length of vena cava distal to renal veins, the substitute (submucosa) approximately 4.5 cm in length was placed and anastomosed end-to-end with 6-0 silk thread by interrupted suture. After the replacement, the lumen of the substitute was slightly constricted with a row of continuous longitudinal suture (Fig. 1).

Group B: Replacement of abdominal inferior vena cava was attempted with reconstructed tube of the fresh submucosa in five animals. The segment of submucosa was opened longitudinally and retubulated with interrupted sutures after being somewhat excised, so as to make a little larger than the vein. At the retubulation a metallic plate was inserted in it to make the suture easy and secure. The substitute was inserted in the same manner as in group A.

Group C: Replacement of thoracoabdominal inferior vena cava was done with long segment of fresh submucosa in two animals and with long segment of fresh intestine devoid of mucosa in one animal. Right thorax was opened through the seventh and eleventh intercostal spaces. While thorax was open, respiration was maintained by a mechanical respirator. Posterior diaphragm was incised and opened radially, then retracting liver anteriorly, abdominal vena cava was exposed. The substitute was placed between just above renal veins and just below right

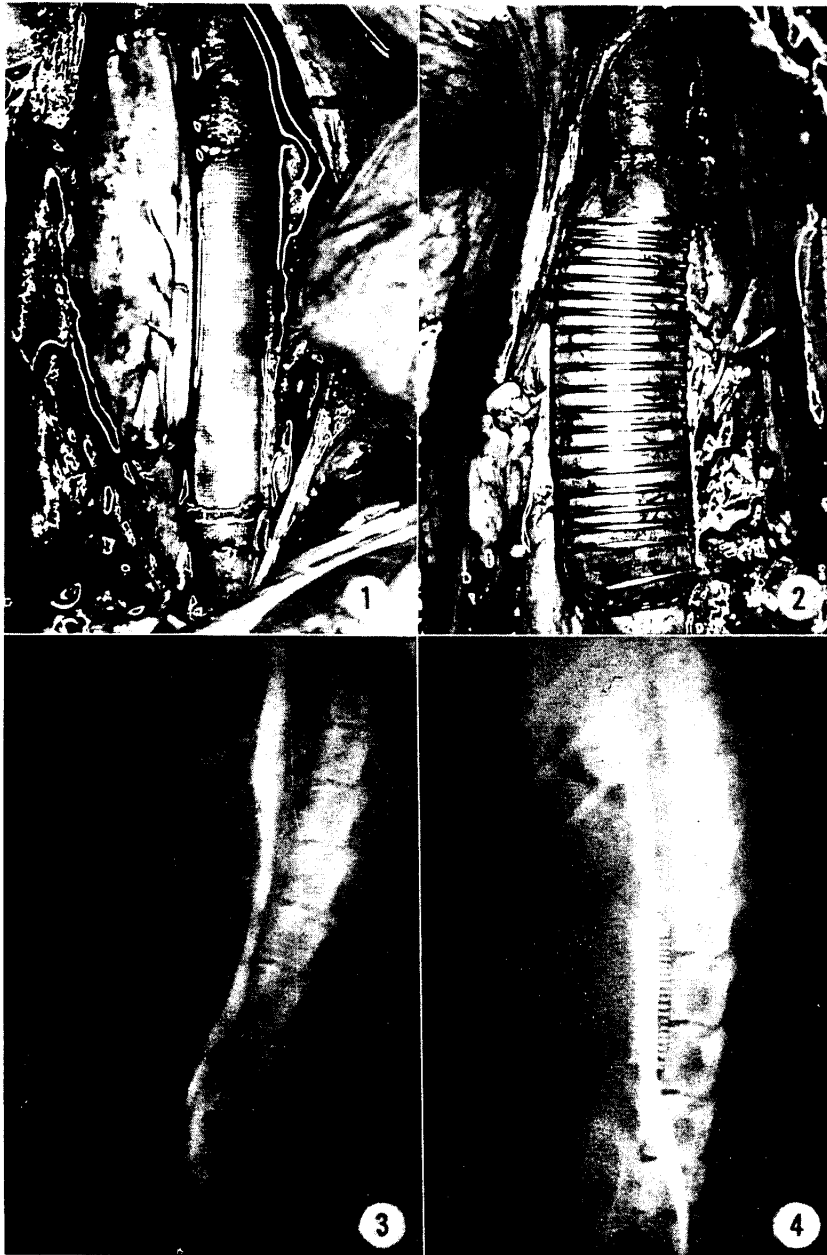
Fig. 1 Left, replacement of abdominal vena cava with autogenous intestinal submucosa. Longitudinal continuous suture is placed in order to make the submucosa somewhat small. Right, replacement of abdominal aorta with double layer tube of reconstructed submucosa and Tetoron gauze.

Fig. 2 Replacement of abdominal vena cava with autogenous intestinal submucosa, applying coil and rings.

Fig. 3 Cavogram of the abdominal vena cava shown in Fig. 1, five days after replacement. The substitute (submucosa) is patent in this cavogram, but it showed occlusion in the next cavogram of 117 days after replacement.

Fig. 4 Cavogram, seven days after replacement of abdominal vena cava with the submucosa, applying coil and polyethylene rings. The substitute is patent in this cavogram, but showed occlusion in the next cavogram of 58 days after replacement.

atrium and anastomosed to the right wall of the vein end-to-side under the partial occlusion of the vein with clamps applied longitudinally. After completing the anastomosis thoracic inferior vena cava was excised between ligatures. A coil of



hard molybdenum stainless steel wire was externally put on a part of the substitute to resist its being compressed by liver.

Group D: Replacement of abdominal inferior vena cava was attempted with the segment of fresh submucosa disinfected with iodine tincture and reinforced with a ring of steel wire or polyethylene at the anastomosis site and a steel coil in the full length of it (Fig. 2) in five animals. Vena cava distal to renal veins was excised about 2 cm in length and the substitute of about 2.5 cm was inserted end-to-end by continuous over and over suture. Prior to the replacement a ring of 8 to 9 mm in diameter, made of hard molybdenum stainless steel wire of 0.4 mm in thickness or made of polyethylene of 1 mm in thickness and 1 mm in width was fixed at both ends of the substitute with several interrupted sutures, which was performed with ease under the support of a hard plastic tube inserted into the substitute temporarily. The ring was included in the anastomotic suture. On the other hand, the coil of steel wire was tied up into a bundle with a thread until the completion of the anastomosis and then, it recoiled back to the original length immediately and spontaneously when the thread was cut off. The animals were given the injection of antibiotics.

Group E: Replacement of abdominal inferior vena cava was tried with the segment of preserved submucosa in two animals. An excised intestinal segment was preserved in 1% mercurochrome saline solution in the one and 0.1% acrinolum saline solution in the other, for nine days. The segment of submucosa of 2.5 cm in length was taken out and soon inserted into abdominal vena cava distal to renal veins with application of a polyethylene ring to the anastomosis and a steel coil to the substitute in the same way as in group D. The animals received antibiotics postoperatively.

Group F. Replacement of abdominal aorta distal to renal arteries was attempted with a double layer tube consisting of a reconstructed tube of fresh submucosa and another Tetoron gauze tube (Fig. 1) in two animals. The replacement was performed concurrently with the vena cava replacement in one animal

Table 1. Replacement of blood vessel with the autogenous segment of small intestinal submucosa

Dog No.	Dog(Kg) weight	Graft length (cm)	Duration of follow up	Patency of substitute	Cause of death	Remarks
A: Replacement of abdominal inferior vena cava with the sement of fresh submucosa						
1	8	4.0	21 days	Occluded	Sacrifice	Patent in the first cavogram at 3 days
2	10	4.5	66 days	Occluded	Sacrifice	Patent in the first cavogram at 3 days
3	10	4.5	110 days	Occluded	Sacrifice	Patent in the first cavogram at 3 days
4	11	4.5	112 days	Occluded	Sacrifice	Patent in the first cavogram at 5 days
5	11	4.5	117 days	Occluded	Sacrifice	Patent in the first cavogram at 5 days

B: Replacement of abdominal inferior vena cava with the reconstructed tube of fresh submucosa						
1	10	4.0	30 days	Occluded	Sacrifice	Patent in the first cavogram at 3 days
2	10	4.0	30 days	Occluded	Sacrifice	Patent in the first cavogram at 3 days
3	11	4.5	74 days	Occluded	Sacrifice	Patent in the first cavogram at 5 days
4	12	4.5	35 days	Occluded	Sacrifice	Patent in the first cavogram at 5 days
5	12	4.5	35 days	Occluded	Sacrifice	Patent in the first cavogram at 5 days
C: Replacement of thoracoabdominal inferior vena cava with the segment of fresh submucosa						
1	13	12	14 days	markedly constricted	Sacrifice	
2	15	12	28 days	constricted	Dispepsia	
Replacement of thoracoabdominal inferior vena cava with the segment of fresh intestine devoid of mucosa						
3	13	12	2 days	Occluded	Occlusion of substitute by thrombus	
D: Replacement of abdominal inferior vena cava with the segment of fresh submucosa prepared from intestine disinfected with iodine tincture and reinforced with a coil and two rings						
1	10	4	7 days	Occluded	Sacrifice	Occlusion by thrombus
2	10	3.5	58 days	Occluded and had the tendency to recanalization	Sacrifice	
3	11	2.5	58 days	Patent	Sacrifice	
4	12	2.5	65 days	Patent	Sacrifice	
5	12	2.5	79 days	Patent	Sacrifice	
E: Replacement of abdominal inferior vena with the segment of submucosa prepared from the preserved intestine						
1	10	2.5	33 days	Occluded	Sacrifice	Preserved in 1% mercurochrome saline solution
2	10	2.5	167 days	Moderately constricted	Escaped	Preserved in 0.1% acrinolum saline solution
F: Replacement of abdominal aorta with double layer tube consisting of a reconstructed tube of fresh submucosa and another Tetoron gauze tube						
1	10	3.5	66 days	Patent	Sacrifice	The animal No 2 in group A
2	11	3.5	74 days	Patent	Sacrifice	The animal No 3 in group B

each of groups A and group B. A segment of submucosa was retubulated in the same manner as in the case of vena cava replacement, then covered and made double with a tube of Teton porous gauze through which fluid can freely pass. After excising aorta about 3 cm, the double layer tube of 3.5 cm in length was placed and anastomosed end-to-end with 6-0 silk thread by continuous over-and-over suture.

Cavograms were taken after injection of about 10ml of 76% Urographin into a greater saphenous vein at varying periods postoperatively but aortogram was not made. Autopsy was performed after sacrifice or spontaneous death in all the animals except the one that ran away. Histological studies were done with hematoxylin eosin, Van Gieson's, silver nitrate and Azan stains. In two instances, a part of the submucosa taken out without the treatment of iodine tincture was crushed and preserved with heart infusion agar in an incubator to cultivate bacteria. In each instance no colony was observed after 24-hour incubation and 10,000 colonies per g of the material grew after 48 hours. The submucosa treated with iodine tincture was not examined bacteriologically.

OBSERVATIONS AND DISCUSSION

Group A: five animals. All substitutes were patent at three to five postoperative days in the first cavogram (Fig. 3) but showed occlusion in the next cavograms made at 21, 66, 112 and 117 postoperative days, respectively and soon the animals were sacrificed. At autopsy the implanted substitutes were overtaken by fibrous tissue, the original submucosa being scarcely distinguishable, but no abscess was present. No histological study was done.

Group B: five animals. The results were the same as in group A, namely, all substitutes were patent at three to five days and showed occlusion in the second cavograms at 30 to 74 days, respectively, and the animals were sacrificed. Histological study was not done.

Group C: three animals. The one implanted with the long segment of intestine devoid of its mucosa, died of occlusion of the substitute by thrombus two days later. The distal anastomosis tended to flatten out already when it was being placed. One of the two implanted with the long segment of submucosa was in good general conditions up to the twelfth postoperative day when it became somewhat exhausted, then constriction of substitute was demonstrated at 14 days in cavogram without sign of ascites. The animal was sacrificed soon after it. The substitute was excessively compressed by liver and so firmly adhered to the adjacent tissue that it could not be taken out without tearing it. No suppuration was found, and histological examination was not performed. As for the other, though the substitute was patent at seven days in cavogram, it died of dispepsia

at 28 days. At autopsy the internal surface of the substitute was covered by an organized thin layer which adhered firmly to the substitute (Fig. 5). The organization developed especially for the distance of 2 cm from the

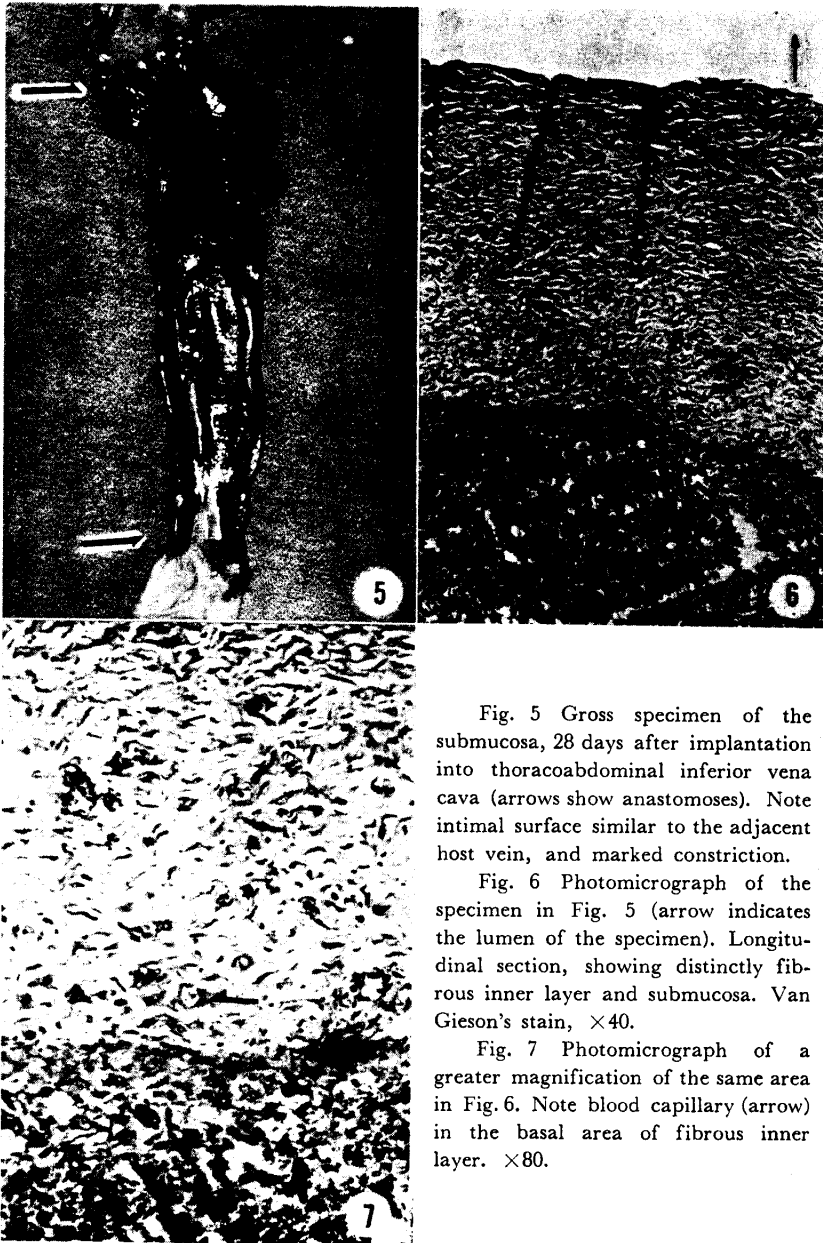


Fig. 5 Gross specimen of the submucosa, 28 days after implantation into thoracoabdominal inferior vena cava (arrows show anastomoses). Note intimal surface similar to the adjacent host vein, and marked constriction.

Fig. 6 Photomicrograph of the specimen in Fig. 5 (arrow indicates the lumen of the specimen). Longitudinal section, showing distinctly fibrous inner layer and submucosa. Van Gieson's stain, $\times 40$.

Fig. 7 Photomicrograph of a greater magnification of the same area in Fig. 6. Note blood capillary (arrow) in the basal area of fibrous inner layer. $\times 80$.

ends. However, the lumen was markedly constricted due to the thickening of the wall. The substitute was relatively easy to take out and examined histologically (Figs. 6, 7).

Group D: five animals. One substitute showed occlusion at seven days in cavogram and the animal was sacrificed. At autopsy fresh thrombus was found and no histological examination was done. Another was patent at seven days in the first cavogram (Fig. 4), but revealed occlusion having a tendency to recanalization at 58 days in the second cavogram and the animal was sacrificed. The substitute was broken and surrounded by thickened fibrous tissue and it could not be taken out. The remaining three substitutes were patent showing slight stenosis at the proximal end at 58, 65 and 79 days, respectively in cavograms and the animals were sacrificed. At autopsy the internal surface of each substitute was completely organized, and it was very thin, compact, smooth and homogenous, being quite similar to the adjacent host endothelium (Fig. 8). On the external

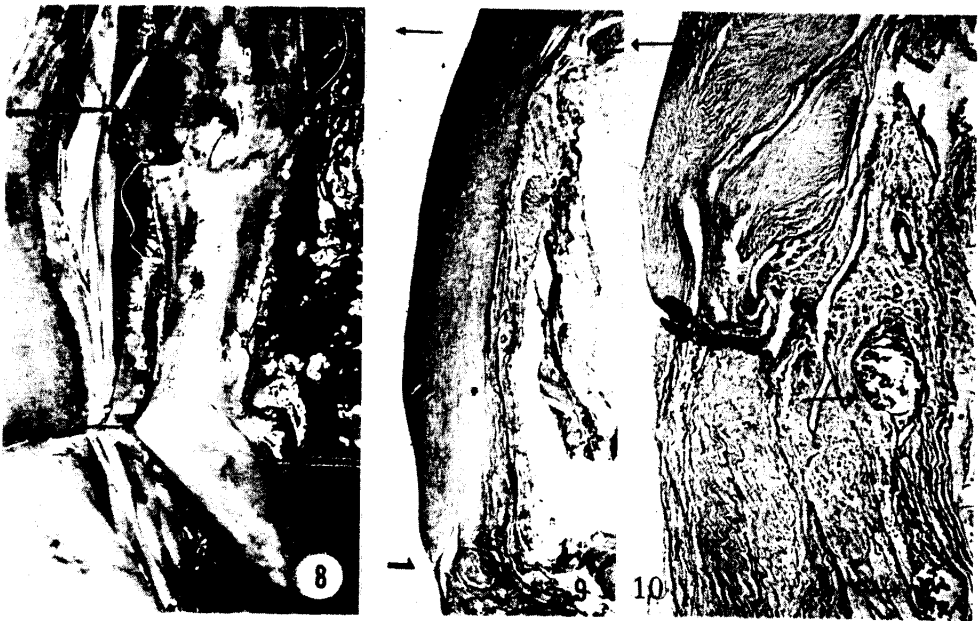


Fig. 8 Gross specimen of autogenous submucosa, 79 days after implantation into abdominal vena cava. Coil and rings were removed prior to photography.

Fig. 9 Photomicrograph of the specimen in Fig. 8. Longitudinal section showing compact fibrous inner layer and anastomosis (arrow). There is no endothelial lining visible. Van Gieson's stain, $\times 10$.

Fig. 10 Photomicrograph of another longitudinal section of the specimen in Fig. 8, showing anastomosis, well organized fibrous inner layer on the upper. Two cut surfaces of silk suture are found in the center and right lower (arrows), with minimal tissue reaction. Van Gieson's stain, $\times 16$.

surface, somewhat thickened fibrous tissue was formed, embedding the applied coil. Histologically, the internal surface was covered by a very compact fibrous inner layer but endothelial lining was indistinct, contrary to the expectation by the macroscopical findings, and the underlying submucosa was invaded by the fibrous tissue of the outer layer without necrotic sign (Figs. 9, 10).

Group E: two animals. The one substitute preserved in mercurochrome, showed occlusion at 33 days in the first cavogram. The other which was preserved in acrinolum showed a moderate constriction, attended by minimal collateral circulation, at 26 days in the first cavogram, which persisted to postoperative day 167 in the second cavogram. The animal ran away afterward.

Group F: two animals. They were sacrificed at 66 and 74 days. The substitutes were nearly patent and similar to each other in the gross findings (Fig. 11). Internal surface was well developed, smooth and similar

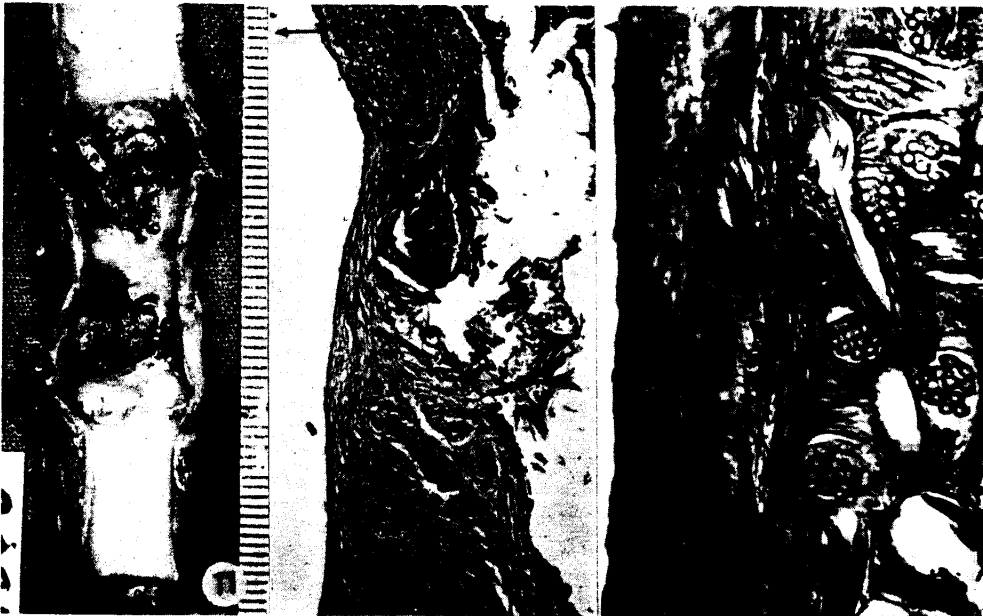


Fig. 11 Gross specimen of the double layer tube of autogenous reconstructed submucosa and Tetoron gauze, 74 days after implantation into abdominal aorta. Thin granulation is present in a portion of well organized inner layer. Note four fixation stitches.

Fig. 12 Photomicrograph of the specimen in Fig. 11. Logitudinal section showing anastomosis. Note the elastic fibers limited in the host aorta on the upper. Tetoron layer was removed before embedding the specimen into paraffin. Van Gieson's stain, $\times 16$.

Fig. 13 Photomicrograph of another longitudinal section of the same specimen, showing complete inner layer, submucosal layer and Tetoron layer. H & E, $\times 25$.

to that of the adjacent host aorta except a portion covered by a thin granulation tissue rich in blood capillaries. Histological examination revealed endothelial lining, well developed inner layer of fibrous tissue, residual submucosa, well preserved thin porous fabric of Tetoron, compactly developed outer layer, and presence of firm connection between the inner and outer layers in the interstices of the fabric but there was found no elastic fiber in the inner layer and no tissue reaction to either the submucosa or the fabric (Figs. 12, 13).

As just mentioned the ten instances of abdominal vena cava replacement whose lumen was confirmed to be patent three to seven days after the replacement, seemed to suggest that the experiment were apparently successful. However, all these revealed to be invariably occluded 21 to 117 days after the replacement though the onset time of the occlusion was undetermined. One of the long substitutes of submucosa was patent at seven days in cavogram, which was found moderately constricted at the autopsy on the 28th day. The other showed a marked compression and constriction at the autopsy on the 14th day. The one long substitute of intestine devoid of mucosa was occluded with fresh thrombus at two days. Because of these complete failures, in the next group abdominal vena cava was replaced with a shorter segment approximately 2.5cm of the submucosa taken out after the treatment with iodine tincture of a fresh segment of intestine. A fine ring was applied to each anastomotic site and hard fine coil on the outside of the substitute in the entire length. The implanted substitute was covered with peritoneum. Antibiotics were administered for five days, into abdominal cavity at the operation and thereafter intramuscularly. In these five experiments three substitutes remained patent at the autopsy on the 58th, the 65th and the 79th day, respectively. The implanted substitutes, apart from the problem of whether they would remain viable or not, were each covered by an organized layer on the internal surface. In this respect, it may be said that the segment of submucosa plays no more than a part of the supporter or a temporary substitute for the growth of a new blood vessel. This suggests the applicability of preserved intestine for the replacement. Actually in the present experiments the intestinal segment was preserved in 1% mercurochrome solution in one instance and 0.1% acrinolum solution in another, each for nine days. Individual short segment of the submucosa from the preserved intestinal segment was inserted into abdominal vena cava of the host, having reinforcement of two rings and a coil. The former revealed occlusion at 33 days in the first cavogram. The latter was narrowed and attended by

minimal collateral circulation at 26 days, which remained in the same condition up to postoperative day 167 in cavogram. Both of the two instances of abdominal aorta replacement remained slightly constricted.

As the present experiments were performed by inexperienced techniques in limited number of animals, no definitive answer may be given from the results obtained to the question as to whether the free segment of autogenous submucosa would be better than synthetic grafts for the material in blood vessel replacement, but the author believes that some basic knowledge of the autogenous submucosa as a blood vessel substitute has been obtained. The strip of submucosa essentially has no endothelium and after implantation its internal surface is at first coated with the deposition of fibrin, which is gradually organized into fibrous connective tissue. In this process, the submucosa, being pliable, may fall into fibrous constriction, still more so when it is compressed by the outside tissue. In addition, the submucosa is more or less contaminated by the contents. In spite of these undesirable properties the submucosa still has an advantage in causing no immunological or foreign body reaction. Actually, in all the implanted segments of submucosa no thrombosis occurred for a few days after the implantation except one that showed occlusion at seven days in the first cavogram because of mechanical injury by vigorous scrubbing at the preparation. In view of this, the submucosa appears to be superior to the synthetic graft. The present experiments of inferior vena cava replacement were successful in a few cases, of which three were obtained in group D of five animals where the replacement was made with the fresh submucosa which was prepared from the intestinal segment treated with iodine tincture and reinforced with application of a coil and two rings. The remaining one, though showing a moderate constriction, was the one where the submucosa for the replacement was prepared from the intestinal segment preserved in acrinolum solution and also reinforced with a coil and two rings. The reason of the success being limited to the instances in applying a coil and two rings is not obvious because the segment of submucosa used in this group was not only shorter than that in the other group but also prepared after the treatment with iodine tincture or the preservation in acrinolum solution. In addition, influence of accumulated experiences with surgical techniques cannot be denied. The coil was utilized on the supposition that a rigid coil would protect initially the substitute from the compression by the surrounding tissue, and later, when the substitute was embedded in the organized outer layer, the coil would prevent the fibrous constriction of the substitute similarly as observed in our previous study with synthetic grafts (1). In the present experiment a ring was

further applied to the anastomotic site with consideration to the more collapsible tendency of the substitute. Further experiments with larger vein such as thoracic vena cava or abdominal vena cava in bigger dogs are necessary to evaluate the present substitute because the collapsible substitute having no endothelium may be unsuitable essentially for small venous replacement. While a simple ring of steel wire is too smooth to be sutured readily into the anastomosis of such a pliable material as submucosa, a similar one of polyethylene is somewhat too frail in such a fine size of 1mm. A care should be taken in the preparation of submucosa so as not to injure it. In one instance, because of injury by vigorous abrasion at preparation, sugillation occurred on the submucosa soon after the replacement was completed and circulation reestablished. On the other hand, unless scraping of mucosa is done thoroughly until submucosa becomes purely white and semitransparent, some of mucosa still remains, demonstrable microscopically. Whether the presence of the remaining mucosa influences success or failure is not determined. Abdominal aorta replacement with the segment of submucosa combined with a very porous and thin Tetoron gauze was successful with promising result in both of the limited two instances. For the replacement of aorta the segment of submucosa needs to be reconstructed smaller than the original size, suitably to the aorta, and for the reconstruction the use of sewing apparatus, if available, seems to be desirable.

CONCLUSION

Replacement of abdominal vena cava with a fresh autogenous substitute, the segment of small intestinal submucosa, was attempted in 15 animals. Five segments were prepared from the intestine smeared with iodine tincture, and reinforced with a steel coil externally in the entire length and a steel or polyethylene ring at the anastomosis. Thoracoabdominal long implantation was done in three animals, of which one with the intestinal segment devoid of mucosa, and the other two with the submucosa. Replacement of abdominal vena cava with the submucosa taken out of the intestinal segment preserved for nine days in 1% mercurochrome solution, or 0.1% acrinolum solution was done in one animal each. In these two a coil and two rings were also applied. Replacement of abdominal aorta with the double layer tube of a reconstructed submucosa and another very porous Tetoron gauze was done in two animals, each coupled with the abdominal vena cava replacement at the same time. Of these experiments, aorta replacements were nearly patent in both. The abdominal vena cava

replacements made of the submucosa treated with iodine tincture were patent in three. The one that was preserved in acrinolum showed moderate constriction. Most of the others were also observed for a long period of time but these all occluded in spite of the initial patency which was revealed at three to seven days in cavograms, and the time of the occlusion was not determined. The internal surface of the segment of submucosa, being implanted, is covered in the first stage with the deposition of fibrin, which is subsequently organized into a fibrous layer, in the same manner as that of the synthetic graft. Another disadvantage of this substitute is its readily collapsible tendency. Infection is preventable in the experiment. The substitute seems to be useful for the replacement of aorta and for the short segment of vena cava.

ACKNOWLEDGEMENT

The author is indebted much to Professor T. SUNADA, Assist. Prof. K. INADA and Dr. S. TERAMOTO for their invaluable advices. Many thanks are due to Dr. S. MEGURO, Dr. A. SEJIMA, Dr. H. MONDEN, Dr. S. KAWAMOTO and Dr. K. OTSUKA for their technical assistance and encouragement.

REFERENCE

1. EGUSA, S.: Experimental study on vascular graft. I. Replacement of inferior vena cava with crimped woven Tetoron (polyester) grafts and those reinforced with stainless steel coil. *Acta Med. Okayama* **22**, 3, 1968