

# *Acta Medica Okayama*

---

*Volume 23, Issue 6*

1969

*Article 6*

DECEMBER 1969

---

## An experimental study on the efferent connections of the amygdaloid complex in the cat

Isao Ishikawa\*

Syosuke Kawamura†

Osamu Tanaka‡

\*Okayama University,

†Tokushima University,

‡Tokushima University,

# An experimental study on the efferent connections of the amygdaloid complex in the cat\*

Isao Ishikawa, Syosuke Kawamura, and Osamu Tanaka

## Abstract

The amygdalofugal fibers were studied in the cat with the silver method of NAUTA-GYGAX. 1. The amygdalofugal fibers are distributed by way of the stria terminalis, the longitudinal association bundle, the inferior thalamic peduncle, and the medial forebrain bundle. 2. The amygdalofugal fibers running through the longitudinal association bundle arise in the lateral principal, intermediate principal nuclei and the lateral and possibly intermediate parts of the periamygdaloid cortex, and terminate in the lateral preoptic nucleus, the bed nucleus of the anterior commissure, the olfactory tubercle, the nucleus of the diagonal band of Broca, the nucleus accumbens, the medial and posterior septal nuclei and the basal part of the head of the caudate nucleus. In addition, there are scattered fibers coursing along the longitudinal association bundle proper. These fibers may have a widespread origin from the amygdaloid complex. The longitudinal association bundle contributes no fibers to the medial forebrain bundle. 3. The fibers, originating from the lateral principal, intermediate principal and medial principal nuclei, join the medial forebrain bundle to distribute widely in the lateral hypothalamic nucleus. A few fibers are seen to reach the ventromedial hypothalamic nucleus, and are considered to arise in the medial principal nucleus. 4. By way of the inferior thalamic peduncle some fibers from the amygdaloid complex course dorsally into the medial part of the dorsomedial thalamic nucleus at its caudal levels. They may arise widely from the amygdaloid complex. A few of them extend farther dorsally to reach the lateral habenular nucleus and the parataenial nucleus. They probably originate from the lateral principal nucleus. 5. The fibers forming the stria terminalis originate from the medial principal nucleus, the medial nucleus, the periamygdaloid cortex and the cortical nucleus, and are distributed in the bed nucleus of the stria terminalis and the lateral preoptic nucleus (preoptic component), as well as the medial preoptic nucleus, the anterior hypothalamic nucleus and the ventromedial hypothalamic nucleus (supracommissural component). The cortical nucleus, particularly its caudal part, and possibly the medial part of the periamygdaloid cortex are regarded as the main sources of the stria terminalis fibers ending in the hypothalamic region. The intermediate principal and lateral principal nuclei do not appear to contribute fibers to the stria terminalis. 6. The ventromedial hypothalamic nucleus receives amygdalofugal fibers both from the medial principal nucleus by way of the medial forebrain bundle, and from the cortical nucleus via the stria terminalis. 7. In addition to intrinsic internuclear fibers within the amygdaloid complex, some of the fibers from the complex

---

\*PMID: 4246441 [PubMed - indexed for MEDLINE] Copyright ©OKAYAMA UNIVERSITY MEDICAL SCHOOL

are distributed to the ventralmost part of the putamen, the medial part of the claustrum, the periamygdaloid cortex, the prepiriform area and the anterior amygdaloid area, but do not reach the hippocampus.

## AN EXPERIMENTAL STUDY ON THE EFFERENT CONNECTIONS OF THE AMYGDALOID COMPLEX IN THE CAT

Isao ISHIKAWA, Syosuke KAWAMURA and  
Osamu TANAKA

*Department of Anatomy, Okayama University Medical School, Okayama, Japan  
(Director: Prof. K. Niimi) and Department of Internal Medicine, Tokushima  
University Medical School, Tokushima, Japan (Director: Prof. T. Aburaya)*

*Received for publication, August 3, 1969*

It has long been known that the efferent fibers from the amygdaloid complex are distributed largely by way of the stria terminalis. JOHNSTON (15) first suggested the existence of the amygdalofugal pathway through the longitudinal association bundle. This was confirmed and extended by later experimental studies (FOX (9), ADEY and MEYER (1), ADEY *et al.* (3), BAN and OMUKAI (4)). These studies revealed that the ventral amygdalofugal pathway is distributed to many basal telencephalic structures, viz. the preoptic region, the hypothalamus, the thalamus, and the bed nucleus of the stria terminalis. It is of interest to note that FOX (10) found in the monkey amygdalofugal fibers entering the dorsomedial nucleus of the thalamus by way of the inferior thalamic peduncle. In recent years the Nauta silver method was found to be the best suited for tracing fiber connections, particularly of unmyelinated and finely myelinated fibers, such as the amygdalofugal fibers. Recent studies using the Nauta method have elucidated more precisely the origin, course and termination of amygdalofugal pathways (NAUTA (22), VALVERDE (28, 29), POWELL *et al.* (25), HALL (14)). However, there is a diversity of opinion among them as to details of efferent connections of the amygdaloid complex.

The present study was undertaken in an attempt to clarify the exact distribution of amygdalofugal fibers in the cat by means of the NAUTA-GYGAX technique (24) following lesions in the amygdaloid complex. Special emphasis was placed upon the topical relation of efferent fibers from different nuclei of the amygdaloid complex.

### MATERIAL AND METHODS

Operations were performed on 23 adult cats and five of these, which showed lesions fairly well localized in the amygdaloid complex, were used in the present investigation. Unilateral electrolytic lesions were placed in various parts of the

amygdaloid complex by the temporal approach under deep Nembutal anesthesia. After a survival period of 7 to 8 days, the animals were anesthetized and perfused via the carotid artery with normal saline followed by a solution of 10% neutral formalin. The brains were then removed from the skull and sectioned 10 mm thick transversely. These cut blocks were stored in 10% neutral formalin for two months, sectioned serially at 35  $\mu$  on the freezing microtome, and impregnated by the NAUTA-GYGAX (24) silver method.

The classification and terminology of the amygdaloid complex here employed are based on the investigations of the KOIKEGAMI school, particularly of KARIBE (16) in carnivores. The site and extent of the lesions in five cases are shown in Fig. 1.

## RESULTS

### *Cat 38*

In this cat the lesion extends throughout the anteroposterior extent of the left amygdaloid complex, involving the major parts of the medial principal and intermediate principal nuclei, the medial, intermediate and lateral parts of the periamygdaloid cortex and parts of the lateral principal and cortical nuclei.

Fibers from the amygdaloid complex are classified into the ventral amygdalofugal pathway and the stria terminalis. The former is distributed through the longitudinal association bundle, the medial forebrain bundle and the inferior thalamic peduncle. The degenerated fibers forming the ventral pathways run dorsomedially to pass through the sublenticular gray, in which a few fibers appear to terminate. A group of fine, densely crowded, degenerated fibers course rostrally through the longitudinal association bundle, with some medium-sized and rather fine scattered fibers along them. It proceeds farther rostrally just ventral and ventromedial to the internal capsule to reach the lateral preoptic nucleus. Passing through this nucleus, it begins to disperse medially and dorsomedially in the whole area of the lateral preoptic nucleus. At anterior levels of the anterior commissure the degenerated fibers in the dorsomedial part of the lateral preoptic nucleus continue dorsomedially, and most of them are found to terminate in the bed nucleus of the anterior commissure. Very few fibers enter the ventral part of the anterior commissure to course medially, but their final destination cannot be followed. Rostrally a considerable number of degenerated fibers coursing through the lateral part of the lateral preoptic nucleus are distributed diffusely in the olfactory tubercle and the anterior amygdaloid area. A few of them can be traced to the subcortical region of the anterior sylvian gyrus. In addition, some degenerated fibers in the ventromedial part of the lateral preoptic nucleus, passing rostrally,

run medially and dorsomedially through the diagonal band of Broca, where a few fibers are found to terminate, and enter the ventral part of the medial septal nucleus at anterior levels of the head of the caudate nucleus.

At anterior levels of the optic chiasma, the degenerated fibers coursing medially through the sublenticular gray join the medial forebrain bundle and run caudally in rather compact bundles to enter the lateral hypothalamic nucleus. Proceeding caudally, the degenerated fibers are distributed widely to this nucleus, but gradually they are confined to its ventral part. As the ventromedial hypothalamic nucleus appears, a few of them proceed ventromedially to enter its anterolateral part. Most of the degenerated fibers continue further caudally through the lateral hypothalamic nucleus, gradually decreasing in number. They disappear at the level of the anterior pole of the mammillary body.

At levels of the rostral third of the optic chiasma, scattered degenerated fibers passing dorsally from the sublenticular region enter the inferior thalamic peduncle. The majority of them course dorsocaudally through this fiber bundle to distribute in the posterior region of the dorsomedial thalamic nucleus, with a few fibers proceeding further dorsally to the ventral part of the lateral habenular nucleus. Within the dorsomedial nucleus the degeneration is confined to its medial (magnocellular) part. During their course through the inferior thalamic peduncle some of the degenerated fibers leave it to pass through the anteromedial nucleus and reach the ventral part of the parataenial nucleus. A few fibers appear to end in the paracentral nucleus at posterior levels of the optic chiasma.

The fibers entering the stria terminalis arise from the posterior part of the lesion and run caudally ventrolateral and lateral to the optic tract. They then curve dorsally along the tail of the caudate nucleus to lie dorsolateral to the thalamus. The degenerated fibers in the stria terminalis can be differentiated into a dorsomedial and a ventrolateral division. The former consists of fine, densely arranged fibers, while the latter is composed of medium-sized, rather scattered fibers. These two divisions together pass rostrally to reach the anterior commissural levels without giving off any fibers and divide into the preoptic (lateral) and supracommissural (medial) components. The preoptic component, derived from the ventrolateral division, courses ventrally to end largely in the bed nucleus of the stria terminalis dorsolateral to the posterior border of the anterior commissure, but some fibers proceed further ventralward lateral to the anterior commissure to end in the medial part of the lateral preoptic nucleus. The supracommissural component, a direct continuation of the

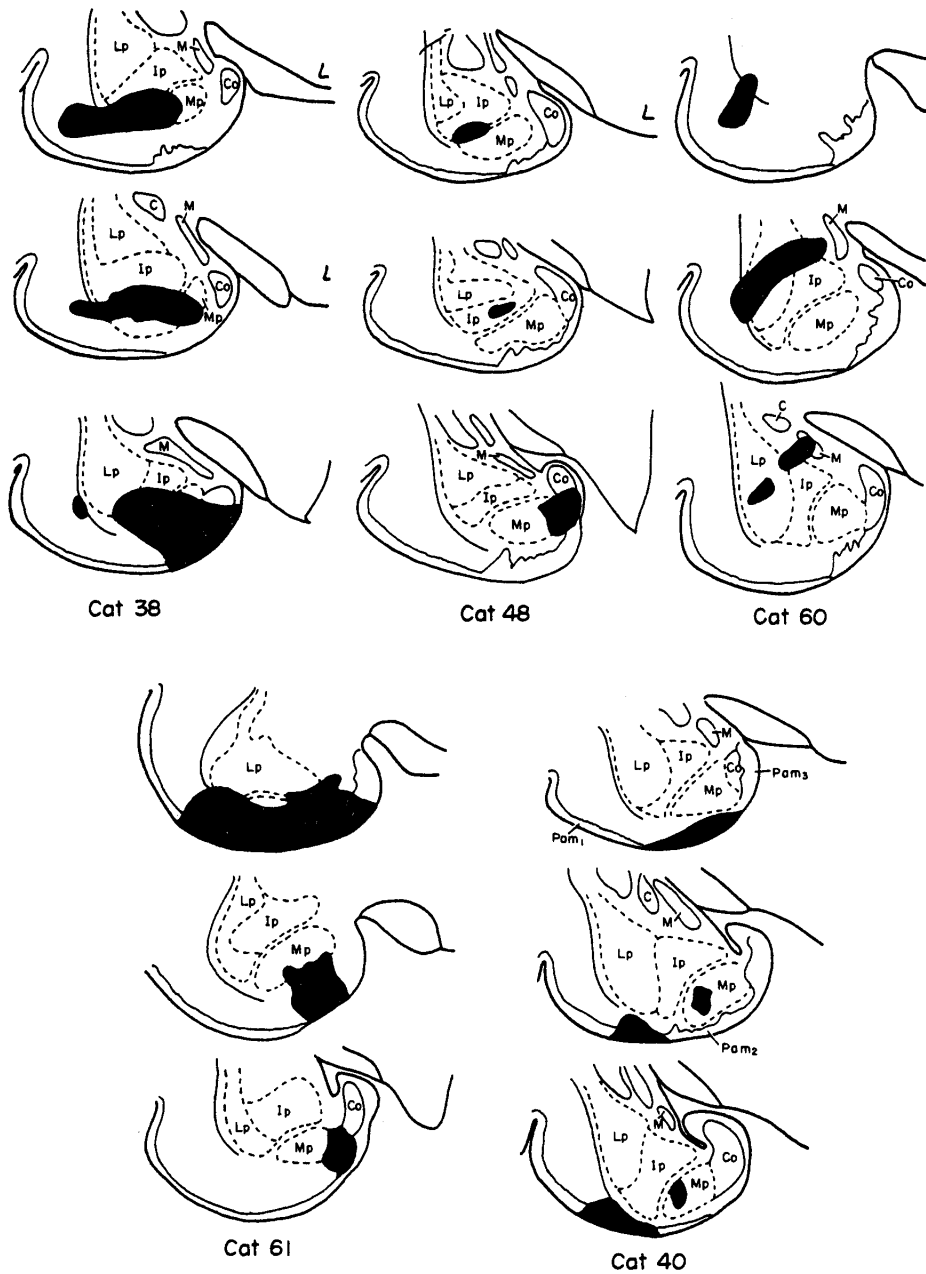


Fig. 1 Drawings of transverse sections showing the site and extent of lesions in the amygdaloid complex in each case. The lesion is indicated in solid black.

dorsomedial division, swings ventrocaudally in front of the anterior commissure to enter the medial preoptic nucleus, where some fibers terminate. Most of the degenerated fibers of the supracommissural component pass through this nucleus to reach the anterior hypothalamic nucleus, in which many fibers are found to terminate. However, some of them proceed further caudally to distribute in the ventromedial part of the lateral hypothalamic nucleus. During their course a few fibers turn ventrally to enter the ventromedial hypothalamic nucleus, where these fibers are intermingled with the fibers coming by way of the medial forebrain bundle.

Medium to coarser degenerated fibers arising in the lateral part of the lesion are found to join the external capsule and proceed dorsally to enter the posterior limb of the anterior commissure. Passing rostrally, they turn medially and cross in the dorsal portion of the anterior commissure. They can be traced as far as the sublenticular region of the opposite side, but their farther course cannot be traced. A few degenerated fibers are

#### *Abbreviations*

Aa, Anterior amygdaloid area	bundle
Ac, Nucleus accumbens	Lp, Lateral principal nucleus
Bca, Bed nucleus of anterior commissure	M, Medial nucleus
Bst, Bed nucleus of stria terminalis	Md, Dorsomedial thalamic nucleus
C, Central nucleus	MFB, Medial forebrain bundle
Ca, Anterior commissure	Mp, Medial principal nucleus
Cd, Head of caudate nucleus	Pam <sub>1</sub> , Lateral part of periamygdaloid cortex
Ch, Optic chiasma	Pam <sub>2</sub> , Intermediate part of periamygdaloid cortex
Ci, Internal capsule	Pam <sub>3</sub> , Medial part of periamygdaloid cortex
Cl, Claustrum	Pir, Piriform cortex
Co, Cortical nucleus	Pol, Lateral preoptic nucleus
Dg, Nucleus of diagonal band	Pom, Medial preoptic nucleus
F, Fornix	Pt, Parataenial nucleus
Ha, Anterior hypothalamic nucleus	Pu, Putamen
Hbl, Lateral habenular nucleus	Sm, Medial septal nucleus
Hl, Lateral hypothalamic nucleus	Sp, Posterior septal nucleus
Hvm, Ventromedial hypothalamic nucleus	ST, Stria terminalis
Ip, Intermediate principal nucleus	Tol, Olfactory tubercle
ITP, Inferior thalamic peduncle	Vm, Medial ventral nucleus
LAB, Longitudinal association	



found to enter the claustrum without coursing to the anterior commissure. Within the claustrum degenerated fibers are scattered in its medial part, but they cannot be seen at levels rostral to the septum.

A few degenerated fibers from the lesion take a direct dorsal course to distribute in the ventral and lateral part of the putamen at levels caudal to the anterior commissure.

Within the amygdaloid complex a large number of degenerated fibers are found in the lateral principal and central nuclei, which are not involved in the lesion, but scarcely any degeneration is discernible in the cortical and medial nuclei.

*Cat 48*

The lesion in this cat is situated for the most part in the intermediate principal nucleus of the left amygdaloid complex and involves the medial part of the periamygdaloid cortex and parts of the medial principal and cortical nuclei.

As compared with cat 38, the degenerated fibers in the longitudinal association bundle proper are relatively few in number, while those around the bundle are abundant. Passing rostrally, the degenerated fibers as a whole spread medially to reach the medial part of the lateral preoptic nucleus, where some fibers are found to terminate. Most of the degenerated fibers run rostrally through the lateral preoptic nucleus to distribute widely in the prepiriform area, with some fibers entering the medial part of the olfactory tubercle. At the middle level of the anterior commissure the degenerated fibers in the lateral preoptic nucleus course in two directions: dorsomedial and ventromedial. Some of the dorsomedially running fibers are directed to the bed nucleus of the anterior commissure, but the majority pass dorsally to spread dorsomedially to the nucleus accumbens and dorsolaterally to the ventromedial part of the head of the caudate nucleus at levels rostral to the anterior commissure. The ventromedially running fibers course rostrally to join the diagonal band of Broca. Most of them proceed dorsomedially to enter the ventral part of the medial septal nucleus at rostral levels of the head of the caudate nucleus, though some fibers are found to end in the nucleus of the diagonal band.

At levels of the optic chiasma the degenerated fibers joining the medial forebrain bundle course caudally through the lateral hypothalamic nucleus, sending some fibers to the lateral part of the anterior hypothalamic nucleus. At rostral levels the degenerated fibers are distributed widely in the lateral hypothalamic nucleus, but caudally they decrease in number and are limited to its ventral part. Very few fibers are found to enter the

ventromedial hypothalamic nucleus.

Some degenerated fibers enter the inferior thalamic peduncle to course caudodorsally and are distributed in the medial part of the dorsomedial thalamic nucleus at caudal levels of the mamillary body, as in cat 38. However, there are no fibers passing through the dorsomedial nucleus to the lateral habenular nucleus.

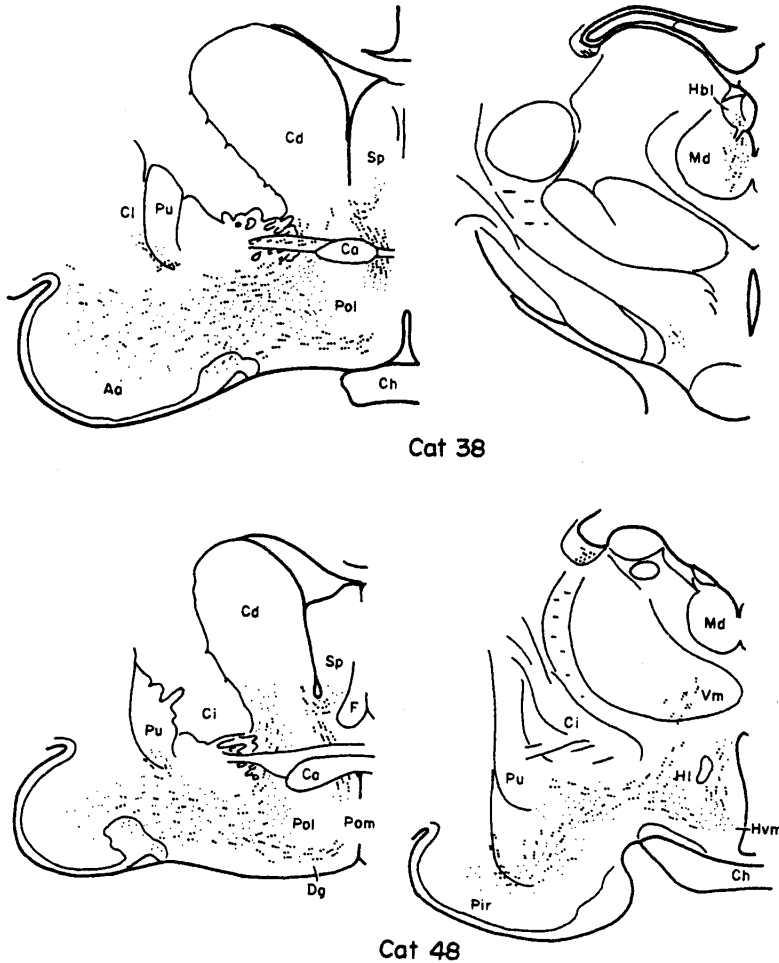


Fig. 2 Fiber degeneration observed in cats 38 and 48. Coarse dots indicate degenerating fibers of passage, fine stripples preterminal degeneration.

The degenerated fibers coursing through the stria terminalis arise in the posterior portion of the lesion, that is, the cortical nucleus and the medial part of the medial principal nucleus. They are relatively few in

number as compared with cat 38. The degenerated fibers run through the stria terminalis turning caudodorsally and then rostrally in association with the tail of the caudate nucleus to reach the level of the caudal border of the anterior commissure. At this level the degenerated fibers divide into the supracommissural and preoptic components. The preoptic component takes a ventral course just lateral to the anterior commissure to end in the bed nucleus of the anterior commissure and the medial part of the lateral preoptic nucleus. The supracommissural component, after sending some fibers to the posterior septal nucleus, runs ventromedially to turn caudally in front of the anterior commissure. It then passes ventromedial to the fornix through the medial preoptic nucleus, giving off in course fibers to this nucleus, and enters the anterior hypothalamic nucleus, where it disappears at the rostralmost level of the infundibulum. During its course a small number of degenerated fibers diverge from it to pass ventrolaterally to the ventromedial hypothalamic nucleus. In addition, very few fibers are seen running medially into the arcuate nucleus.

A small number of medium-sized fibers are seen running dorsally from the lesion to pass through the ventral part of the external capsule into the claustrum. In this case there are no fibers entering the anterior commissure.

As in cat 38, some fine and medium-sized degenerated fibers are directed dorsally from the lesion to the putamen and are scattered in the ventral and lateral part of the putamen at levels of the optic chiasma.

Within the amygdaloid complex degenerated preterminals are scattered in the intermediate principal, medial principal and central nuclei, but not in the cortical and medial nuclei. In the lateral part of the periamygdaloid cortex a few degenerated preterminals are found.

#### *Cat 60*

The lesion is placed in the lateral principal nucleus, involving the dorsalmost part of the intermediate principal nucleus and part of the medial nucleus and the lateral part of the periamygdaloid cortex.

The degenerated fibers forming the ventral amygdalofugal pathway are directed dorsally and dorsomedially. Most of them course through and along the longitudinal association bundle. In this cat fibers passing through this bundle are abundant, whereas those coursing along it are much sparser than those found in cat 48. Proceeding rostrally, the degenerated fibers of the longitudinal association system run medially and dorsomedially. At the level of the anterior border of the optic chiasma they divide into two distinct groups: medial and lateral. At about the

middle level of the anterior commissure the medial group of fibers extend shell-like mediolaterally ventral to the internal capsule. Passing rostrally, the majority of the fibers of this group run ventromedially to join the diagonal band of Broca and end in the medial septal nucleus at levels of the head of the caudate nucleus, giving off fibers to the nucleus of the diagonal band and the medial part of the lateral preoptic nucleus. On the other hand, a small number of fibers run dorsally from the medial group and are scattered in the ventral part of the head of the caudate nucleus and the lateral part of the posterior septal nucleus. At this level a few fibers are seen running medially through the ventral portion of the anterior commissure to the contralateral side.

The lateral group of fibers proceed rostrally to distribute largely in the anterior amygdaloid and prepiriform areas and partly in the lateral part of the olfactory tubercle.

The degenerated fibers joining the medial forebrain bundle are relatively few in number as compared with those of cats 38 and 48. Proceeding caudally, they take a medial course and distribute in the lateral hypothalamic nucleus. They decrease in number caudally and can be traced as far as the anteriormost level of the mamillary body. In this case, none appear to enter the ventromedial hypothalamic nucleus.

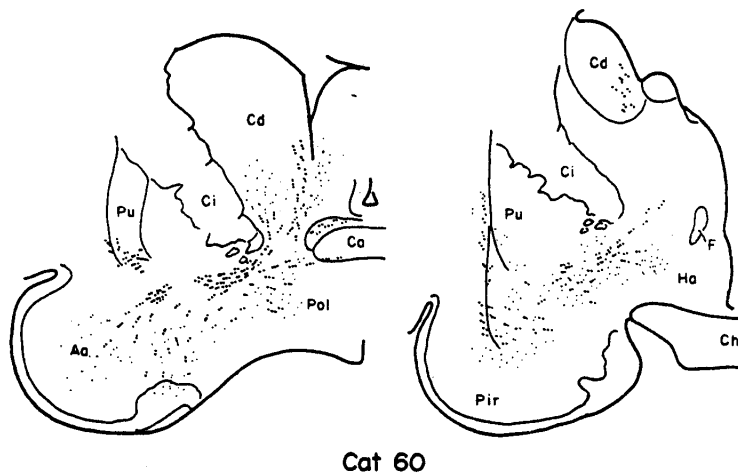


Fig. 3 Fiber degeneration in cat 60. Symbols as in Fig. 2.

Some degenerated fibers are seen coursing through the inferior thalamic peduncle to the dorsomedial thalamic nucleus as in cat 38, but are somewhat smaller in amount.

The degenerated fibers passing by way of the stria terminalis arise from the caudal part of the lesion, mainly from the medial nucleus. They are much smaller in amount than those in the previous cases. The degenerated fibers course through the stria terminalis closely associated to the tail of the caudate nucleus (ventrolateral division). It should be noted that no degenerated fibers are found in that portion of the stria terminalis which lies just beneath the ventricle (dorsomedial division). As the head of the caudate nucleus is reached, most of the degenerated fibers pass ventrally through its medial portion to end in the bed nucleus of the stria terminalis. A few fibers, however, terminate in the medial part of the lateral preoptic nucleus, where they are intermingled with the fibers coming by way of the longitudinal association bundle. In this case there are no fibers passing through the medial preoptic nucleus to the hypothalamic nuclei.

Also in this case many medium-sized degenerated fibers are seen coursing dorsally from the lateral part of the lesion along the lateral periphery of the amygdaloid complex. Some of them enter the posterior limb of the anterior commissure to cross to the contralateral side. Other fibers enter the external capsule to end in the claustrum.

*Cat 61*

The lesion attains its maximal size at middle levels of the optic chiasma, covering most of the medial principal nucleus, the medial and intermediate parts of the periamygdaloid cortex and the ventral small part of the intermediate principal nucleus. Caudally it decreases in size and is confined to the medial part of the medial principal nucleus, the ventromedial part of the cortical nucleus and the intermediate part of the periamygdaloid cortex.

The degenerated fibers forming the ventral amygdalofugal pathway are directed dorsally and then course rostrally ventral to the entopeduncular nucleus.

In this cat the degenerated fibers running through the longitudinal association bundle proper are few in number, while those around it are abundant. The degenerated fibers as a whole course rostrally, forming a single mass of diffusely scattered fibers. As the anterior commissure appears, a few of the medially situated fibers sweep dorsolaterally around the internal capsule to spread into the basal part of the head of the caudate nucleus. Most of the medial fibers, however, run more rostrally and terminate in the medial part of the lateral preoptic nucleus and the bed nucleus of the anterior commissure, with a few fibers joining the diagonal

band of Broca to end in the medial septal nucleus. On the other hand, the laterally situated fibers pass rostrally to distribute in the lateral part of the lateral preoptic nucleus, the dorsal part of the olfactory tubercle and the prepiriform area.

The degenerated fibers joining the medial forebrain bundle are distributed in the lateral hypothalamic nucleus. In the anterior part of this nucleus degenerated fibers are found throughout, but caudally decrease in number and disappear at the level of the anterior extremity of the mammillary body.

Some degenerated fibers are seen to enter the inferior thalamic peduncle from the sublenticular region at anterior levels of the optic chiasma. They run dorsocaudally to distribute in the medial part of the dorsomedial thalamic nucleus.

From the posterior portion of the lesion, that is, the medial part of the medial principal nucleus and the ventrolateral part of the cortical nucleus, a large number of degenerated fibers are found entering the stria terminalis and reach the anteriormost level of the anterior commissure. At this level a few fibers terminate in the lateral part of the bed nucleus of the stria terminalis, but the majority loop around the anterior commissure and then swing caudally to pass through the medial preoptic nucleus and enter the anterior hypothalamic nucleus. Within these nuclei a considerable number of fibers terminate, but the remaining fibers run further caudally through the anterior hypothalamic nucleus medial to the fornix and terminate in the dorsal part of the anterior half of the ventromedial hypothalamic nucleus.

#### *Cat 40*

In this cat the lesion destroys partly the intermediate and lateral parts of the left periamygdaloid cortex. At more caudal levels a localized small lesion is found in the medial principal nucleus.

Fine degenerated fibers, leaving the anterior part of the lesion in the intermediate part of the periamygdaloid cortex, run dorsomedially and enter the longitudinal association bundle. The fibers in this bundle are large in number, but a considerable number of fibers are scattered diffusely around it. As the anterior commissure appears, the degenerated fibers of the longitudinal association bundle form a transversely elongated mass of fibers, which does not divide into two groups, in contrast to cat 60. The medial portion of this mass, although projecting a few fibers to the basal part of the caudate nucleus, proceeds rostrally to distribute widely in the lateral preoptic nucleus. Passing more rostrally, it terminates

in the lateral preoptic nucleus, the bed nucleus of the anterior commissure and the nucleus of the diagonal band, with a few fibers running through the diagonal band to the medial septal nucleus. From the lateral portion of the mass, degenerated fibers are directed laterally to distribute in the olfactory tubercle and the prepiriform area.

Some degenerated fibers join the medial forebrain bundle to run caudally and distribute widely in the anterior part of the lateral hypothalamic nucleus. Very few of them pass medially and cross through the commissure of Meynert to the contralateral side, but their farther course cannot be followed.

The medium-sized degenerated fibers from the lateral part of the lesion enter the posterior limb of the anterior commissure to cross through the dorsal portion of the commissure to the contralateral side, although their ultimate distribution cannot be established.

From the posterior part of the lesion, involving the intermediate part of the periamygdaloid cortex and the medial principal nucleus, a few fibers run dorsomedially to enter the stria terminalis and pass around the thalamus until the anterior commissure level is attained. They then proceed ventrally to end largely in the bed nucleus of the stria terminalis and partly in the medial preoptic nucleus, but no fibers can be traced to the hypothalamus.

#### DISCUSSION

##### *Longitudinal association bundle*

In all our cases degenerated fibers are seen running through or along the longitudinal association bundle. In cats 40, 60 and 38 they are consistently found in the longitudinal association bundle proper. In cats 60 and 38 the lesions involve the intermediate principal nucleus, the lateral principal nucleus and the periamygdaloid cortex, particularly its lateral part. In cat 40, however, the lesion is localized roughly to the lateral and intermediate parts of the periamygdaloid cortex, and does not involve the lateral and intermediate principal nuclei. This indicates that the longitudinal association bundle receives fibers from the lateral and possibly from the intermediate part of the periamygdaloid cortex, in addition to the intermediate and lateral principal nuclei. The contribution of the intermediate principal nucleus to the longitudinal association bundle is also evidenced by the fact that degenerated fibers are found in this bundle in cat 48 where the lesion is almost confined to the intermediate principal nucleus. On the other hand, only very few fibers are seen in this bundle

in cat 61 with the lesion involving almost all of the medial principal nucleus and the medial and intermediate parts of periamygdaloid cortex. From this fact it may be said that scarcely any contribution to this bundle is made by the medial principal nucleus and the medial part of the periamygdaloid cortex. In all our cases scattered degenerated fibers are seen running forward along the longitudinal association bundle. They may originate widely from the amygdaloid complex, including the cortex of the piriform lobe.

It is generally accepted that the amygdaloid complex contributes fibers to the longitudinal association bundle. Fox (9), studying by means of the Marchi method in the rat, stated that the longitudinal association bundle arises in the large-celled basal amygdaloid nucleus (intermediate principal nucleus). HALL (14) studied the efferent connections of the amygdala in the cat and stated that the longitudinal association bundle originates not only in the basal nucleus but also in the lateral nucleus of the amygdaloid complex. She found that the contribution of the basal nucleus is considerably greater than that of the lateral, and the fibers from the lateral nucleus are more thinly myelinated. VALVERDE (29) agreed with the above-mentioned view that the bundle originates mainly in the basolateral nucleus. BAN and OMIKAI (4), using the Marchi method in the rabbit, stated that the longitudinal association bundle arises in the lateral part of the basal nucleus, the anterior part of the lateral nucleus and the periamygdaloid cortex. Our results agree roughly with those of BAN and OMIKAI.

According to our results, degenerated fibers coursing through or along the longitudinal association bundle are distributed to the anterior amygdaloid and the prepiriform areas, the lateral preoptic nucleus, the bed nucleus of the anterior commissure, the olfactory tubercle, the nucleus of the diagonal band of Broca, the nucleus accumbens and the medial and posterior septal nuclei. In addition, some degenerated fibers are seen to reach the basal part of the head of the caudate nucleus in cats 48, 60 and 61.

FOX (9) and HALL (14) stated that the longitudinal association bundle arising from the basal nucleus shows a partial division into lateral and medial components. According to HALL, the lateral component terminates in the lateral two-thirds of the preoptic region, the bed nucleus of the anterior commissure and the substantia innominata, while the medial component ends in the medial two-thirds of the preoptic region and the bed nucleus of the anterior commissure. In most of our cases where the longitudinal association bundle is severely degenerated (cats 40 and 38),



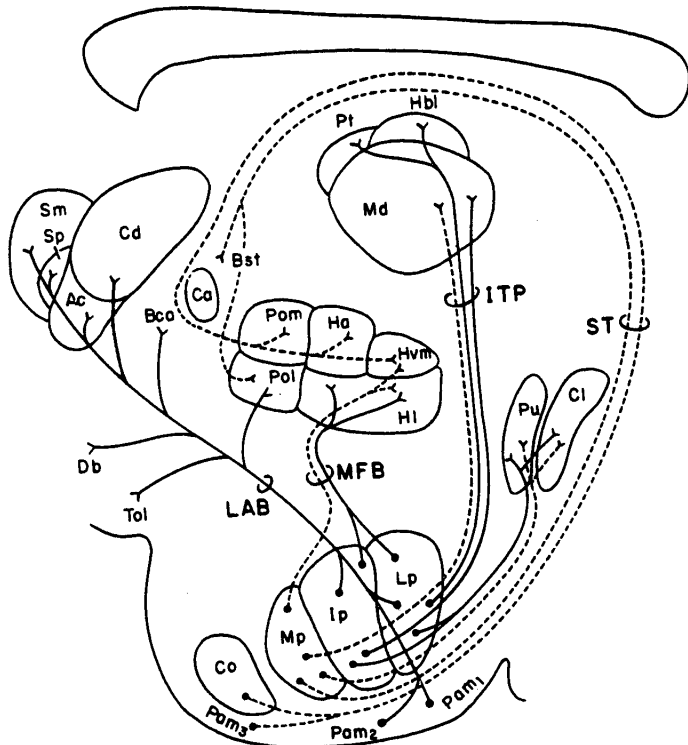


Fig. 4 Diagram showing the distribution of amygdalofugal fibers in the cat. Fibers from the lateral nuclear group of the amygdaloid complex are shown by solid lines; those from the medial nuclear group by dotted lines.

the longitudinal association bundle shows scarcely any division. In cat 60, however, it divides clearly into two components. The medial component terminates in the ventromedial part of the head of the caudate nucleus, the lateral part of the posterior septal nucleus, the lateral preoptic area, the nucleus of the diagonal band of Broca and the medial septal nucleus, while the lateral component ends in the anterior amygdaloid area, the prepiriform area and the lateral part of the olfactory tubercle.

On the basis of observations made on normal preparations, JOHNSTON (15) and Fox (8) stated that the longitudinal association bundle contributes fibers to the medial forebrain bundle. Later papers, including the experimental study of Fox (9), denied such a contribution. Our results are also negative.

#### *Medial forebrain bundle*

In all our cases with lesions of the amygdaloid complex, the degene-

rated fibers coursing through the medial forebrain bundle are distributed to the hypothalamus. They are widely distributed to the lateral hypothalamic nucleus. Proceeding caudally, they gradually decrease in number to disappear at levels of the mamillary body. The lateral principal, intermediate principal and medial principal nuclei are regarded as the probable sources of the amygdalofugal fibers to the medial forebrain bundle. In addition, a few fibers are seen running medially to reach the ventromedial hypothalamic nucleus in cats 38, 48, 61 and 40, where the medial principal nucleus is involved in the lesion. In cat 40 the lesion involves only the medial principal nucleus and the periamygdaloid cortex. These facts indicate that the ventromedial hypothalamic nucleus receives fibers largely, if not exclusively, from the medial principal nucleus.

HALL (14) stated that the diffuse fibers from the lateral nucleus course directly medially inferior to the ansa lenticularis to join the medial forebrain bundle and are distributed throughout the lateral hypothalamus. VALVERDE (29) designated such a group of fibers the medial amygdalo-hypothalamic pathway and considered it to originate largely from the area amygdaloidea anterior and the medial part of the central nucleus. NAUTA (22) described the ventral amygdalofugal fibers coursing to the lateral preoptic and hypothalamic regions. These fibers terminate diffusely among cell groups scattered between the longitudinal fibers of the medial forebrain bundle. Only a few of them accompany the bundle caudalward to distribute in the lateral hypothalamus at infundibular levels or farther caudally. FOX (9), BAN and OMUKAI (4), and ADEY and MEYER (1) did not describe the amygdalofugal fibers joining the medial forebrain bundle.

#### *Inferior thalamic peduncle*

Some fibers from the amygdaloid complex course dorsally into the dorsomedial thalamic nucleus by way of the inferior thalamic peduncle. They are distributed in the medial part of the dorsomedial nucleus at its caudal levels in all our cases. Some of them are found to extend farther dorsally to reach the lateral habenular nucleus and the parataenial nucleus in cats 38 and 60, where the lesions involve more or less the lateral principal nucleus. These data suggest that the amygdalofugal fibers to the dorsomedial nucleus have a relatively widespread origin from the amygdaloid complex, and that those to the lateral habenular and parataenial nuclei arise from the lateral principal nucleus.

Based on the Marchi experiments in the monkey, FOX (10) first described the amygdalofugal fibers coursing directly to the dorsomedial nucleus by way of the inferior thalamic peduncle. NAUTA (22) confirmed

FOX's observations and found these fibers to terminate in the medial, magnocellular part of the dorsomedial nucleus. He could not identify the contributing amygdaloid nuclei with certainty, but considered the basal and lateral nuclei to be the most likely sources of origin of the amygdalothalamic connections. HALL (14), however, was not able to demonstrate direct amygdalothalamic fibers following lesions in the basal and lateral nuclei in the cat. VALVERDE (28, 29) followed the amygdalothalamic fibers of the cat to the posteromedial part of the dorsomedial nucleus. According to him, these fibers may arise in the area amygdaloidea anterior and little, if any, contribution can be expected from the remaining amygdaloid nuclei. On the other hand, NAUTA found some sparse termination of amygdalofugal fibers in the rostral midline region and the paracentral intralaminar nucleus, in addition to the dorsomedial nucleus. However, such terminations cannot be observed in our experiments, except for cat 38 where a few fibers appear to terminate in the paracentral nucleus.

*Stria terminalis*

In cats 38, 48 and 61 the amygdalofugal fibers forming the stria terminalis are distributed in the bed nucleus of the stria terminalis and the lateral preoptic nucleus (preoptic component), as well as the medial preoptic area, the anterior hypothalamic nucleus and the ventromedial hypothalamic nucleus (supracommissural component). In cats 60 and 40, where the cortical nucleus and the medial part of the periamygdaloid cortex are intact, the degenerated fibers are relatively few in the stria terminalis and end mostly in the bed nucleus of the stria terminalis and partly in the lateral preoptic nucleus. This indicates that the cortical nucleus, particularly its caudal part, and possibly the medial part of the periamygdaloid cortex are the main sources of the stria terminalis fibers ending in the hypothalamic region (supracommissural component). It is evident from the above cases that the fibers from the medial principal nucleus and the medial nucleus enter the stria terminalis, but do not extend to the hypothalamic region (preoptic component). The intermediate principal nucleus does not appear to contribute fibers to the stria terminalis. In cat 48 no degenerated fibers are found to enter the stria from the anterior portion of the lesion lying largely in the intermediate principal nucleus. Although a few degenerated fibers are seen in the stria terminalis in cat 60, they arise from the posterior portion of the lesion involving the medial principal and cortical nuclei. There is no evidence that the lateral principal nucleus contributes fibers to the stria terminalis.

There has been no general agreement as to the exact origin and termi-

nation of the stria terminalis fibers from the amygdaloid complex. FOX (9) stated that a large portion of the stria terminalis originates in the basal amygdaloid nucleus, particularly its caudal end, and projects to the septum, the preoptic region and the vicinity of the paraventricular nucleus of the hypothalamus. He failed to trace degeneration in the stria after lesions in the lateral nucleus of the amygdala. According to observations of ADEY and MEYER (1) in the monkey, the stria terminalis fibers arise mainly in the basal amygdaloid nucleus, and degeneration is found principally in the hypothalamic and supracommissural components of the stria, which appear to be more closely related to the posterior basolateral parts of the amygdaloid complex than to the corticomедial group. HALL (14) stated that the basal nucleus in the cat contributes fibers to the stria terminalis and projects fibers to the bed nucleus of the stria terminalis and the anterior commissure. NAUTA (22) described the stria terminalis in the monkey as originating mostly in the caudal half of the amygdaloid complex. Fibers arising most rostrally in the complex appear to terminate largely in the bed nucleus of the stria terminalis. Other fibers of more caudal region form a prominent preoptico-hypothalamic component distributing fibers to the medial preoptic nucleus, the anterior hypothalamic nucleus and the region of the nucleus supraopticus diffusus. Our results reveal that the supracommissural component corresponding to NAUTA'S preoptico-hypothalamic component originates from the cortical nucleus, particularly its caudal part. BAN and OMUKAI (4) stated that the supracommissural component originates in the medial nucleus, the cortical nucleus and the small-celled medial part of the basal nucleus, and terminates in the bed nucleus of the stria terminalis and the anterior commissure, the septal area and the rostral part of the ventromedial hypothalamic nucleus, while the preoptic component, arising in the large-celled lateral part of the basal nucleus and the periamygdaloid cortex, terminates in the lateral preoptic area.

Most of the authors claimed that the stria terminalis fibers are distributed to the ventromedial hypothalamic nucleus (ADEY and MEYER (1), BAN and OMUKAI (4), HALL (14)), while a few workers denied such a connection (NAUTA (22), VALVERDE (29)). According to our results, the ventromedial hypothalamic nucleus receives amygdalofugal fibers by way of both the medial forebrain bundle and the stria terminalis.

#### *Anterior commissure*

Since JOHNSTON'S (15) description in normal bat material, the commissural component of the stria terminalis has been described by a number

of authors. NAUTA (22), studying experimentally in the monkey, followed a few fibers of the stria terminalis across the midline in the dorsal stratum of the anterior commissure, but could not determine their termination. However, no stria terminalis fibers are seen to cross in the anterior commissure in all of our experiments. In studies of normal material YOUNG (30) found that the posterior limb of the anterior commissure serves to interconnect the amygdaloid nuclei, particularly the lateral, of the two sides. In cats 40, 60 and 38 of our cases also some fibers are seen running dorsally from the lesion to join the posterior limb of the anterior commissure and can be traced to the sublenticular gray of the opposite side. It is, however, difficult to determine whether or not they arise in the amygdaloid complex. In agreement with observations of HALL (14) a few fibers of the longitudinal association bundle course dorsomedially to cross in the anterior limb of the anterior commissure to the contralateral side. They may arise in the intermediate principal and lateral principal nuclei.

*Other amygdalofugal pathways*

NAUTA (22) found degenerated fibers in the claustrum and the lateral zone of the putamen following lesions in the amygdaloid complex in the monkey. According to VALVERDE (29), some fine degenerated fibers are seen to end in the posterior pole of the claustrum in the cat. Coarse fibers are also observed in the putamen, but they are probably fibers interrupted by the needle track. In addition, the electro-physiological study of ADEY *et al.* (2) suggested the correlation between the amygdaloid complex and the globus pallidus. In all our cases some degenerated fibers can be traced to the ventralmost part of the putamen and the medial part of the claustrum.

KOIKEGANI *et al.* (19) stated that the stimulation of the medial principal nucleus and cortical nucleus (medial nuclear group) gives rise to sympathetic responses, while the stimulation of the lateral nuclear group produces parasympathetic or no responses. These results are considered to be closely related to the fiber connections of the amygdaloid complex. It is of interest to note that the medial nuclear group tends to send fibers by way of the stria terminalis to the medial hypothalamus (B-sympathetic zone of KUROTSU), while the lateral nuclear group contributes fibers to the medial forebrain bundle and projects to the lateral hypothalamus (C-parasympathetic zone of KUROTSU).

SUMMARY

The amygdalofugal fibers were studied in the cat with the silver

method of NAUTA-GYGAX.

1. The amygdalofugal fibers are distributed by way of the stria terminalis, the longitudinal association bundle, the inferior thalamic peduncle, and the medial forebrain bundle.

2. The amygdalofugal fibers running through the longitudinal association bundle arise in the lateral principal, intermediate principal nuclei and the lateral and possibly intermediate parts of the periamygdaloid cortex, and terminate in the lateral preoptic nucleus, the bed nucleus of the anterior commissure, the olfactory tubercle, the nucleus of the diagonal band of Broca, the nucleus accumbens, the medial and posterior septal nuclei and the basal part of the head of the caudate nucleus. In addition, there are scattered fibers coursing along the longitudinal association bundle proper. These fibers may have a widespread origin from the amygdaloid complex. The longitudinal association bundle contributes no fibers to the medial forebrain bundle.

3. The fibers, originating from the lateral principal, intermediate principal and medial principal nuclei, join the medial forebrain bundle to distribute widely in the lateral hypothalamic nucleus. A few fibers are seen to reach the ventromedial hypothalamic nucleus, and are considered to arise in the medial principal nucleus.

4. By way of the inferior thalamic peduncle some fibers from the amygdaloid complex course dorsally into the medial part of the dorso-medial thalamic nucleus at its caudal levels. They may arise widely from the amygdaloid complex. A few of them extend farther dorsally to reach the lateral habenular nucleus and the parataenial nucleus. They probably originate from the lateral principal nucleus.

5. The fibers forming the stria terminalis originate from the medial principal nucleus, the medial nucleus, the periamygdaloid cortex and the cortical nucleus, and are distributed in the bed nucleus of the stria terminalis and the lateral preoptic nucleus (preoptic component), as well as the medial preoptic nucleus, the anterior hypothalamic nucleus and the ventromedial hypothalamic nucleus (supracommissural component). The cortical nucleus, particularly its caudal part, and possibly the medial part of the periamygdaloid cortex are regarded as the main sources of the stria terminalis fibers ending in the hypothalamic region. The intermediate principal and lateral principal nuclei do not appear to contribute fibers to the stria terminalis.

6. The ventromedial hypothalamic nucleus receives amygdalofugal fibers both from the medial principal nucleus by way of the medial forebrain bundle, and from the cortical nucleus via the stria terminalis.

7. In addition to intrinsic internuclear fibers within the amygdaloid complex, some of the fibers from the complex are distributed to the ventralmost part of the putamen, the medial part of the claustrum, the periamygdaloid cortex, the prepiriform area and the anterior amygdaloid area, but do not reach the hippocampus.

## ACKNOWLEDGEMENT

We wish to express our hearty thanks to Professor K. NIIMI, Okayama University Medical School, and Professor T. ABURAYA, Tokushima University Medical School, for their kind guidance and helpful suggestions throughout this investigation.

## REFERENCES

1. ADEY, W. R. and MEYER, M.: Hippocampal and hypothalamic connexions of the temporal lobe in the monkey. *Brain* **75**, 358, 1952
2. ADEY, W. R., BUCHWALD, N. A. and LINDSLEY, D. F.: Amygdaloid, pallidal and peripheral influences on mesencephalic unit firing patterns with reference to mechanisms of tremor. *EEG Clin. Neurophysiol.* **12**, 21, 1960
3. ADEY, W. R., RUDOLPH, A. F., HINE, I. F. and HARRIT, N. J.: Gleys staining of the monkey hypothalamus: a critical appraisal of normal and experimental material. *J. Anat.* **92**, 219, 1958
4. BAN, T. and OMUKAI, F.: Experimental studies on the fiber connections of the amygdaloid nuclei in the rabbit. *J. Comp. Neur.* **113**, 245, 1959
5. BERKELBACH van der SPRENKEL, H.: Stria terminalis and amygdala in the brain of the opossum (*Didelphis virginiana*). *J. Comp. Neur.* **42**, 211, 1926
6. COWAN, W. M., RAISMAN, G. and POWELL, T. P. S.: The connexions of the amygdala. *J. Neur. Neurosurg.* **28**, 137, 1965
7. CROSBY, E. C. and HUMPHREY, T.: Studies of the vertebrate telencephalon. II. The nuclear pattern of the anterior olfactory nucleus, tuberculum olfactorium and the amygdaloid complex in adult man. *J. Comp. Neur.* **74**, 309, 1941
8. FOX, C. A.: Certain basal telencephalic centers in the cat. *J. Comp. Neur.* **72**, 1, 1940
9. FOX, C. A.: The stria terminalis, longitudinal association bundle and precommissural fornix fibers in the cat. *J. Comp. Neur.* **79**, 277, 1943
10. FOX, C. A.: Amygdalo-thalamic connections in *Macaca mulatta*. *Anat. Rec.* **103**, 537, 1949
11. FUKUCHI, S.: Comparative-anatomical studies on the amygdaloid complex in mammals, especially in ungulata. *Fol. psychiat. jap.* **5**, 241, 1952
12. GLOOR, P.: Electrophysiological studies on the connections of the amygdaloid nucleus in the cat. I and II. *EEG. Clin. Neurophysiol.* **7**, 223, 1955
13. GLOOR, P.: Amygdala. Handbook of Physiology. Section I: Neurophysiology Vol. 2, Williams & Wilkins, Baltimore, 1959
14. HALL, E. A.: Efferent connections of the basal and lateral nuclei of the amygdala in the cat. *Amer. J. Anat.* **113**, 139, 1963
15. JOHNSTON, J. B.: The evolution of the forebrain. *J. Comp. Neur.* **35**, 337, 1923
16. KARIBE, H.: Comparative anatomical studies on the amygdaloid complex, especially in carnivora. *Acta Inst. Anat. Niigata* **50**, 99, 1961 (in Japanese)
17. KINGLER, J. and GLOOM, P.: The connections of the amygdala and of the anterior

- temporal cortex in the human brain. *J. Comp. Neur.* **115**, 333, 1960
18. KOIKEGAMI, H.: Amygdala and other related limbic structures: Experimental studies on the anatomy and function. I. Anatomical researches with some neurophysiological observations. *Acta med. biol.* **10**, 161, 1963
  19. KOIKEGAMI, H., FUSE, S., YOKOYAMA, T., WATANABE, T. and WATANABE, H.: Contributions to the comparative anatomy of the amygdaloid nuclei of mammals with some experiments of their destruction or stimulation. *Fol. psychiat. jap.* **8**, 336, 1955
  20. KUROTSU, T.: Studies on the autonomic center. *Brain-Researches* **3**, 39, 1949 (in Japanese)
  21. LAUER, E. W.: The nuclear pattern and fiber connections of certain basal telencephalic centers in the macaque. *J. Comp. Neur.* **82**, 215, 1945
  22. NAUTA, W. J. H.: Fiber degeneration following lesions of the amygdaloid complex in the monkey. *J. Anat.* **95**, 515, 1961
  23. NAUTA, W. J. H.: Neural association of the amygdaloid complex in the monkey. *Brain* **85**, 505, 1962
  24. NAUTA, W. J. H. and GYGAX, P. A.: Silver impregnation of degenerating axons in the central nervous system: a modified technic. *Stain Techn.* **29**, 91, 1954
  25. POWELL, T. P. S., COWAN, W. M. and RAISMAN, G.: Cifactory relationships of the diencephalon. *Nature* **199**, 710, 1963
  26. SNIDER, R. S. and NIEMER, W. T.: A Stereotaxic Atlas of the Cat Brain. Univ. of Chicago Press, Chicago, 1961
  27. TAKAHASHI, K.: Experimental studies on the periamygdaloid cortex. *Niigata Igakkai Zasshi* **66**, 660, 1952 (in Japanese)
  28. VALVERDE, F.: Amygdaloid Projection Field. *Progress in Brain Research* Vol. **3**, 20, 1963
  29. VALVERDE, F.: Studies on the Piriform Lobe. Harvard Univ. Press, Cambridge, 1965
  30. YOUNG, M. W.: The nuclear pattern and fiber connections of the noncortical centers of the telencephalon in the rabbit. *J. Comp. Neur.* **65**, 295, 1963