Acta Medica Okayama

Volume 45, *Issue* 3 1991 *Article* 6

JUNE 1991

Immunohistochemical characterization of the lymphocyte and the immunoglobulin-containing cell in the epithelium and the lamina propria of normal human intestines.

Kazuhiro Matsueda* Gotaro Yamada† Takao Tsuji‡

*Okayama University,
†Okayama University,
‡Okayama University,

Copyright ©1999 OKAYAMA UNIVERSITY MEDICAL SCHOOL. All rights reserved.

Immunohistochemical characterization of the lymphocyte and the immunoglobulin-containing cell in the epithelium and the lamina propria of normal human intestines.*

Kazuhiro Matsueda, Gotaro Yamada, and Takao Tsuji

Abstract

In order to clarify difference of the mucosal immunity in various sites of normal large and small intestines, we studied the population of lymphocyte subsets and immunoglobulin (Ig)-containing cells in situ in biopsy specimens taken from various sites (ascending colon, sigmoid colon and rectum) of the large intestine and from the duodenum using an immunohistochemical method. Monoclonal antibodies against pan-T (Leu 1), cytotoxic/suppressor T (Leu2a), helper/inducer T (Leu3a), suppressor T (Leu15) and natural killer/K (Leu7) cells, and polyclonal antibodies to human IgG, IgA and IgM were used. In the duodenum, intraepithelial lymphocytes (IELs) were more prominent than in the large intestine. Immunoelectron microscopic observation revealed that some Leu2a+ IELs possessed pseudopods extending into intestinal epithelial cells, indicating that some IELs belong to the cytotoxic T cell subset. Leu7+ IELs were scarcely observed and Leu7+/Leu1+ ratio was higher in the large intestine than in the duodenum. Furthermore, the number of Leu7+ cells were more in the distal than the proximal colon. In the lamina propria Ig-containing cells tended to be fewer in the rectum than in the duodenum and the proximal colon. Our findings may suggest the variation of local immune responses and the difference of assigned immunological functions among the various sites of the intestines.

KEYWORDS: cytotoxic T cell subsets, anti-Leu7(NK/K cells), immunoglobulin-containing cells, intestinal mucosa

---

*PMID: 1891975 [PubMed - indexed for MEDLINE]
Copyright (C) OKAYAMA UNIVERSITY MEDICAL SCHOOL

Acta Med Okayama 45 (3) 161-169 (1991)

Immunohistochemical Characterization of the Lymphocyte and the Immunoglobulin-Containing Cell in the Epithelium and the Lamina Propria of Normal Human Intestines

Kazuhiro Matsueda*, Gotaro Yamada and Takao Tsuji

First Department of Internal Medicine, Okayama University Medical School, Okayama 700, Japan

In order to clarify difference of the mucosal immunity in various sites of normal large and small intestines, we studied the population of lymphocyte subsets and immunoglobulin (Ig)-containing cells *in situ* in biopsy specimens taken from various sites (ascending colon, sigmoid colon and rectum) of the large intestine and from the duodenum using an immunohistochemical method. Monoclonal antibodies against pan-T (Leu 1), cytotoxic/suppressor T (Leu2a), helper/inducer T (Leu3a), suppressor T (Leu15) and natural killer/K (Leu7) cells, and polyclonal antibodies to human IgG, IgA and IgM were used. In the duodenum, intraepithelial lymphocytes (IELs) were more prominent than in the large intestine. Immunoelectron microscopic observation revealed that some Leu2a$^+$ IELs possessed pseudopods extending into intestinal epithelial cells, indicating that some IELs belong to the cytotoxic T cell subset. Leu7$^+$ IELs were scarcely observed and Leu7$^+$/Leu1$^+$ ratio was higher in the large intestine than in the duodenum. Furthermore, the number of Leu7$^+$ cells were more in the distal than the proximal colon. In the lamina propria Ig-containing cells tended to be fewer in the rectum than in the duodenum and the proximal colon. Our findings may suggest the variation of local immune responses and the difference of assigned immunological functions among the various sites of the intestines.

Key words : **cytotoxic T cell, T cell subsets, anti-Leu7 (NK/K cells), immunoglobulin-containing cells, intestinal mucosa**

The incidence of large intestinal diseases such as colorectal cancer, Crohn's disease (CD) and ulcerative colitis (UC) has been higher in Europe and in the USA than in Japan. Recently, these diseases have been gradually increasing in Japan (1, 2). In these large intestinal diseases, there are apparent difference of common sites of the lesion; that is, the site of colorectal cancer is in the rectum and sigmoid colon, UC in the rectum, and CD in the terminal ileum and ascending colon, respectively. Many investigators have reported on immunological abnormalities in the intestinal mucosa in these diseases (3-8). Since various differences (*ie*, nerves and vessel supplies, thickness of the mucosa (9), and components of the mucus in the goblet cells (10) are known between the proximal and the distal colon, the immunological function could differ at various sites

* To whom correspondence should be addressed.

Produced by The Berkeley Electronic Press, 1991

in the large intestine. These difference could contribute to the distribution of the lesions of these large intentinal diseases.

To clarify whether the immunity differs at various sites of the normal intestinal mucosa, we characterized the lymphocytes and the immunoglobulin (Ig)-containing cells in the epithelium and the lamina propria of normal human intestines *in situ* using an immunohistochemical method.

Materials and Methods

Ten patients (6 males and 4 females: the large intestine), and 8 patients (5 males and 3 females: the small intestine) were studied. The age of the patients ranged from 34 to 82 years (mean 55.1 ± 14.8 years) and from 42 to 65 years (mean 54.3 ± 7.3 years), respectively. These patients underwent colonoscopy, or upper gastrointestinal endoscopy because of suspected colorectal polyps of gastric ulcers. None of the patients revealed evidence of apparent diseases, and no medication had been administered. The specimens were obtained from three sites (ascending colon, sigmoid colon and rectum) in the large intestine, and one site (second portion of duodenum) in the small intestine by endoscopic biopsy. The specimens were obtained from the endoscopically normal appearing mucosa and confirmed to be normal histologically.

Antibodies. Following murine monoclonal anibodies to various subpopulations of human lymphocytes (Leu series, Becton Dickinson Monoclonal Center Inc. Sunnyvale, CA) were used: antibody to pan T cell antigen (Leu1), to cytotoxic/suppressor T cell antigen (Leu2a), to helper/inducer T cell antigen (Leu3a), to suppressor T cell antigen (Leu15), and to natural killer/K cells antigen (Leu7). Fab' fragments of rabbit antibody to mouse immunoglobulins (absorbed by human immunoglobulins) (DAPOPATTS, Copenhagen, Denmark) were conjugated with horseradish peroxidase (HRP) (Sigma Chemical Co., St. Louis, Mo, type 4) according to the method of Nakane *et al* (11). HRP-labeled rabbit Fab' of immunoglobulin G to human IgA (Hoechist Co.), human IgM (DAKOPATTS) and human IgG (Hoechist Co.) were prepared in the same way.

Immunocytochemistry. The tissue biopsies were fixed in a periodate-lysine-paraformaldehyde (PLP) solution (12–16). Surface antigens of infiltrating lymphocytes in the tissue were detected by an indirect immunocytochemical method (14–16). Cryostat sections (6μm) of the fixed tissue specimens were pretreated with periodic acid and sodium borohydride in order to inactivate endogenous tissue peroxidase (17). The sections were incubated sequentially with each of the monoclonal antibodies overnight, and with the HRP-labeled rabbit Fab' anti-mouse immunoglobulins for 4 h. For the detection of Ig-containing cells, a direct immunocytochemical method was used. The sections were incubated with HRP-labeled Fab' of anti-IgA, anti-IgM or anti-IgG for 15 min. Then the sections were reacted with a diaminobenzidine (DAB) solution containing hydrogen peroxide in addition of 0.01 M sodium azide (13) for 10 min, counterstained with methyl green, dehydrated, and mounted.

For immunoelectron microscopy, cryostat sections were reacted with the antibodies in the same way as in the light microscopic study. The sections were fixed with 2 % glutaraldehyde, and reacted sequentially with DAB solution and DAB solution containing hydrogen peroxide, dehydrated, embedded in Epon-Araldite, and ultrathin-sections were observed without counterstaining under a Hitachi-700H electron microscope.

Numbers of positive cells were counted for each mm square of the lamina propria, and per thousand epithelial cells in the epithelium in serial sections. Positive cells in the lymph follicle were excluded from the enumeration.

Statistical analysis. The Student's *t* test was used for the statistical analysis.

Results

Intraepithelial Cells

Lymphocytes. In the duodenum, numbers of T cells and lymphocyte subsets were significantly higher (about 14 times) than in the large intestine. The intraepithelial lymphocytes (IELs) were mostly $Leu1^+$ $Leu2a^+$ $Leu15^-$ (Fig. 1a, b, c). The number of $Leu2a^+$ cells wes 214 ± 48, whereas $Leu15^+$ cells were 20 ± 8. $Leu7^+$ cells were scarcely observed. In the large intestine, most $Leu1^+$ $Leu2a^+$ IELs were also $Leu15^-$ (Fig. 1d, e, f). The number of $Leu2a^+$ (Fig. 2a) cells was 13 ± 7, whereas $Leu15^+$ cells 3 ± 3. $Leu7/Leu1^+$ ratio was significantly higher in the large intestine than in the duodenum. In the large intestine, $Leu7^+$ cells (Fig. 2b) were more prominent in the distal than the proximal colon. The

number of Leu7$^+$ cells was 4 ± 6 in the ascending colon, 11 ± 7 in the sigmoid colon, and 12 ± 9 in the rectum, respectively. The population of the T cell subsets did not differ significantly among the various sites of the large intestine (Table 1).

By electron microscopy, most of IELs were specifically stained by anti-Leu2a, but not by anti-Leu15. They were observed near the basal portion of the epithelial cells (Fig. 3a). Small pseudopods projecting from the surface of some Leu2a$^+$ cells extended into epithelial cells (Fig. 3b). Most of Leu2a$^+$ cells had round or oval nuclei (Fig. 3c).

Ig-containing cells. In the epithelium, Ig-containing cells were observed neither in the large intestine nor in the small intestine.

Cells in the Lamina Propria

Lyphocyte subsets. In the lamina propria, many Leu1$^+$ cells were observed both in the duodenum and the large intestine (Fig. 1a, d). Leu3a$^+$ cells dominated over Leu2a$^+$ cells, whereas Leu7$^+$ cells were few.

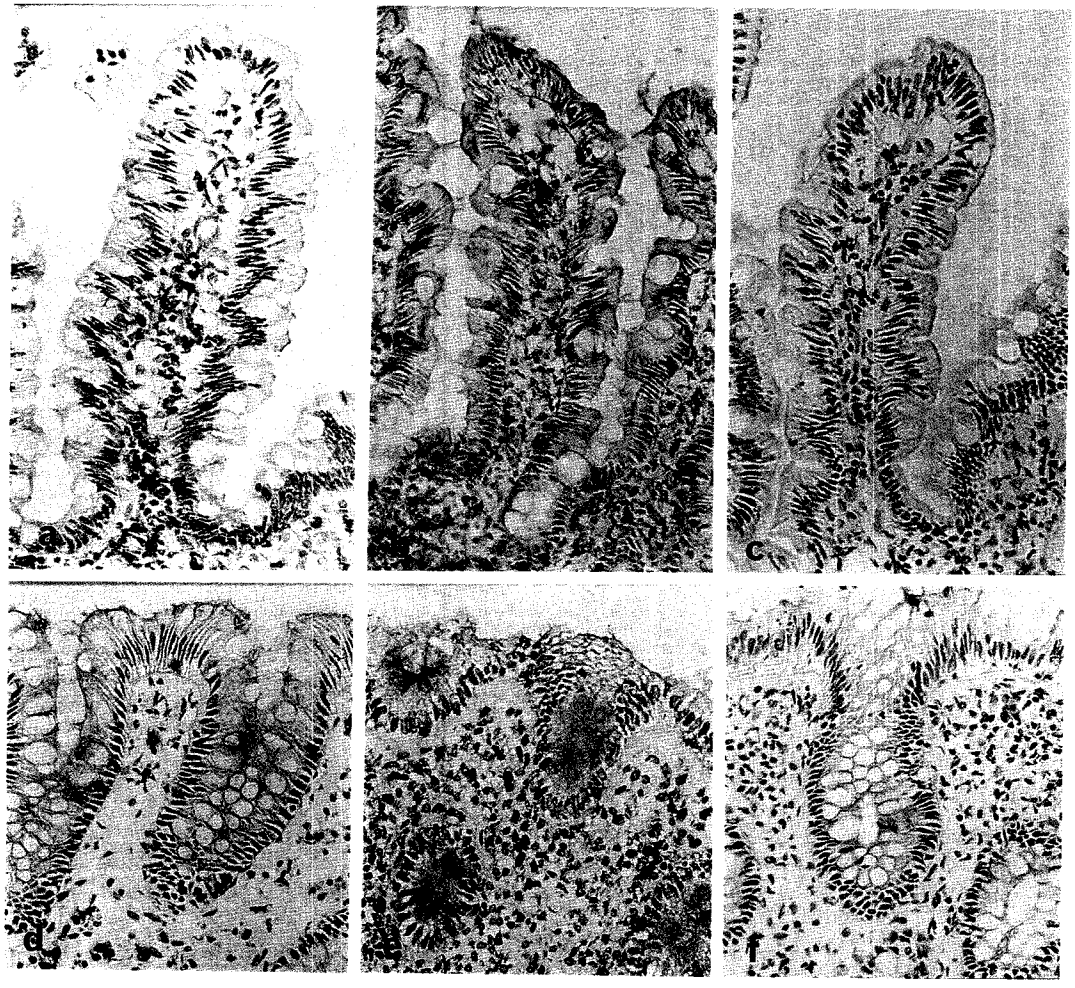

Fig. 1 Immunocytochemical staining of Leu1$^+$ (a), Leu2a$^+$ (b) and Leu15$^+$ (c) cells in the duodenum, and Leu1$^+$ (d), Leu2a$^+$ (e) and Leu15$^+$ (f) cells in the sigmoid colon (× 200). The number of Leu1$^+$ cells are significantly higher in the duodenum than in the sigmoid colon. IELs are mostly Leu1$^+$ Leu2a$^+$ Leu15$^-$. In the lamina propria, many Leu1$^+$ cells are observed.

In comparison of the large intestine with the duodenum, numbers of Leu1$^+$ cells and Leu3a$^+$ cells were not significantly different. In contrast, Leu2a$^+$ cells were fewer in the sigmoid colon and the rectum than in the duodenum and the proximal colon. As a result, Leu3a$^+$/Leu2a$^+$ratio tended to be higher in the sigmoid colon and the rectum than in the duodenum and the proximal colon. About half of Leu2a$^+$ cells were Leu15$^+$ cells in the large intestine. Leu7$^+$ cells were also significantly fewer in the large intestine than the duodenuum. Among the three sites of the large intestine, numbers of T cell subsets and Leu7$^+$ cells did not show significant differences (Table 2).

Ig-containing cells. In the lamina propria of the large intentine as well as in the duodenum, IgA$^+$ cells were predominant, and IgM$^+$ or IgG$^+$ cells were scarcely observed (Fig. 4a, b, c). In the large intestine, IgA$^+$ cells, IgM$^+$ cells and IgG$^+$ cells were significantly fewer than in the duodenum. Among the three sites of the large intestine,

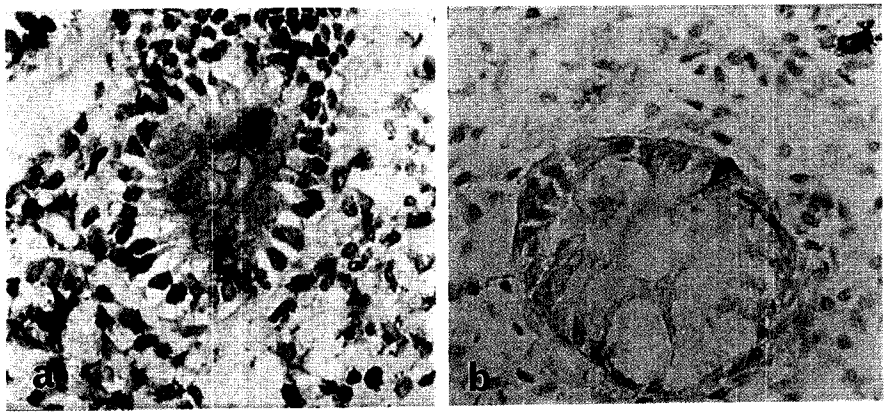

Fig. 2 Immunocytochemical staining of Leu2a$^+$ (a) and Leu7$^+$ (b) cells in the epithelium of the sigmoid colon (× 400).

Table 1 Number of positive cells in intraepithelial lymphocytes (/1,000 IELs)

	Duodenum (n = 8)	Large intestine			
		Total (n = 30)	As. colon (n = 10)	Sig. colon (n = 10)	Rectum (n = 10)
Leu 1	206 ± 49	15 ± 7^c	13 ± 5^c	12 ± 5^c	18 ± 10^c
Leu 2a	214 ± 48	13 ± 7^c	12 ± 6^c	11 ± 5^c	15 ± 9^c
Leu 3a	45 ± 29	3 ± 3^b	2 ± 1^b	3 ± 2^b	4 ± 4^b
Leu 15	20 ± 8	3 ± 3^c	2 ± 1^c	4 ± 3^c	5 ± 4^b
Leu 7	14 ± 5	9 ± 8	4 ± 6	11 ± 7	12 ± 9
			*	*	
Leu 3a/Leu 2a	0.21 ± 0.10	0.28 ± 0.25	0.18 ± 0.11	0.30 ± 0.20	0.35 ± 0.36
Leu 7/Leu 1	0.07 ± 0.02	0.66 ± 0.60^c	0.32 ± 0.31^a	0.94 ± 0.73^b	0.66 ± 0.60^a
			*		

(mean ± SD)

a: P < 0.05 *b*: P < 0.01 *c*: p < 0.001 *a, b, c*; compared with duodenum

* : P < 0.05; for each site in large intestine. IELs: intraepithelial lymphocytes. As. colon: asending colon; Sig. colon: sigmoid colon.

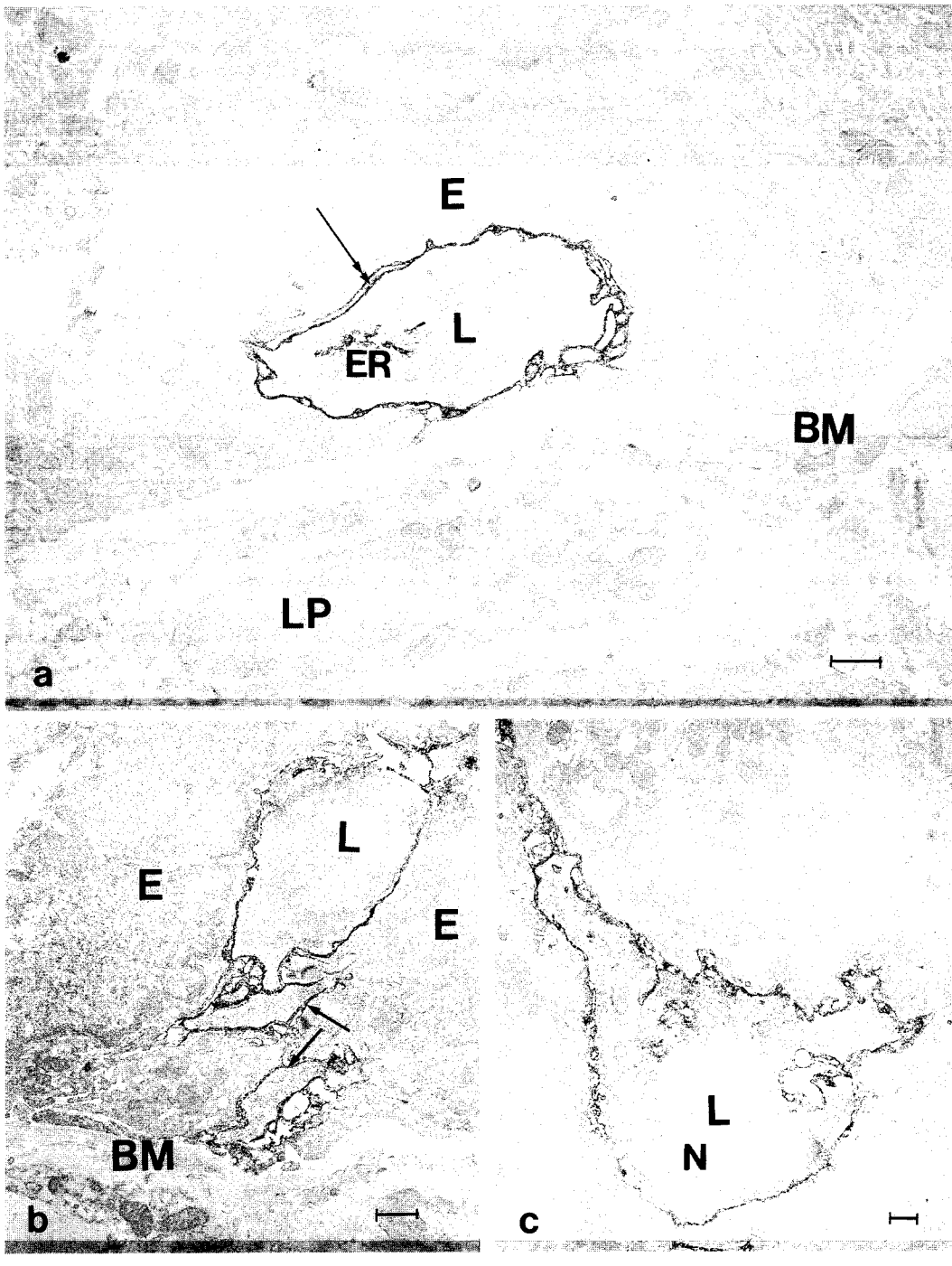

Fig. 3 Immunoelectron micrograph of Leu2a$^+$ cells (L) in the epithelium of the sigmoid colon. (a) Leu2a$^+$ cells are observed near the basal portion of the epithelial cells (E). Positive reaction are localized in cell membrane (double-headed arrows) and in the endoplasmic reticulum (ER) (× 6,000). (b) Small pseudopods (arrows) projecting from the surface of Leu2a$^+$ cells extend into epithelial cells (× 6,000). (c) Leu2a$^+$ cells have round or oval nuclei (N) (× 4,800).
BM; basement membrane of the epithelial cells LP; cells in the lamina propria Bars = 1μm

the number of Ig-containing cells varied greatly in each case but tended to be smaller in the rectum followed by the sigmoid colon and the ascending colon in that order (Table 3).

Discussion

The functions of IEL in the human intestine is still controversial. In our study, the majority of

Table 2 Number of positive cells in lamina propria (/mm²)

	Duodenum (n = 8)	Large intestine			
		Total (n = 30)	As. colon (n = 10)	Sig. colon (n = 10)	Rectum (n = 10)
Leu 1	901 ± 125	858 ± 392	953 ± 431	760 ± 432	861 ± 318
Leu 2a	345 ± 22	266 ± 156[b]	328 ± 178	239 ± 119[a]	233 ± 162[a]
Leu 3a	636 ± 105	543 ± 267	583 ± 292	532 ± 285	517 ± 247
Leu 15	101 ± 55	125 ± 109	144 ± 121	120 ± 113	78 ± 79
Leu 7	88 ± 26	48 ± 30[c]	60 ± 37[a]	43 ± 21[c]	41 ± 29[b]
Leu 3a/Leu 2a	1.84 ± 0.25	2.57 ± 1.81	1.98 ± 0.96	2.44 ± 1.15	3.28 ± 2.71

a: P < 0.05 *b*: P < 0.01 *c*: p < 0.001 *a, b, c*; compared with duodenum. (mean ± SD)
No significant difference was found among the sites in the large intestine. As. colon, Sig. colon; See Table 1.

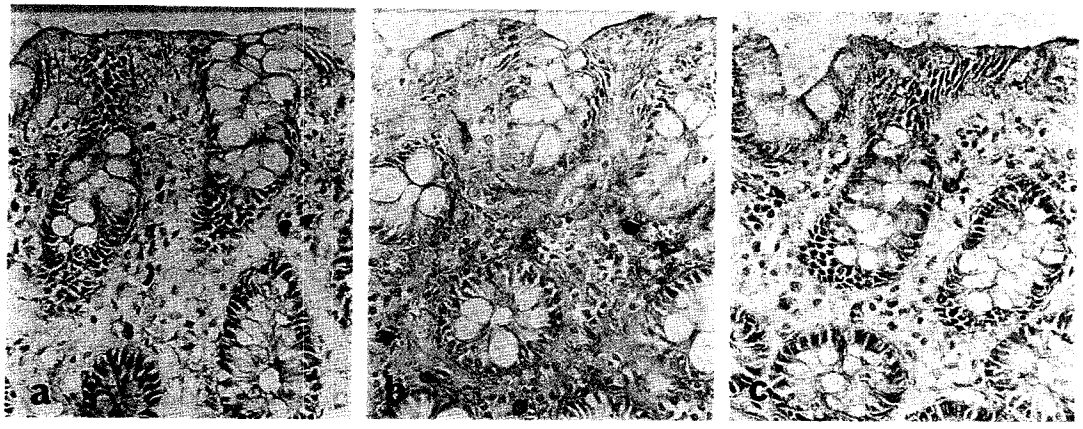

Fig. 4 IgA (a), IgM (b) and IgG (c) containing cells in the lamina propria of the sigmoid colon. IgA containing cells are predominant (× 200).

Table 3 Number of Ig containing cells in lamina propria (/mm²)

	Duodenum (n = 8)	Large intestine			
		Total (n = 30)	As. colon (n = 10)	Sig. colon (n = 10)	Rectum (n = 10)
IgA	1598 ± 246	867 ± 409[c]	1039 ± 434[b]	805 ± 382[c]	758 ± 398[c]
IgM	399 ± 135	134 ± 127[c]	208 ± 189[a]	114 ± 69[c]	82 ± 42[c]
			*		
IgG	179 ± 48	116 ± 125[a]	172 ± 1861	104 ± 186	71 ± 51[c]

a: P < 0.05 *b*: P < 0.01 *c*: p < 0.001 *a, b, c*; compared with duodenum. (mean ± SD)
* : P < 0.05; for each site in large intestine. As. colon, Sig. colon; See Table 1.

the IEL were Leu1$^+$ Leu2a$^+$, and most were Leu15$^-$ in both the duodenum and the large intestine. One would argue that the negative reactivity of IEL to Leu15 antibody is due to loss of antigenicity by the fixation which we used, but we have already reported positive staining of mononuclear cells by the same method used in this paper (14 - 16). Furthermore, immunoelectron microscopic observation revealed that some Leu2a$^+$ IELs possessed pseudopods extending into intestinal epithelial cells. Leu2a antigen is thought to be expressed on a subpopulation of human T cells that perform supressor and cytotoxic functions, and Leu15 antigen supressor antigens (18, 19). Therefore, our findings suggest that some Leu2a$^+$ cells in IELs may reflect a lymphocytotoxic process (20). Some investigators (21–23) have reported no cytotoxic activities in IELs. Trejdosiewicz *et al.* (24) showed that all CD8$^+$ IELs in human colon were not stained with anti-H366 antibody (25) which recognizes a population of cytotoxic T cell as well as NK/K cells, but not suppressor or helper T cells. They suggest that human IELs are mainly suppressor T cells rather than cytotoxic and might contribute to the development of immunological tolerance to orally investigated antigens. In contrast, Nauss *et al.* (26) showed that IELs in rat had natural killer cytotoxic activity. Mowat *et al.* (27) have identified both cytotoxic T cell and NK cell activity of the IELs, and suggest that these cells might play an important role in mucosal defence against intracellular organisms such as viruses or parasites. Furthermore, IELs, peripheral T lymphocytes and dendric epidermal cells have been recently shown to express $\gamma\delta$ T-cell receptors (TCRs) (28–30). Major functions of T cells bearing $\gamma\delta$ TCRs are reported to be cytotoxic, and these cells are thought to be important in surveillance of abnormal intestinal epithelia (31). Bonneville *et al.* (32) showed that IELs isolated from murine small intestines were CD8$^+$ CD4$^-$ and most of these CD8$^+$ cells expressed $\gamma\delta$ TCRs. These observations are consistent with our data suggenting that the majority of IELs consist of cytotoxic T cells. We observed that the number of IELs was significantly higher in the duodenum than the large intestine in accord with others' observations. These findings might suggest that the immune mechanism against various foreign antigens is more highly activated, and IELs play a more important role in mucosal defence in the small intestine than in the large intestine.

Concerning the presence of Leu7$^+$ NK cells, conflicting results have been reported. Hirata *et al.* (4) and Chiba *et al.* (33) observed Leu7$^+$ cells in the eqithelium of the small and large intestine. In contrast, Fiocchi *et al.* (23) and Cerf-Bensussan *et al.* (22) reported that IELs were not stained with anti Leu7 antibody. In our study, Leu7$^+$ IELs were observed, although scarcely, and more in the distal than in the proximal colon. The Leu7$^+$/Leu1$^+$ ratio was apparently higher in the large intestine than in the duodenum. The differences in these results may be due to different fixation techniques. We used PLP fixative which has given consistent results in this kind of immunohistochemical work and is believed to provide confident results (13–16). Our results may suggest that the first line defense mechanism in the intestine is more highly assigned to Leu7$^+$ NK cells in the large intestine than in the duodenum.

IELs are normally found mainly along the basement membrane of intestinal epithelial cells (34, 35), suggesting that lymphocytes migrate to the intraepithelial space from the lamina propria by nonspecific diffusion (36). In our study, IELs were indeed found along the basement membrane of the epithelium. However, IELs were apparently more prominent in the duodenum than in the large intestine, although in the lamina propria the number of lymphocytes was similar in both of the large intentine and the duodenum. Moreover, Ig-containing IELs were not observed either in the small intestine or in the large intestine as in others' reports (3, 7), although about half of the mononuclear cells in the lamina propria were Ig-containing cells. These findings suggest the

presence of specific mechanism for the migration of lymphocytes from the lamina propria to the intraepithelial space rather than nonspecific diffusion.

In the lamina propria, IgA^+ cells were most frequently observed among the Ig-containing cells in the large intestine as well as the duodenum. IgA^+, IgM^+ or IgG^+ cells were apparently less common in the large intentine than in the duodenum and tended to be less numerous in the rectum than the ascending colon. These findings are in accord with those of Crabbe *et al.* (37) and might indicate the diverse humoral immune responses in the various sites of the intestine, since secretory IgA and IgM are thought to act as a first line of mucosal defense mechanism. Bjerke *et al.* (38) reported that IgG^+ cells were more numerous in the appendix than in the colon and preferentially accumulated adjacent to lymphoid follicles, suggesting that IgG^+ cells most likely represent follicle derived B cells that have reached terminal maturation locally. Since the appendix has many lymphoid tissues, the appendix may greatly contribute to the different distribution of IgG-containing cells among the sites of the large intestine.

In summary, our findings that the number of lymphocyte subsets, $Leu7^+$ NK cells and Ig-containing cells differed among the duodenum and the various sites of the large intestine suggest variation of local immune responses, and differences in assigned immunological functions among the various sites of the intestines.

Acknowledgments. The authors thank Drs. Shigeatsu Fujiki, Motowo Mizuno and Jun Tomoda.

References

1. Bockus HL: Ulcerative colitis. History and epidemiology: in Bockus Gastroenterology, 4th Ed. WB Saunders Co, Philadelphia (1985) pp. 2137-2139.
2. Tajima K, Hirose K, Nakagawa N, kuroishi T and Toninaga S: Urban-rural difference in the trend of colo-rectal cancer mortality with special reference to the subsites of colon cancer in Japan. Jpn J Cancer Res (Gann) (1985) **76**, 717-728.
3. Kobayashi K, Asakura H, Hamada Y, Hibi T, Watanabe M, Yoshida T, Watanabe N, Miura S, Aiso S and Tsuchiya M: T lymphocyte subpopulations and immunoglobulin-containing cells in the colonic mucosa of ulcerative colitis; A morphometric and immunohistochemical study. J Clin Lab Immunol (1988) **25**, 63-68.
4. Hirata I, Berrebi G, Austin LL, Keren DF and Dobins WO: Immunohistological characterization of intraepithelial and lamina propria lymphocytes in control ileum and colon and in inflammatory bowel disease. Dig Dis Sci (1986) **31**, 593-603.
5. Brandtzaeg P, Valnes K, Scott H, Rognum TO, Bjerke K and Baklien K: The human gastrointestinal secretory immune system in health and disease. Scand J Gastroenterol (1985) **20**, (Suppl 114) 17-38.
6. James SP, Strober W, Quinn TC and Danovitch SH: Crohn's disease, New concepts of pathogenesis and current approaches to treatment. Dig Dis Sci (1987) **32**, 1297-1310.
7. Kett K, Rognum TO and Brandtzaeg P: Mucosal subclass distribution of immunoglobulin G-producing cells is different in ulcerative colitis and Crohn's disease of the colon. Gastroenterology (1987) **93**, 919-924.
8. Allison MC, Poulter LW, Dhillon AP and Pounder RE; Immunohistological studies of surface antigen on colonic lymphoid cells in normal and inflamed mucosa. Gastroenterology (1990) **99**, 421-430.
9. Fawcett DW: The large intestine. A Textbook of Histology, 11th ed. WB Saunders Co, Philadelphia (1986) 660-664.
10. Fillipe MI and Branfoot AC: Mucin histochemistry of the colon. Curr Top Pathol (1976) **63**, 143-178.
11. Nakane PK and Kawaoi A: Peroxidase labeled antibody. A new method of conjugation. J Histchem Cytochem (1974) **22**, 1084-1091.
12. Mclean IW and Nakane PK: Periodate-lysine-paraformaldehyde fixative. A new fixative for immunoelectron microscopy. J Histochem Cytochem (1974) **23**, 1077-1083.
13. Yamada G and Nakane PK: Hepatitis B core and surface antigens in liver tissue. Light and electron microscopic localization by the peroxidase-labeled antibody method. Lab Invest (1977) **36**, 649-659.
14. Nishihara T: Intrahepatic distribution of T cell and T cell subsets in cases with type B chronic liver disease by peroxidase-labeled antibody method using monoclonal antibodies. Gastroenterol Jpn (1983) **18**, 320-329.
15. Hyodo I, Yamada G and Nagashima H: Cellular immune responses in the acute exacerbation of hepatitis B E antigen-positive type B chronic hepatitis. Gastroenterol Jpn (1985) **20**, 315-323.
16. Yamada G, Hyodo I, Tobe K, Mizuno M, Nishihara T, Kobayashi T and Nagashima H: Ultrastructual immunocytochemical analysis of lymphocytes infiltrating bile duct epithelia in primary biliary cirrhosis. Hepatology (1986) **6**, 385-391.
17. Isobe Y, Chen ST and Nakane PK; Studies on translocation

of immunoglobulins across intestinal epithelium. I. Improvements in the peroxidase-labeled antibody method for application to study of human intestinal mucosa. Acta Histochem Cytochem (1977) **10**, 161-171.

18. Landay A, Gartland GL and Clement LT: Characterization of a phenotypically distinct subpopulation of Leu-2$^+$ cells that suppresses T cell proliferative responses. J Immunol (1983) **131**, 2757-2761.
19. Clement LT, Dagg MK and Landay A: Characterization of human lymphocyte subpopulations: Alloreactive cytotoxic T-lymphocyte precursor and effector cells are phenotypically distinct from Leu2a$^+$ suppressor cells. J Clin Immunol (1985) **4**, 395-402.
20. Sanderson CJ: The mechanism of T cell mediated cytotoxity 5. Morphological studies by electron microscopy. Proc R Soc Lond B (1977) **198**, 315-323.
21. Chiba M, Bartnik W, Remine SG, Thayer WR and Shorter RG: Human colonic intraepithelial and lamina proprial lymphocytes: Cytotoxity *in vitro* and the potential effects of the isolation method on their functional properties. Gut (1981) **22**, 177-186.
22. Cerf-Bensussan N, Guy-Grand D and Griscelli C: Intraepithelial lymphocytes of human gut: Isolation, characterisation and study of natural killer activity. Gut (1985) **26**, 81-88.
23. Fiocchi C, Tubbs RR and Youngman KR: Human intestinal mucosal monouclear cells exhibit lymphokine-activated killer cell activity. Gastroenterology (1985) **88**, 625-637.
24. Trejdosiewicz LK, Malizia G, Badr-el-Din S, Smart CJ, Oakes DJ, Southgate J, Howdle PD, Janossy G, Poulter LW and Losowsky MS: T cell and mononuclear phagocyte populations of the human small and large intestine. Adv Exp Med Biol (1987) 216A, 465-473.
25. AL-Sakkaf L, Pozzilli P, Sensi M, Irving WL and Bottazzo GF: A cell surface monoclonal antibody (H 366) helps to discriminate human cytotoxic from suppressor T cells. Clin Exp Immunol (1985) **65**, 594-599.
26. Nauss KM, Pavlina TM, Kumar V and Newberne PM: Functional characteristics of lymphocytes isolated from the rat large intestine. Gastroenterology (1984) **86**, 468-475.
27. Mowat AM, Tait RC, Mackenzie S, Davies MDJ and Parrot DMV: Analysis of natural killer effector and suppressor activity by intraepithelial lymphocytes from mouse small intestine. Clin Exp Immunol (1983) **52**, 191-198.
28. Brenner MB, McLean J, Dialynas DP, Strominger JL, Smith JA, Owen FL, Seddman JG, Ip S, Rosen F and Krangel MS: Identification of a putative second T-cell receptor. Nature (1986) **322**, 145-149.
29. Koning F, Stingel G, Yokohama WM, Yamada H, Maloy WL, Tschachler E, Shevach EM and Coligan JE: Identification of a T3-associated $\gamma\delta$ T cell receptor on Thy-1$^+$ dendritic epidermal cell lines. Science (1987) **236**, 834-837.
30. Goodman T and Lefrancois L: Expression of the $\gamma\delta$ T-cell receptor on intestinal CD8$^+$ intraepithelial lymphocytes. Nature (1988) **333**, 855-858.
31. Janeway CA Jr, Jones B, Hatday A: Specificity and function of T cells bearing $\gamma\delta$ receptors. Immunol Today (1988) **9**, 73-76.
32. Bonneville M, Janeway CA, Ito K, Haser W, Ishida I, Nakanishi N and Tonegawa S: Intestinal intraepithelial lymphocytes are a distinct set of $\gamma\delta$ T cells. Nature (1988) **336**, 479-481.
33. Chiba M, Ohta H, Nagasaki A, Arakawa H and Masamune O: Lymphoid cell subsets in normal human small intestine. Gastroenterol Jpn (1986) **21**, 336-343.
34. Cerf-Bensussan N, Schneeberger EE and Bhan AK: Immunohistologic and immunoelectron microscopic characterization of the mucosal lymphocytes of human small intestine by the use of monoclonal antibodies. J Immunol (1983) **130**, 2615-2622.
35. Marsh MN: Studies of intentinal lymphoid tissue: 2 Aspect of proliferation and migration of epithelial lymphocytes in the small intestine of mice. Gut (1975) **16**, 674-682.
36. Brandtzaeg P, Halstensen TS, Kett K, Krajci P, Kvale D, Rognum TO, Scott H and Sollid LM: Immunobiology and immunopathology of human gut mucosa: Humoral immunity and intraepithelial lymphocytes. Gastroenterology (1989) **97**, 1562-1584.
37. Crabbbe PA and Heremans JF: The distribution of immunoglobulin-containing cells along the human gastrointestinal tract. Gastroenterology (1966) **51**, 305-316.
38. Bjerke K, Brandtzaeg P and Rognum TO: Distribution of immunoglobulin producing cells is different in normal human appendix and colon. Gut (1986) **27**, 667-674.

Received December 7, 1990; accepted February 1, 1991.