

Acta Medica Okayama

Volume 33, Issue 2

1979

Article 6

APRIL 1979

Existence of serum HBe antigen and expression of liver HB surface and core antigens in hepatitis type B patients.

Takao Tsuji, *Okayama University*
Kunihiko Naito, *Okayama University*
Junichi Inoue, *Okayama University*
Masao Tsuchiya, *Okayama University*
Kiyonori Araki, *Okayama University*
Toru Shinohara, *Okayama University*
Kimiaki Onoue, *Okayama University*
Hideo Nagashima, *Okayama University*
Katsuyuki Tokuyama, *Kawasaki Medical College*
Takeshi Okada, *Matsuyama Saiseikai Hospital*

Existence of serum HBe antigen and expression of liver HB surface and core antigens in hepatitis type B patients.*

Takao Tsuji, Kunihiko Naito, Junichi Inoue, Masao Tsuchiya, Kiyonori Araki, Toru Shinohara, Kimiaki Onoue, Hideo Nagashima, Katsuyuki Tokuyama, and Takeshi Okada

Abstract

A study of 52 liver biopsies (47 hepatitis type B and 5 asymptomatic carriers) was performed to clarify the roles of HBe antigen (HBeAg), HB surface antigen (HBsAg) and HB core antigen (HBcAg). In this study, the Gudat classification was modified so as to classify the patterns of HB antigens into six reaction types including: type O (negative for both liver HBsAg and liver HBcAg), type III-A (characterized by a spotty HBsAg pattern) and type III-B (characterized from a sub-lobular to lobular HBsAg localization pattern). This classification enabled accurate prediction of the prognosis of hepatitis. Patients with positive serum HBeAg had either minimal hepatitis with mild clinical features or chronic aggressive hepatitis with severe clinical features. Ten patients negative for both HBeAg and HBeAb were all positive for liver HBcAg. In all 3 patients on corticosteroid administrations liver tissue was markedly positive for HBcAg and serum was usually positive for HBeAb.

KEYWORDS: HBs antigen, HBc antigen, HBe antigen, hepatitis B virus, hepatitis type B, chronic hepatitis type B, chronic hepatitis

*PMID: 157670 [PubMed - indexed for MEDLINE]

Acta Med. Okayama 33, (2), 121-131 (1979)

**EXISTENCE OF SERUM HBe ANTIGEN AND EXPRESSION
OF LIVER HB SURFACE AND CORE ANTIGENS
IN HEPATITIS TYPE B PATIENTS**

Takao TSUJI, Kunihiko NAITO, Junichi INOUE, Masao TSUCHIYA,
Kiyonori ARAKI, Toru SHINOHARA, Kimiaki ONOUE,
Hideo NAGASHIMA, Katsuyuki TOKUYAMA*
and Takeshi OKADA**

*First Department of Internal Medicine, Okayama University Medical School,
Okayama 700, Japan, *Department of Internal Medicine, Kawasaki Medical
College, Okayama 700, Japan, and **Department of Internal Medicine,
Matsuyama Saiseikai Hospital, Matsuyama 791-41, Japan*

Received December 25, 1978

Abstract. A study of 52 liver biopsies (47 hepatitis type B and 5 asymptomatic carriers) was performed to clarify the roles of HBe antigen (HBeAg), HB surface antigen (HBsAg) and HB core antigen (HBcAg). In this study, the Gudat classification was modified so as to classify the patterns of HB antigens into six reaction types including: type 0 (negative for both liver HBsAg and liver HBcAg), type III-A (characterized by a spotty HBsAg pattern) and type III-B (characterized from a sublobular to lobular HBsAg localization pattern). This classification enabled accurate prediction of the prognosis of hepatitis. Patients with positive serum HBeAg had either minimal hepatitis with mild clinical features or chronic aggressive hepatitis with severe clinical features. Ten patients negative for both HBeAg and HBeAb were all positive for liver HBcAg. In all 3 patients on corticosteroid administrations liver tissue was markedly positive for HBcAg and serum was usually positive for HBeAb.

Key words: HBs antigen, HBc antigen, HBe antigen, hepatitis B virus, hepatitis type B, chronic hepatitis

Carriers persistently positive for HB surface antigen (HBsAg) and HBe antigen (HBeAg) in serum have been reported recently as sources of HB virus infection (1). On the other hand, hepatitis type B with positive serum HBeAg is thought to be liable to become chronic (2, 3, 4) and HB core antigen (HBcAg) is thought to be more closely associated with virus replication than HBsAg (5, 6). The roles of these antigens are still unclear.

This paper deals with classification of localization patterns of hepatic lobular HBsAg and HBcAg by making some modifications on the schema reported by Gudat *et al.* (7). Moreover, the localization patterns of liver lobular HBsAg and HBcAg is discussed in relation to serum HBeAg.

MATERIALS AND METHODS

A series of 47 hepatitis type B patients and 5 asymptomatic carriers was investigated. Liver biopsy specimens from all these patients were frozen rapidly with dry-ice acetone, and preserved at -70°C in a deep freezer (Kelvinator Co.). Other liver tissue specimens were fixed in Bouin's fixation solution and embedded in paraffin by a routine technique for staining.

The histological diagnoses of hepatitis patients based on the classification reported by De Groot *et al.* (8, 9) were minimal hepatitis (5 cases), acute hepatitis (1 case), chronic persistent hepatitis (CPH) (3 cases), chronic aggressive hepatitis (CAH) with activity moderate (2A) (6 cases), CAH with activity severe (2B) (23 cases), chronic lobular hepatitis (CLH) (11 cases), and liver cirrhosis (LC) (3 cases).

Staining methods for liver HBsAg and HBcAg. Liver HBsAg was stained by a direct immunofluorescent method (10) using fluorescein isothiocyanate (FITC) labelled rabbit anti-HBsAg solution. HBcAg was stained by an immunofluorescent complement (IFC) technique using guinea pig C3 as previously reported (11). For the paraffin embedded tissue specimens, HBsAg was stained by an enzyme-labelled antibody method (10) using peroxidase-labelled swine anti-rabbit IgG (Dakopatts Lab.), and HBcAg was stained by an enzyme-labelled antibody method using guinea pig complement.

Detection of serum HBeAg and HBeAb. Serum HBeAg and serum HBeAb were detected with our technique (PEG-MO) (12). The method was as follows: patient sera were concentrated with polyethylene glycol (PEG) (MW 6,000). To 0.5 ml of each serum specimen, 0.02 M acetate buffer, pH 4.6 (3.0 ml) was added, followed by 31.5% PEG (1.0 ml). The final concentration of PEG was 7% w/v. The pH was 5.2. These sample were then centrifuged at 3,000 r. p. m. for 15 min. The precipitins were dissolved in a few volumes of 0.005 M phosphate buffer saline, pH 7.2 (PBS), and used as the concentrated materials for routine treatment by the micro-Ouchterlony (MO) technique of Magnius (13).

Classification of localization patterns of HBsAg and HBcAg in hepatic lobules. An attempt was made to classify the localization patterns of HBsAg and HBcAg in hepatic lobules according to the classification of Gudat *et al.* (7). In this study, type 0 (negative for both HBsAg and HBcAg) was added to their classification. Furthermore, type III (characterized by the dominance of HBsAg over HBcAg) was divided into type III-A (characterized by much HBsAg and a spotty HBsAg pattern) and type III-B (characterized by much HBsAg and a sublobular HBsAg localization pattern). Our modified classification consisted of six reaction types of HBsAg and HBcAg, as shown in Fig. 1.

Titration of HBcAb. The titer of serum HBcAb was determined by an immunofluorescent technique (11). The term "low titer" referred to serum of which a five-fold dilution was still positive for HBcAb. The term "high titer" referred to serum of which a 640-fold dilution was still positive for HBcAb.

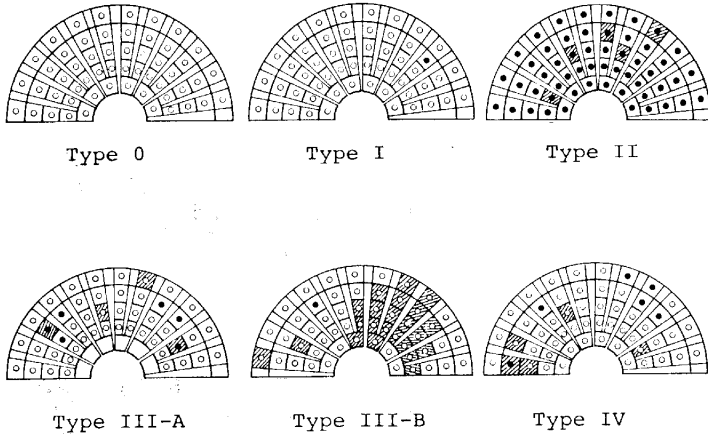


Fig. 1. Our modification of the Gudat schema showing the features of HBsAg and HBcAg in hepatic lobules (● : HBcAg, ▨ : HBsAg)

RESULTS

Relationship between histological features of hepatitis type B and localization patterns of liver HBsAg and HBcAg in hepatic lobules. HBsAg was detected in the cytoplasm of hepatic cells. HBcAg was granular throughout the cytoplasm, near the membrane, and in the nucleus of hepatic cells (Fig. 2). The features of these two antigens in hepatitis type B are listed in Table 1. Four of 5 cases of minimal hepatitis showed type III-A pattern, while 1 case of acute hepatitis showed type I pattern and some localized HBsAg (Fig. 3). In the cases of chronic hepatitis, type III-B pattern was the main observation in chronic severe cases which progressed from CPH through CAH2A to CAH2B (Fig. 4). This pattern was

TABLE 1. HISTOLOGICAL DIAGNOSES OF HEPATITIS TYPE B AND LOCALIZATION PATTERNS OF HB ANTIGENS IN HEPATIC LOBULES

Histological diagnosis	No. of cases	Types					
		0	I	II	III-A	III-B	IV
Minimal hepatitis	5				4	1	
AH	1		1				
CPH	3		2	1			
CAH(2A)	6		2	1		2	1
CAH(2B)	23	2	1			12	8
CLH	11	2	2	1		4	2
LC	3					3	
Total	52	4	8	3	4	22	11

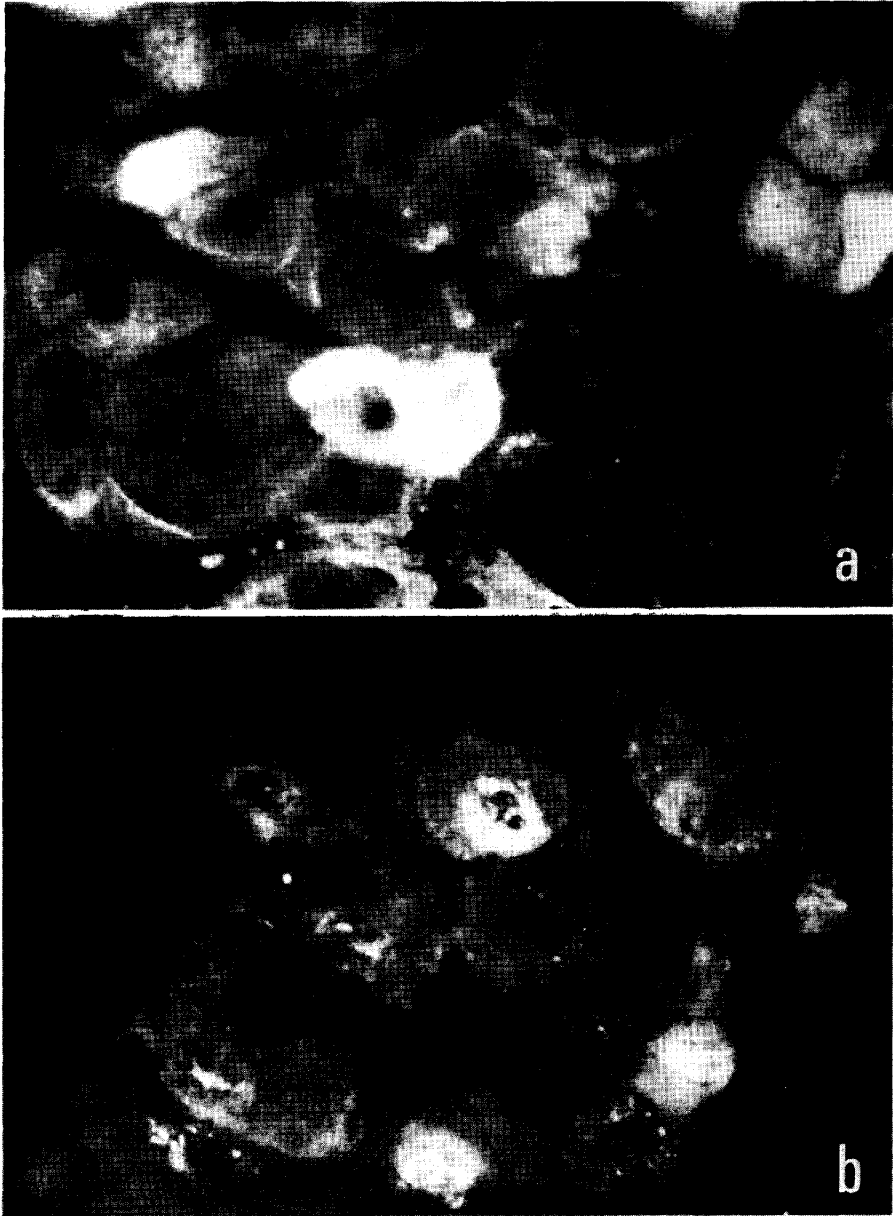


Fig. 2. Biopsy specimen from a chronic aggressive hepatitis (CAH2B) patient with positive serum HBeAg.

a. Positive fluorescent HBsAg is localized in the cytoplasm and on the membrane of hepatic cells ($\times 400$). b. Identical section of the same case shows positive HBcAg. HBcAg is localized mainly in the nucleus and in some parts of the cytoplasm and the membrane of hepatic cells ($\times 400$)

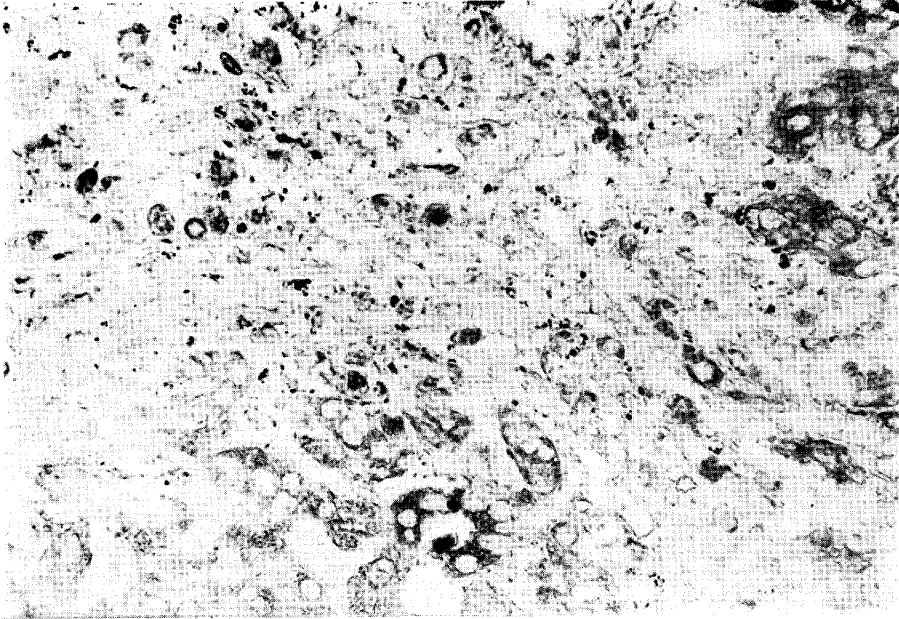


Fig. 3. Biopsy specimen from an acute hepatitis patient without either serum HBeAg or HBeAb. There is little positive peroxidase activity of HBsAg ($\times 200$).

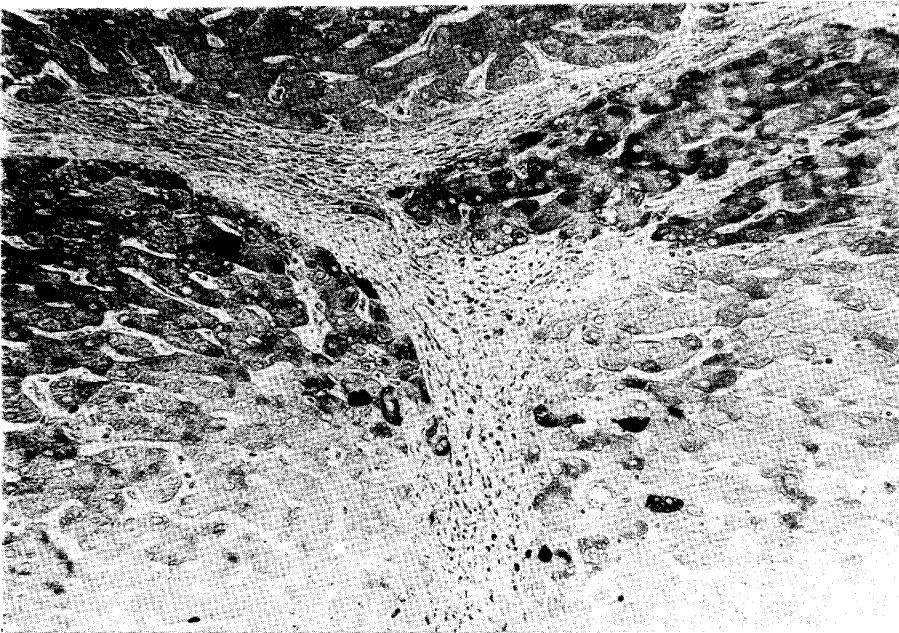


Fig. 4. Biopsy specimen from another case of CAH2B without either HBeAg or HBeAb. Paraffin section stained by peroxidase-labelled antibody technique for HBsAg ($\times 100$).

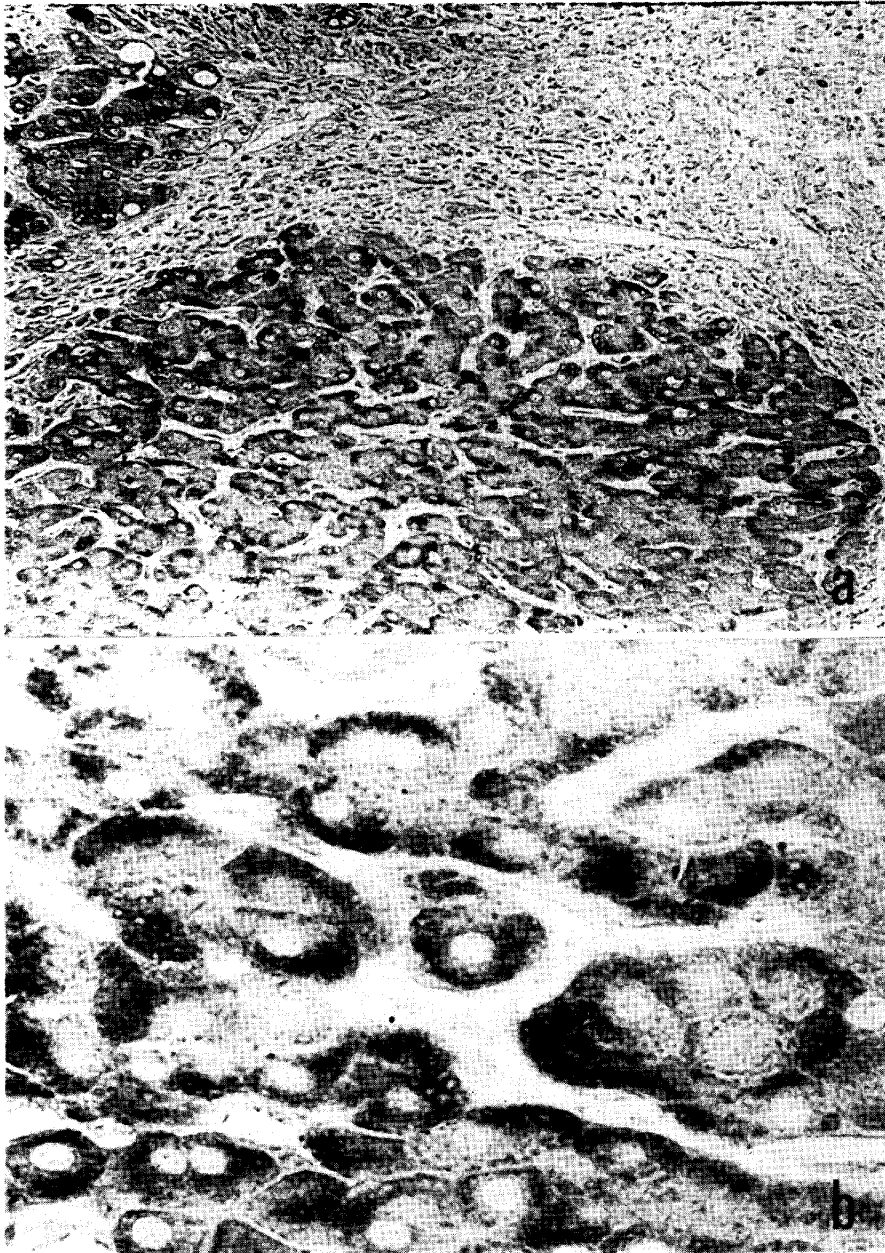


Fig. 5. Biopsy specimen from a liver cirrhotic patient without either serum HBsAg or HBeAb.

a. Positive peroxidase activity of HBsAg in cytoplasm ($\times 100$). b. High power view of the same section. HBsAg is demonstrated in cytoplasm. Note positive HBsAg as a homogeneous pattern in the submembrane area and as an inclusion body-like pattern in hepatic cells ($\times 400$).

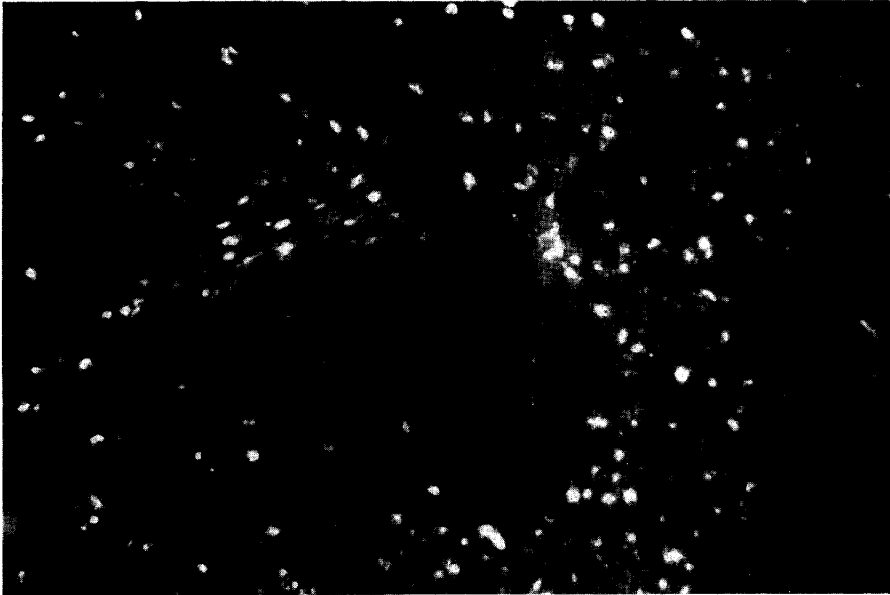


Fig. 6. Biopsy specimen from a chronic persistent hepatitis (CPH) patient on corticosteroid administration. Positive fluorescent HBcAg in nuclei appear diffusely distributed throughout a lobule. This case has serum positive for HBeAb ($\times 100$).

observed in 12 (52.2%) of 23 cases of CAH2B, and in all 3 cases of liver cirrhosis (Fig. 5).

On the relationship between clinical features and localization patterns, type 0 and I were found in florid stages, such as acute hepatitis, CAH2A and CAH2B. One case of each of CPH, CAH2A and CLH was type II (Fig. 6), and all had been given corticosteroids. All cases of type III-A (Fig. 7) and type III-B (Fig. 4) showed relatively simply mild clinical features. Their serum transaminase levels were normal. Type IV was noted in cases of chronic hepatitis suggesting recrudescence of CAH2B.

The relationship between localization patterns of liver HBsAg and HBcAg, and detection rates for serum HBeAg. The relationship between localization patterns of liver HBsAg and HBcAg and detection rates for serum HBeAg was studied in 24 cases (Table 2). Two of 5 HBeAg positive cases were diagnosed as CAH2A with type I, and the remaining 3 cases were diagnosed as minimal hepatitis with type III-A. On the other hand, 4 of 9 HBeAb positive cases showed 0 type pattern, and this group included one case each of type I, type II, and type III-B. Five of 6 cases with type III-B were negative for both HBeAg and HBeAb.

A summary of the relationship between liver HB antigens and serum HBeAg is shown in Table 3. It is clear from this table that all 5 HBeAg positive cases and

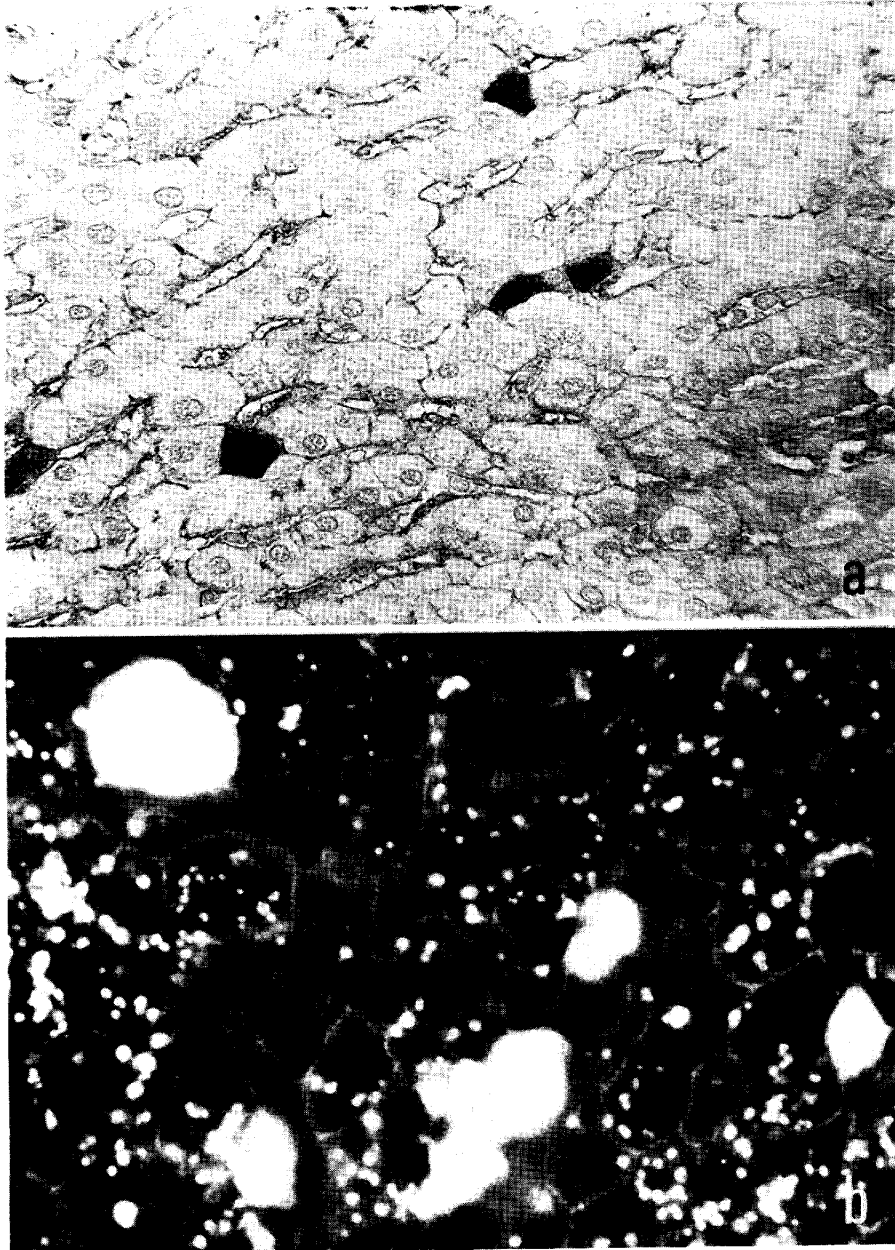


Fig. 7. Biopsy specimen of an asymptomatic carrier with positive serum HBsAg. a. Positive peroxidase activity of HBsAg is demonstrated in the cytoplasm of hepatic cells and on the cell membrane ($\times 200$). b. Frozen section of the same case shows similar fluorescent HBsAg findings. Note the positive HBsAg of cell membrane ($\times 400$).

Serum HBeAg and Liver HB Antigens

TABLE 2. LOCALIZATION PATTERNS OF HBsAg AND HBcAg IN HEPATIC LOBULES, AND HBV-ASSOCIATED ANTIBODY IN SERUM

Type	HBsAg and HBcAg in liver tissue	No. of cases	Serum			Titer of HBcAb in serum ^a	
			HBcAg	HBeAb	-	Low	High
0	s(-), c(-)	4	0	4	0	4	0
I	s(-)~(±), c(+)	4	2	1	1	2	2
II	s(+), c(+++)	1	0	1	0	0	1
III-A	s(+++) spotty, c(+)	3	3	0	0	0	3
III-B	s(+++) lobular, c(+)	6	0	1	5	0	6
IV	s(+)-(++), c(++)	6	0	2	4	0	6

^a HBcAb (IFC method); low titer : 5×, high titer : 640×

TABLE 3. LIVER HBsAg AND HBcAg, AND SERUM HBeAg OR HBeAb

HBeAg or HBeAb in serum	No. of cases	HBsAg in liver cell		HBcAg in liver cell	
		(+)	(-)	(+)	(-)
HBeAg +	5	3	2	5	0
HBeAb +	9	4	5	5	4
Both -	10	9	1	10	0

all 10 cases negative for both HBeAg and HBeAb were positive for liver HBcAg, and that 5 (55.6%) of 9 HBeAb positive cases were positive for liver HBcAg.

The relationship between localization patterns of liver HB antigens and the prognosis of patients. Changes in the localization patterns of liver HB antigens during the clinical courses of 9 patients are shown in Table 4. Three of 9 cases changed

TABLE 4. HISTOLOGICAL DIAGNOSES, LOCALIZATION PATTERNS OF HB ANTIGENS AND HBcAb TITERS IN SERO-POSITIVE PATIENTS

Case	Age	Sex	Changes of histological diagnosis ^a	Changes of pattern (HBsAg & HBcAg)	Initial HBcAb titer
Ko, D.	57	M	2A-2A-2B	I-I-0	low
I, J.	32	F	AH-(recovery)	I-0	low
Na, S.	22	M	2A-2B-CLH	I-I-0	high
Go, T.	27	M	2B-CLH	IV-II	high
Ni, M.	24	M	2B-2B-LC	IV-III-III	high
Hi, K.	34	M	2B-LC	III-III	high
Ha, M.	20	M	2B-2B	III-III	high
Ta, S.	33	M	2B-LC	IV-III	high
A, E.	18	F	2B-2B	III-III	high

^a 2A=CAH (2A), 2B=CAH (2B), LC=liver cirrhosis, AH=acute hepatitis, CLH=chronic lobular hepatitis

to type III-B and their clinical features were mild. There were also changes in the histological diagnoses. For instance, some cases changed from CAH2A to CPH to CLH. In addition, 2 cases with low titers of serum HBcAb, changed to type 0.

DISCUSSION

The detection of serum HBeAg in hepatitis type B patients has been reported by Nielsen *et al.* (2), Sheikh *et al.* (3), Eleftherion *et al.* (4), and Hess *et al.* (5), and their results are much the same as ours. Murphy *et al.* (6) studied chimpanzees infected with HB virus, and Hess *et al.* (5) carried out study of humans with a view to clarifying the relationship between HB antigens and serum HBeAg. According to these investigators, all cases in which liver HBcAg was detected also were positive for serum HBeAg, or at least, showed a very high detection rate for serum HBeAg. Furthermore, it is reported that cases with positive liver HBsAg have a low detection rate for serum HBeAb.

In the present study, liver HBcAg was detected in all five HBeAg positive cases, in all 10 cases (100%) without both HBeAg and HBeAb, and in 5 (55.6%) of 9 HBeAb positive cases. The detection rate for liver HBcAg was higher than that reported in foreign reports. These results are interesting, when one considers that transmission of HB virus from mother to infant is a very important mode of transmission (1) and that the majority of chronic hepatitis patients in Japan are thought to be due to such transmission (14). Another important finding was that HBeAb was detected in 6 of 11 cases of CLH based on the International Group classification (9). These cases had a relatively favorable prognosis. This suggests that chronic hepatitis with CLH type is a chronic hepatitis due to horizontal infection by HB virus.

The schematic localization patterns of liver HB antigens were described in detail by Gudat *et al.* (7). In our study, this classification was modified partially because there were some cases with positive tissue HBsAg and negative liver HBsAg, and other cases with either spottily localized HBsAg in the hepatic lobule or diffusely localized HBsAg in the lobule. The author anticipates that his classification underlining the above findings provides a useful means to predict the prognosis of chronic hepatitis type B.

Acknowledgment. This work was supported by grants (No. 867057 and No. 067098) from the Japan Ministry of Education in 1977.

REFERENCES

1. Okada, K., Kamiyama, I., Inomata, M., Imai, M., Miyakawa, Y. and Mayaumi, M.: e antigen and anti-e in the serum of asymptomatic carrier mothers as indicators of positive and negative transmission of hepatitis type B virus to their infants. *N. Engl. J. Med.* **294**, 746-749, 1976.
2. Nielsen, J. O., Dietrichson, O. and Juhl, E.: Incidence and meaning of the "e" determinant among hepatitis B antigen positive patients with acute and chronic liver diseases. *Lancet* **ii**, 913-915, 1974.
3. Sheikh, N. E., Woolf, I. L., Galbraith, R. M., Eddleston, A. L. W., Dymock, I. W. and Williams, R.: e antigen-antibody system as indicator of liver damage in patients with hepatitis B antigen. *Br. Med. J.* **4**, 252-253, 1975.
4. Eleftherion, N., Thomas, H. C. and Heathcote, J.: Incidence and clinical significance of e antigen and antibody in acute and chronic liver disease. *Lancet* **ii**, 1171-1174, 1975.
5. Hess, G., Nielsen, J. O., Arnold, W. and Meyer zum Büschenfelde, K. H.: e system and intrahepatocellular HBcAg and HBsAg in HBsAg positive patients with liver diseases and healthy carriers. *Scand. J. Gastroenterol.* **12**, 325-330, 1977.
6. Murphy, B. L., Peterson, J. M., Smith, J. L., Gitnick, G. L., Auslander, M. O., Berquist, K. R., Maynard, J. E. and Puecell, R. H.: Correlation between fluorescent antibody detection of hepatitis B core antigen in liver biopsies and the presence of e antigen in serum. *Infect. Immun.* **13**, 296-298, 1976.
7. Gudat, F., Bianchi, L., Sonnabend, W., Thiel, G., Aenishaenslin, W. and Stalder, G. A.: Pattern of core and surface expression in liver tissue reflects state of specific immune response in hepatitis B. *Lab. Invest.* **32**, 1-9, 1975.
8. De Groote, J., Desmet, V. J., Gedick, P., Korb, G., Popper, H., Poulsem, H., Scheuer, P. J., Schmid, M., Thaler, H., Uehlinger, E. and Wepler, W.: A classification of chronic hepatitis. *Lancet* **ii**, 626-628, 1968.
9. International Groups: Acute and chronic hepatitis revisited. Review by a International Group. *Lancet* **ii**, 914-919, 1977.
10. Tsuji, T., Naito, K., Tokuyama, K., Okada, T. and Kosaka, K.: Detection of HBs antigen in routine paraffin embedded liver tissue by enzyme-labelled antibody technique. *Acta Med. Okayama* **30**, 69-73, 1976.
11. Tsuji, T., Tokuyama, K., Okada, T., Takata, S., Naito, K., Kosaka, K., Takahashi, T. and Mayumi, M.: Detection of liver HBc antigen and its antibody in sera from viral hepatitis by the immunofluorescent complement technique. *Acta Med. Okayama* **30**, 61-67, 1976.
12. Tsuji, T., Okada, T. and Nagashima, H.: Detections of HBe antigen in sera from HB surface antigen symptom-free carrier and hepatitis patients used with polyethylene glycol (PEG). *Gastroenterologia Jpn.*, **14**(3), 1979 (in press).
13. Magnus, L. D.: Characterization of a new antigen-antibody system associated with hepatitis B. *Clin. Exp. Immunol.* **20**, 209-216, 1975.
14. Suzuki, H., Mitamura, K. and Mayumi, M.: Significance of anti-HBe antibody in hepatitis B virus infection. *U. S.-Japan Hepatitis Symposium*, Tokyo, Japan, July 17-19, 1978.