

Acta Medica Okayama

Volume 56, Issue 1

2002

Article 10

FEBRUARY 2002

A case of suffocation by an advertising balloon filled with pure helium gas.

Kei Yoshitome*

Takaki Ishikawa†

Sachiyo Inagaki‡

Yuji Yamamoto**

Satoru Miyaishi††

Hideo Ishizu‡‡

*Okayama University,

†Okayama University,

‡Okayama University,

**Okayama University,

††Okayama University,

‡‡Okayama University,

A case of suffocation by an advertising balloon filled with pure helium gas.*

Kei Yoshitome, Takaki Ishikawa, Sachiyo Inagaki, Yuji Yamamoto, Satoru Miyaishi, and Hideo Ishizu

Abstract

We encountered a rare case of suffocation by an advertising balloon filled with pure helium gas. Suffocation caused by inhalation of atmosphere lacking in oxygen is not exceptional, but reports of death by suffocation due to a pure inert gas such as helium are very rare. In this case, the balloon mooring on the ground was enclosed, warning signs were displayed, and it was clear that entering the balloon filled with an atmosphere lacking in oxygen was extremely dangerous and should not be done; the accident did, however, occur. Accidents of this kind may occur in the future unless appropriate education and countermeasures are taken.

KEYWORDS: asphyxia, suffocation, helium, advertising balloon, atmosphere lacking in oxygen

Case Report

A Case of Suffocation by an Advertising Balloon Filled with Pure Helium Gas

Kei Yoshitome*, Takaki Ishikawa, Sachiyo Inagaki, Yuji Yamamoto,
Satoru Miyaishi, and Hideo Ishizu

*Department of Legal Medicine, Okayama University Graduate School of
Medicine and Dentistry, Okayama 700-8558, Japan*

We encountered a rare case of suffocation by an advertising balloon filled with pure helium gas. Suffocation caused by inhalation of atmosphere lacking in oxygen is not exceptional, but reports of death by suffocation due to a pure inert gas such as helium are very rare. In this case, the balloon mooring on the ground was enclosed, warning signs were displayed, and it was clear that entering the balloon filled with an atmosphere lacking in oxygen was extremely dangerous and should not be done; the accident did, however, occur. Accidents of this kind may occur in the future unless appropriate education and countermeasures are taken.

Key words: asphyxia, suffocation, helium, advertising balloon, atmosphere lacking in oxygen

Aspiration of an oxygen-reduced atmosphere causes a loss of consciousness and immediate death [1-4]. Some cases of suffocation due to a reduction of oxygen in the respired atmosphere have occurred, for example in a well hole left unused for long time or in a silo ensiling herbage to silage [2-3]. However, case reports of death by suffocation due to a pure inert gas such as helium are very rare. We report here an accidental death case of a young person who one night inserted the upper half of his body into an advertising balloon filled with pure helium gas and moored on the ground in a park.

Case History

A 14-year-old boy was found dead early one morning in a supine posture, having inserted the upper half of his body into an advertising balloon filled with pure helium

gas. The balloon was moored on the ground in a park. The victim was carried to a hospital by ambulance and received artificial ventilation and cardiac massage, but he could not be resuscitated.

The advertising balloon was 220 cm in diameter and had originally been filled with 7 m³ pure helium gas, but had been ripped due to a singe from a cigarette light and contained about half the original volume when the victim was found. The balloon was enclosed by a simple fence, and warning signs were displayed.

The previous night, the victim and friends had drunk beer at a friend's home. They became noisy and about midnight were chased away by another resident of the building. The victim and friends then moved to the park. The group amused themselves for a while, but later noticed that the victim was missing.

An autopsy was performed on the following day because the cause and manner of death were indefinite.

Received March 1, 2001; accepted June 28, 2001.

*Corresponding author. Phone: +81-86-235-7195; Fax: +81-86-235-7201

E-mail: kei_y@md.okayama-u.ac.jp (K. Yoshitome)

Autopsy Findings

The victim was 160 cm tall and weighed 49 kg. Unusual external findings were numerous conjunctival petechial hemorrhages.

The heart weighed 350 g, with the left heart containing 80 ml of dark red fluid blood with many small clots and the right heart 70 ml of dark red fluid blood. Lungs (left, 570 g; right, 650 g) were markedly congested and showed pulmonary edema. Frothy fluid was seen in the pharynx and air passages. Stomach and intestines were flatulent. Marked congestion was observed in every organ, and a large number of petechiae were observed in the mucosa and serosa throughout the body.

Analysis of Gaseous Components

Analysis was carried out on an HP 5980 series gas chromatograph (Hewlett-Packard Co., Palo Alto, CA, USA). The column used was an HP-PLOT MoleSieve/5A. Nitrogen gas was used as carrier gas with a flow rate of 1 ml/min. The gaseous samples were collected by syringes from the air passage and stomach and directly injected into the GC apparatus. A 1-cm cube was cut from the lung and placed in a 20-ml volume vial and plugged. The vial was heated to 55 °C, and the upside of the headspace was collected with a syringe, then injected into the GC apparatus. Peaks of helium, O₂, and CO₂ were detected, respectively in all samples. (Fig. 1)

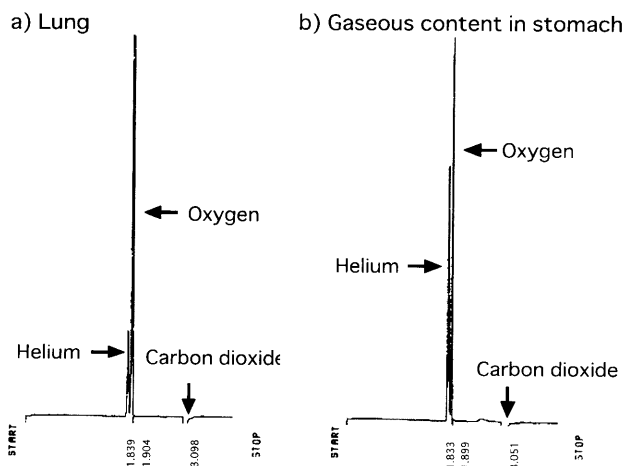


Fig. 1 Gas chromatogram of (a) head-space gas from the lung and (b) gaseous content in the stomach.

Alcohol Analysis

Analysis of the headspace gas chromatography was performed by a gas chromatograph equipped with a flame ionization detector.

Alcohol concentrations of each sample were 0.38 mg/ml in the left heart blood, 0.32 mg/ml in the right heart blood, 0.38 mg/ml in the femoral venous blood, and 0.29 mg/g in femoral muscle.

Discussion

Although artificial ventilation by intubation had been performed for 10 min in the hospital, helium gas was still detected in all the samples. This result suggests that the victim had inhaled helium gas.

The cause of death in this case was judged to be suffocation caused by inhalation of an atmosphere lacking in oxygen, based on findings at the scene, autopsy findings, and the results of analyses of gaseous content. Suicide was considered unlikely based on the results of further investigation by the police, precedent behavior of the victim and the victim's age.

Generally, laws have been enacted to prevent accidental anoxia in the occupational environment when there is danger of a lack of oxygen. This case differed from such industrial accidents, and reports of death case by suffocation in a pure inert gas such as helium are very rare [4-8].

Ordinarily, oxygen concentrations in the air are 21% (v/v). A concentration of oxygen below 10% causes a serious condition, and below 5% causes immediate unconsciousness [1-4].

In this case, the balloon was enclosed, warning signs were displayed and it was clear that entering the advertising balloon filled with an atmosphere lacking in oxygen was extremely dangerous and should not be done; the accident did, however, occur.

This case was therefore considered an accidental death caused by the lack of scientific knowledge of a still young victim combined with his strong curiosity about an unusual thing.

References

- Misawa S: Asphyxia; in Standard Textbook of Legal Medicine and Medical Law, Kamiyama S, Ishizu H and Takatsu A eds, 5th Ed, Igaku-shoin, Tokyo (2000) pp 158-177 (in Japanese).

2. Sasagawa S: Air and soil; in General Hygiene and Public Health, Fujiwara M, Watanabe G and Takakuwa E eds, 2nd Ed, Nankodo, Tokyo (1985) pp 206-217 (in Japanese).
3. Yamaguchi H: Anoxia; in Handbook of Occupational Health, Miura T eds, The Institute for Science of Labour, Kanagawa (1988) pp 903-909 (in Japanese).
4. Hishida S: Asphyxia due to miscellaneous causes; in Modern Textbook of Legal Medicine, Nagano T and Wakasugi C eds, 3rd Ed, Kanehara & Co., Ltd., Tokyo (1995) pp 141-146 (in Japanese).
5. Takatori T, Tomii S and Terazawa K: Medico-legal studies on the death from coal-mine accidents by gas spurt. *Jpn J Legal Med* (1981) **35**, 462-467.
6. Suzutani T, Ishibashi H and Takatori T: Medico-legal studies on the deaths from coal-mine accidents. *Hokkaido J Med Sci* (1979) **54**, 227-233.
7. Suzutani T, Ishibashi H and Takatori T: Medico-legal studies on the deaths from coal-mine accidents. *Hokkaido J Med Sci* (1979) **54**, 467-478.
8. Suzutani T, Ishibashi H and Takatori T: Medico-legal studies on the deaths from coal-mine accidents. *Hokkaido J Med Sci* (1979) **54**, 479-486.