

Acta Medica Okayama

Volume 56, Issue 6

2002

Article 1

DECEMBER 2002

Botulinum toxin treatment of urethral and bladder dysfunction.

Teruhiko Yokoyama* Hiromi Kumon[†] Christopher P. Smith[‡]
George T. Somogyi** Michael B. Chancellor^{††}

*Okayama University,

[†]Okayama University,

[‡]University of Pittsburgh,

**University of Pittsburgh,

^{††}University of Pittsburgh,

Botulinum toxin treatment of urethral and bladder dysfunction.*

Teruhiko Yokoyama, Hiromi Kumon, Christopher P. Smith, George T. Somogyi,
and Michael B. Chancellor

Abstract

Tremendous excitement has been generated by the use of botulinum toxin for the treatment of various types of urethral and bladder dysfunction over the past several years. Botulinum toxin is the most lethal naturally occurring toxin known to mankind. Why, then, would an urologist want to use this agent to poison the bladder or urethral sphincter? In this review article we will examine the mechanisms underlying the effects of botulinum toxin treatment. We will discuss the current use of this agent within the urologic community and will provide perspectives on future targets of botulinum toxin.

KEYWORDS: botulinum toxin, urethra, bladder

*PMID: 12685855 [PubMed - indexed for MEDLINE]

Copyright (C) OKAYAMA UNIVERSITY MEDICAL SCHOOL

Review

Botulinum Toxin Treatment of Urethral and Bladder Dysfunction

Teruhiko Yokoyama^{a*}, Hiromi Kumon^a, Christopher P Smith^b,
George T Somogyi^c, and Michael B Chancellor^b

^aDepartment of Urology Okayama University Graduate School of Medicine and Dentistry, Okayama 700-8558, Japan,

^bDepartment of Urology, and ^cDepartment of Pharmacology, University of Pittsburgh, Pittsburgh, PA 15213, USA

Tremendous excitement has been generated by the use of botulinum toxin for the treatment of various types of urethral and bladder dysfunction over the past several years. Botulinum toxin is the most lethal naturally occurring toxin known to mankind. Why, then, would an urologist want to use this agent to poison the bladder or urethral sphincter? In this review article we will examine the mechanisms underlying the effects of botulinum toxin treatment. We will discuss the current use of this agent within the urologic community and will provide perspectives on future targets of botulinum toxin.

Key words: Botulinum toxin, urethra, bladder

The world's most potent biological toxin, botulinum toxin, was first isolated in 1897 by van Ermenngem [1]. The toxin acts by inhibiting acetylcholine release at the presynaptic cholinergic junction. In the late 1980s the urologic community began to explore the use of botulinum toxin type A (BTX-A) to treat spinal cord injured patients suffering from detrusor external sphincter dyssynergia (DESD) [2-4]. A resurgence of interest over the past 5 years was led by Schurch and colleagues who reported successful treatment of spinal cord injured patients with detrusor hyperreflexia using intravesical BTX-A injections at multiple sites [5].

History of Botulinum Toxin's Medical Development

What is the story of how this "food poi-

son" became a useful medical drug? Botulinum poisoning was first described in cases of sausage poisoning in the late 1700s in Germany. A local medical officer collected data on 230 cases of botulism, and the illness became known as "Kerner's disease" [6]. It wasn't until 1897 that van Ermengem isolated the spore-forming obligate anaerobic bacteria, *Clostridium botulinum* [1].

How does botulinum toxin cause paralysis? Botulinum toxins are synthesized as single chain polypeptides with a molecular weight of approximately 150 kilodaltons (kDa) [7]. Initially, the parent chain is cleaved into its active, dichain polypeptide form consisting of a heavy chain (approx. 100 kDa) connected by a disulfide bond to a light chain (approx. 50 kDa) with an associated zinc atom (Fig. 1) [8]. Three steps are required for toxin induced paralysis: 1. binding and internalization of the toxin within the nerve terminal; 2. translocation of the light chain into the cytosol; and 3. inhibition of neurotransmitter release.

Acetylcholine release involves the ATP-dependent

Received July 3, 2002; accepted August 21, 2002.

*Corresponding author. Phone: +81-86-235-7287; Fax: +81-86-231-3896
E-mail: uroyoko@md.okayama-u.ac.jp (T. Yokoyama)

transport of the vesicle from the cytosol to the plasma membrane [9]. Vesicle docking requires the interaction of various cytoplasmic, vesicle, and target membrane proteins, some of which are specifically targeted with clostridial neurotoxins. BTX-A, for example, cleaves the

cytosolic translocation protein SNAP-25, thus preventing vesicle fusion with the plasma membrane (Fig. 2) [10].

Different Applications of Botulinum Toxin

Seven immunologically distinct neurotoxin types are known and are typically labeled from A-G. BTX-A (Botox[®], Allergan Irvine, CA, USA) received FDA approval in 1989 for the treatment of strabismus, benign essential blepharospasm, and disorders of the VIIth nerve. Since its introduction into clinical use in the 1980s, BTX-A has been successfully used to treat various conditions, including blepharospasm, strabismus, focal dystonias, muscle spasms and spasticity, axillary hyperhidrosis, and achalasia [11-15]. More recently, the U.S. FDA approved a BTX-B complex preparation (Myobloc[™], Elan South San Francisco, CA, USA) for clinical use in cervical dystonia patients.

Botulinum Toxin's Urologic Applications

Sphincter Application. Urological applications of BTX-A have been primarily associated with cases of Detrusor External Sphincter Dyssynergia (DESD). Management of spinal cord injured (SCI) patients was revolutionized with the development of clean intermittent

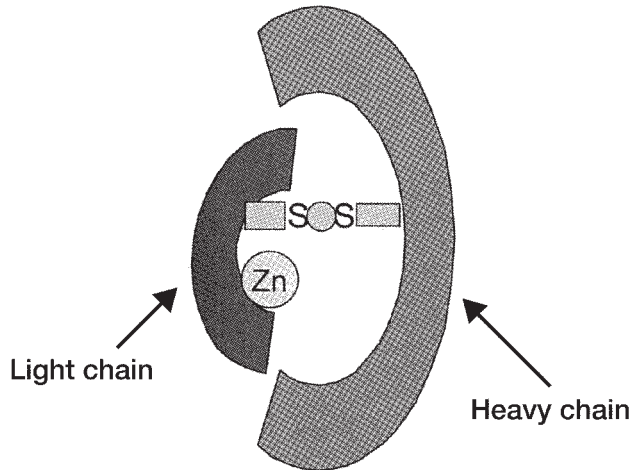


Fig. 1 This illustration depicts the active, dichain polypeptide form of botulinum toxin. The parent chain is cleaved into a heavy chain (approx. 100 kDa) connected by a disulfide bond to a light chain (approx. 50 kDa) with an associated zinc atom.

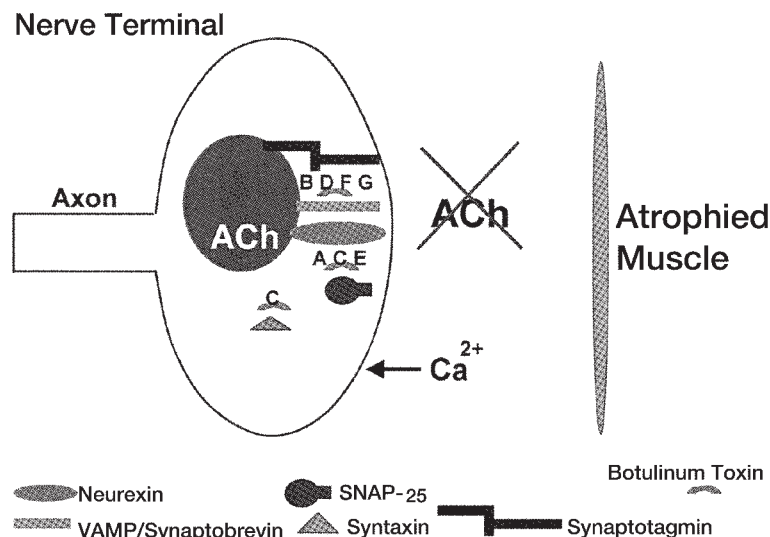


Fig. 2 Schematic diagram of a nerve terminal indicating the blocking effects of botulinum toxin on normal fusion of the synaptic vesicles with the plasma membrane. Note that after blocking of the vesicle transport by botulinum toxin, no ACh release occurs, leading to muscle atrophy.

catheterization (CIC) by Lapedes in 1971 [16]. However, not all patients can tolerate CIC and require an alternative that decreases outlet resistance and allows continuous bladder decompression. Various alternatives have been described, including external sphincterotomy, radical TURP, and various denervation procedures, *i.e.* dorsal rhizotomy [17]. These procedures are unfortunately permanent and irreversible, and carry with them inherent risks (*i.e.* bleeding, stricture formation, fistulas).

BTX-A represents a viable option in the treatment of DESD. The toxin acts at the neuromuscular junction of the external sphincter to block vesicle transport of acetylcholine, in essence producing chemical denervation. The clinical effects begin within 2-3 days and are reversible as terminal nerve sprouting occurs within 3-6 months [18]. Injection of BoNT/A (*i.e.* BoNT = laboratory grade botulinum toxin) into the sternomastoid muscle of mice has been shown to induce the formation of terminal nerve sprouts from the parent terminal [19]. The sprouts form functional synapses with the muscle but eventually regress at a time when the parent nerve terminal regains the ability to release neurotransmitters. It remains to be seen whether similar processes occur in autonomic nerves innervating the lower urinary tract.

Dykstra has investigated the effects of BTX-A injection in 2 studies of SCI patients with DESD. In the first

study, published in 1988, all 10 patients evaluated by electromyography after injection showed signs of sphincter denervation [4]. The urethral pressure profile decreased by an average of 27 cm of water, and post void residuals decreased by an average of 146 cc after toxin injection. In 1990, Dykstra reported the results of the only double-blind placebo controlled study of BTX-A injection into the external urethral sphincter of 5 men with SCI and DESD [3]. Electromyography of the external urethral sphincter indicated denervation in the 3 patients who received toxin injections. The urethral pressure profile decreased by an average of 25 cm/H₂O; the post void residual decreased by an average of 125 ml; and bladder pressure during voiding decreased to an average of 30 cm/H₂O. Parameters were unchanged from baseline in the 2 patients who received normal saline injections.

We performed a prospective study on 21 patients referred to our clinic with voiding dysfunction [20]. All patients were evaluated with video-urodynamics. Follow-up ranged from 3-16 months. Following urethral injection of Botox[®], voiding pressures decreased by an average of 38%. Sixty-seven percent of patients reported an improvement in voiding patterns. No complications or side effects were noted. Our results are consistent with the largest series to date treating DESD with BTX-A. In that study, Schurch treated 24 patients with SCI and DESD with BTX-A injection [21]. Significant improvement in DESD was noted in 21/24 pts (88%) with decreased post void residuals in most patients. The effects lasted 3-9 months with no adverse events reported. Thus, BTX-A toxin injections appear to be a safe and efficacious treatment option for DESD.

The clinical success of BTX-A is supported by laboratory research demonstrating marked decreases in the release of labeled norepinephrine and acetylcholine in BoNT/A injected rat urethral sphincters [22]. While the therapeutic effects of inhibiting acetylcholine release are obvious, blockage of norepinephrine release may also provide clinical benefits by inhibiting sympathetic transmission and smooth muscle dyssynergia in the urethra. These results suggest that the therapeutic effect depends on both somatic and autonomic nerves.

In addition to classic neuropathic DESD, we have expanded the indications for use of botulinum A toxin to include patients with a variety of bladder outlet obstructions, excluding those patients with obstructions secondary to fibrosis. We have successfully used botulinum A

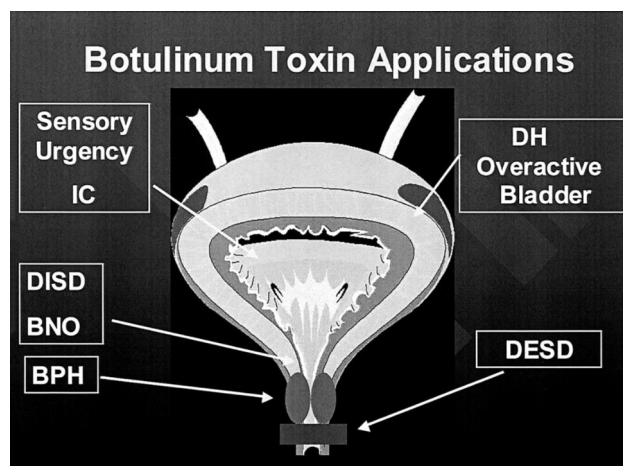


Fig. 3 Current and potential future targets for botulinum toxin within the lower urinary tracts. BNO, bladder neck obstruction; BPH, benign prostatic hyperplasia; DESD, detrusor external sphincter dyssynergia; DH, detrusor hyperreflexia; DISD, detrusor internal sphincter dyssynergia; IC, interstitial cystitis.

toxin to treat voiding dysfunction in multiple sclerosis patients with DESD, patients with pelvic floor spasticity, and even in an acontractile multiple sclerosis patient who wished to void by valsalva [20]. Recently, we reported a case of functional urethral obstruction and detrusor acontractility following pubovaginal sling surgery that was successfully treated by botulinum A toxin urethral sphincter injection [23].

We perform Botox[®] urethral sphincter injections by mixing one vial (100 units) of Botox[®] with 10 cc of saline just prior to injection. It is important not to shake the vial, as this may break the disulfide linkage between the light and heavy chains and render the toxin ineffective. Using a collagen injection needle (we prefer Cook[®] because of the sharper end), injections of 2.5 cc each are made at the 12, 3, 6, and 9 o'clock positions at the level of the striated sphincter. Injections must be directed deeper than collagen injections in order to target nerve terminals innervating skeletal muscle. We also flush the needle with 0.2 cc of saline at the end of the procedure to ensure that no toxin is wasted.

Bladder Application. Data have been accumulating on the clinical application of BTX-A to detrusor muscle in hyperreflexic bladders of spinal cord injured patients. A preliminary study by Schurch and colleagues in 31 patients with detrusor hyperreflexia demonstrated a significant increase in mean maximum bladder capacity (296 ml to 480 ml, $P < 0.016$) and a significant decrease in mean maximum detrusor voiding pressure (65 to 35 cm H₂O, $P < 0.016$) in patients injected with BTX-A [5]. A follow-up, long-term study completed by the same investigators in 87 patients with detrusor hyperreflexia corroborated the efficacy of intravesical botulinum toxin injection found in their earlier study [24]. In addition, they reported clinical responses lasting 4–14 months and observed no adverse effects with treatment. Detrusor muscle injections were performed in over 30 sites with either 300 units of Botox[®] or 500–750 units of Dysport[®]. The trigone was spared, presumably, to avoid the potential complication of vesicoureteral reflux.

In contrast, Del Popolo noted hyposthenia in 5/61 patients treated with high-dose intravesical BTX-A injections (300u of Botox[®] or 1000u Dysport[®]) [25]. The suprapubic weakness was transient in nature, disappearing 2–4 weeks after injection, and was abolished with lower dosage injections (500u Dysport[®]). Clearly, the dose and volume injected play a significant role in inducing systemic toxicity with BTX-A. Multiple injections of

lower doses would be expected to have a more localized and less systemic effect. However, the primary disadvantage of intravesical BTX-A injections for many urologists is the repeated cystoscopies and toxin injections that are necessary to maintain clinical results.

BTX-A injections have extended beyond the realm of neurogenic bladders to patients with non neurogenic voiding and storage disorders. Radziszewski and associates reported favorably on the effects of intravesical BTX-A injections in a pilot study of patients with either idiopathic bladder overactivity or functional outlet obstruction [26]. Following intravesical or sphincteric BTX-A injections, patients demonstrated a resolution of incontinence and improved voiding efficiency, respectively. Finally, Zermann and colleagues presented their experience with intravesical BTX-A injection in seven patients with severe urgency-frequency-syndrome refractory to anticholinergic therapy or electrical stimulation [27]. In contrast to other studies involving intravesical BTX-A injections, the authors' targeted the trigone and bladder base with 5–7 injections of 50, 100, or 200 units of Botox[®]. Four of seven patients responded to treatment with decreases in frequency and increased bladder capacity. No mention was made of vesicoureteral reflux as a complication of treatment.

We recently presented a single surgeon's experience using Botox[®] in the bladder and urethra in 50 patients for a variety of dysfunctions over the past 3 years [28]. Between October of 1998 and October 2001, 50 patients (age range 31–84) were injected with botulinum toxin into the bladder (n = 10) or urethra (n = 40). Of these, 19 were men and 31 were women. Voiding dysfunctions were a result of both neurogenic and non neurogenic conditions and included: multiple sclerosis, spinal cord injury, cerebral vascular accident, overactive bladder, interstitial cystitis, and dysfunctional voiding. Procedures were performed using light sedation. Patients were treated with either 100 units of Botox[®] divided in equal doses into the 4 quadrants of the external sphincter, or via injection into the bladder base using 100–300 units of botulinum toxin diluted in 20 ml of sterile saline. Presently, 15 of these patients have undergone further injections (as many as 4) at intervals of 6 months or more.

Maximal efficacy of botulinum injection was achieved within 7 days post injection. Analysis of the 50 patients indicates that 41 of 50 patients (82%) reported a decrease or absence of incontinence as well as a significant decrease in voiding symptoms. Sleep quantity and quality in-

creased in more than 50% of patients. Follow-up of these patients indicates that effects lasted up to 12 months. No patient developed stress incontinence or urinary retention.

These latest clinical findings are supported by research of ours and others demonstrating the efficacy of BoNTs on autonomic nerves [29–32]. Our study results indicate that the release of norepinephrine and acetylcholine was reduced by 60% and 64%, respectively in BoNT/A-treated versus control rat bladders [32].

Research Development

Botulinum Toxin Isoforms. An interesting side effect of patients with cervical dystonia injected with BTX-B (Myobloc™, Elan) is the development of dry mouth [33]. In a rare occurrence following BTX-A treatment, dry mouth was unexpected because the salivary glands were farther from the injection site than relatively unaffected lingual or lower facial muscles. This effect indicates that BTX-B may have a greater affinity for cholinergic nerves innervating the salivary glands rather than lingual or lower facial muscles or, alternatively, that there are more BTX-B receptors in salivary glands compared to muscles of the lower face and tongue. Future studies should clarify whether similar effects can be seen in parasympathetic cholinergic nerves innervating the lower urinary tract.

In addition, evidence from Carpenter's experiments in the late 1960s as well as that from our lab suggests that rat bladders are significantly more sensitive to the effects of BoNT/D than BoNT/A [29, 34]. In fact, Carpenter has found that parasympathetic blockade with BoNT/D occurs before somatic neuromuscular blockade. It remains to be seen whether these effects are merely due to differing sensitivities of various cholinergic nerve endings to different toxins, or whether BoNT/D's greater efficacy in the bladder is due to an effect on non cholinergic transmission. Currently, no data exist regarding whether these same differences in rat bladder sensitivity to toxin isoforms exist in the human bladder.

Afferent Nerve Effects. Several investigators have demonstrated *in vitro* evidence of an afferent effect of botulinum toxin. Welch and colleagues have reported that neuropeptide release from rat dorsal root ganglia is inhibited by botulinum toxin (BoNT/A, B, C1, F) treatment, while Purkiss and colleagues have noted that incubation of rat dorsal root ganglia with BoNT/A inhibits the release of radioactively labeled glutamate [35, 36]. The inhibi-

tion of transmitter release from nociceptive neurons could impair mechanisms involved with central sensitization and could position botulinum toxin as a therapeutic agent in conditions such as chronic pain.

Current *in vivo* studies support a role for BTX-A in relieving nociceptive pain. In a model of pain associated with formalin-induced inflammation, rats were pretreated in the hind paw with BTX-A prior to injection with formalin [37]. Formalin provokes pain via a direct stimulation of nociceptors (Phase I) and, subsequently, by inflammation (Phase II). Formalin was injected 5 and 12 days after BTX-A injection. Surrogate markers of pain included paw-licking and paw-lifting behavior. Pretreatment with BTX-A significantly reduced pain at 5 and 12 days post injection. These results support clinical observations that BTX-A has an antinociceptive effect that is independent of its effects on the neuromuscular junction.

We have preliminary results suggesting that BoNT/A treatment inhibits afferent nerve mediated bladder strip contractions, presumably by blocking neurotransmitter release from peripheral afferent nerve terminals in the bladder [38]. BoNT/A treatment was found to significantly decrease afferent nerve-mediated contractions in response to both electrical and chemical stimulation by 44.6% and 35.1%, respectively, compared to saline-treated animals ($P < 0.05$).

In addition, we have clinical experience with Botox® treatment in a 42-year-old female patient suffering from recalcitrant IC (personal observation). Under light sedation, following hydrodistension with saline (80 cm) for 5 min, 100 units of Botox®, diluted in 100 ml of saline, was instilled in the bladder and held for 30 min. The patient was discharged home the same day and followed up over the ensuing 6 months. One week following Botox® treatment, the patient noted a marked improvement in her voiding symptoms, characterized by decreased frequency, urgency, and urge incontinent episodes. Nocturia decreased four fold, and painful bladder symptoms diminished greatly as evidenced by a 50% decrease in oral pain medication usage. On a visual analog scale, the patient's bother score decreased from a 10 to a 5 following BTX-A treatment. Maximal therapeutic effects lasted 3 months, with some improvement still noted at 6 months post treatment. Our preliminary findings may lead to new therapeutic applications of BTX-A such as treating conditions associated with increased afferent nerve excitability (*i.e.* spinal cord injury,

chronic inflammation).

Clearly, BTX-A has a much wider spectrum of application within the urologic field than merely the treatment of DH and DESD in SCI patients. Treatment should be extended to other fields, including the MS population and those with non neurogenic voiding and storage disorders. Our basic research evidence that BoNT/A inhibits norepinephrine release in the rat bladder and urethra should prompt studies investigating the effects of botulinum toxin on disorders of increased sympathetic activity (e.g. functional bladder neck obstruction, detrusor internal sphincter dyssynergia, and BPH). Finally, if afferent nerve transmission is impaired by botulinum toxin, a significant patient population will be opened up to this treatment (Fig. 3).

Conclusions

Since the 1980s, injection of botulinum toxin has proven to be a safe and effective therapy for a variety of somatic and autonomic motor disorders. Urologists are now finding clinical success with urethral and bladder BTX-A injections in the treatment of detrusor-sphincter dyssynergia, non neurogenic pelvic floor spasticity, and refractory overactive bladder. Many interesting research questions remain regarding BTX's effects on the neural pathways of the lower urinary tract [39]. However, one cannot deny the ingenuity of man in transforming the lethal toxin of *Clostridium botulinum* into a modern-day therapeutic medicine.

References

- van Ermengem E: Ueber einen neuen anaeroben Bacillus and seine Beziehungen zum Botulismus. Ztsch Hyg Infekt (1897) 26, 1-56.
- Petit H, Wiart L, Gaujard E, Le Breton F, Ferriere JM, Laguery A, Joseph PA and Barat M: Botulinum A toxin treatment for detrusor-sphincter dyssynergia in spinal cord disease. Spinal Cord (1998) 36, 91-94.
- Dykstra DD, Sidi AA, Scott AB, Pagel JM and Goldish GD: Effects of botulinum A toxin on detrusor-sphincter dyssynergia in spinal cord injury patients. J Urol (1988) 139, 919-922.
- Dykstra DD and Sidi A: Treatment of detrusor-sphincter dyssynergia with botulinum A toxin: A double blind study. Arch Phys Med Rehabil (1990) 71, 24-26.
- Schurch B, Stohrer M, Kramer G, Schmid DM, Gaul G and Hauri D: Botulinum-A toxin for treating detrusor hyperreflexia in spinal cord injured patients: A new alternative to anticholinergic drugs? Preliminary results. J Urol (2000) 164, 692-697.
- Dickson EC: Botulism. A clinical and experimental study. Rockefeller Inst Med Res Mong (1918) 8, 1-25.
- Dolly JO: General properties and cellular mechanisms of neurotoxins; in Therapy with Botulinum Toxin, Jankovic J and Hallet M eds, Marcel Dekker, New York (1994) pp 153-268.
- Simpson LL: Peripheral actions of the botulinum toxins, in Botulinum Neurotoxin and Tetanus Toxin, Simpson LL ed, Academic Press, New York (1989) pp 153-178.
- Barinaga M: Secrets of secretion revealed. Science (1993) 260, 487-489.
- Schiavo G, Santucci A, Dasgupta BR, Mehta PP, Jontes J, Benfenati F, Wilson MC and Montecucco C: Botulinum neurotoxins serotypes A and E cleave SNAP-25 at distinct COOH-terminal peptide bonds. FEBS Lett (1993) 335, 99-103.
- Grazko MA, Polo KB and Jabbari B: Botulinum toxin A for spasticity, muscle spasms, and rigidity. Neurology (1995) 45, 712-717.
- Jankovic J, Schwartz K and Donovan DT: Botulinum toxin treatment of cranial-cervical dystonia, spasmodic dysphonia, other focal dystonias and hemifacial spasm J Neurol Neurosurg Psychiatry (1990) 53, 633-639.
- Scott AB: Botulinum toxin injection of eye muscles to correct strabismus. Trans Am Ophthalmol Soc (1981) 79, 734-770.
- Kolbasnik J, Waterfall WE, Fachnie B, Chen Y and Tougas G: Long-term efficacy of Botulinum toxin in classical achalasia: A prospective study. Am J Gastroent (1999) 94, 3434-3439.
- Schnider P, Binder M, Kittler H, Birner P, Starkel D, Wolff K and Auff E: A randomized, double-blind, placebo-controlled trial of botulinum A toxin for severe axillary hyperhidrosis. Br J Dermatol (1999) 140, 677-680.
- Lapides J, Diokno AC, Silber SJ and Lowe BS: Clean, intermittent self-catheterization in the treatment of urinary tract disease. Trans Am Assoc Genitourin Surg (1971) 63, 92-96.
- Koyanagi T, Morita H, Takamatsu T, Taniguchi K and Shinno Y: Radical transurethral resection of the prostate in male paraplegics revisited: Further clinical experience and urodynamic considerations for its effectiveness. J Urol (1987) 137, 72-76.
- Borodic GE, Joseph M, Fay L, Cozzolino D and Ferrante RJ: Botulinum A toxin for the treatment of spasmodic torticollis: Dysphagia and regional toxin spread. Head Neck (1990) 12, 392-399.
- de Paiva A, Meunier FA, Molgo J, Aoki KR and Dolly JO: Functional repair of motor endplates after botulinum neurotoxin type A poisoning: Biphasic switch of synaptic activity between nerve sprouts and their parent terminals. Proc Natl Acad Sci (1999) 96, 3200-3205.
- Phelan MW, Franks M, Somogyi GT, Yokoyama T, Fraser MO, Lavelle JP, Yoshimura N and Chancellor MB: Botulinum toxin urethral sphincter injection to restore bladder emptying in men and women with voiding dysfunction. J Urol (2001) 165, 1107-1110.
- Schurch B, Hauri D, Rodic B, Curt A, Meyer M and Rossier AB: Botulinum-A toxin as a treatment of detrusor-sphincter dyssynergia: A prospective study in 24 spinal cord injury patients. J Urol (1996) 155, 1023-1029.
- McNeil BK, Smith CP, Franks ME, Ghosh R, de Groat WC, Chancellor MB and Somogyi GT: Effect of botulinum toxin A on urethral neurotransmitter release: Implications on somatic/autonomic nerve transmission [Abstract]. J Urol (2001) 165, 277.
- Smith CP, O'Leary M, Erickson J, Somogyi GT and Chancellor MB: Botulinum toxin urethral sphincter injection resolves urinary retention after pubovaginal sling operation. Int Urogynecol J Pelvic Floor Dysfunct (2002) 13, 185-186.
- Schurch B, Stohrer M, Kramer G, Grosse J, Schmid D and Hauri D: Botulinum Toxin-A to treat detrusor hyperreflexia in spinal cord injured patients. NeuroUrol Urodyn (2001) 20, 521-522.
- Del Popolo G: Botulinum-A toxin in the treatment of detrusor hyperreflexia NeuroUrol Urodyn (2001) 20, 522-524.

26. Radziszewski P, Dobronski P and Borkowski A: Treatment of the non-neurogenic storage and voiding disorders with the chemical denervation caused by botulinum toxin type A- A pilot study. *Neurourol Urodyn* (2001) **20**, 410-412.
27. Zermann DH, Ishigooka M, Schubert J and Schmidt RA: Trigonum and bladder base injection of botulinum toxin A (BTX) in patients with severe urgency-frequency-syndrome refractory to conservative medical treatment and electrical stimulation. *Neurourol Urodyn* (2001) **20**, 412-413.
28. Chancellor MB and Smith CP: One surgeon's experience in 50 patients with botulinum toxin injection into the bladder and urethra [Abstract]. *J Urol* (2002) **167**, 249.
29. Carpenter FG: Motor responses of the urinary bladder and skeletal muscle in botulinum intoxicated rates. *J Physiol* (1967) **188**, 1-11.
30. Bigalke H and Habermann E: Blockade by tetanus and botulinum A toxin of postganglionic cholinergic nerve endings in the myenteric plexus. *Naunyn Schmiedebergs Arch Pharmacol* (1980) **312**, 255-263.
31. Mackenzie I, Burnstock G and Dolly JO: The effects of purified botulinum neurotoxin type A on cholinergic, adrenergic and non-adrenergic, atropine-resistant autonomic neuromuscular transmission. *Neuroscience* (1982) **7**, 997-1006.
32. Franks ME, Somogyi GT, Phelan MW, Fraser MO, Yokoyama T, Ghosh R, de Groat WC and Chancellor MB: Botulinum toxin injection into the bladder wall decreases acetylcholine (ACh) and norepinephrine (NE) release: Potential treatment for the overactive bladder [Abstract]. *J Urol* (2000) **163**, 42.
33. Aoki KR: Pharmacology and immunology of botulinum toxin serotypes. *J Neurol* (2001) **248** (Supple 1), 3-10.
34. Smith CP, Fraser MO, Ghosh R, Lu S-H, de Groat WC, Chancellor MB and Somogyi GT: Botulinum toxin D is more potent than botulinum toxin A in inhibiting bladder contractions. *APS 47th Annual Conference*, 2001.
35. Welch MJ, Purkiss JR and Foster KA: Sensitivity of embryonic rat dorsal root ganglia neurons to *Clostridium botulinum* neurotoxins. *Toxicon* (2000) **38**, 245-258.
36. Purkiss JR, Welch MJ, Doward S, Foster KA and Quinn CP: A method for the measurement of [³H]-glutamate release from cultured dorsal root ganglion neurons. *Biochem Soc Trans* (1998) **26**, S108.
37. Cui M and Aoki KR: Botulinum toxin type A (BTX-A) reduces inflammatory pain in the rat formalin model. *Cephalgia* (2000) **20**, 414.
38. Smith CP, Fraser MO, Bartho L, de Groat WC, Chancellor MB and Somogyi GT: Botulinum toxin A inhibits afferent nerve evoked bladder strip contractions [Abstract]. *J Urol* (2002) **167**, 41.
39. Smith CP, Somogyi GT and Chancellor MB: Botulinum toxin: Poisoning the spastic bladder and urethra. *Rev Urol* (2002) **4**, 61-68.