

Acta Medica Okayama

Volume 11, Issue 4

1957

Article 6

DECEMBER 1957

Dysuria following hysterectomy

Kazuo Saratani*

*Okayama University,

Copyright ©1999 OKAYAMA UNIVERSITY MEDICAL SCHOOL. All rights reserved.

Dysuria following hysterectomy*

Kazuo Saratani

Abstract

In the observations of the pelvic nerves both in the reconstruction model of the pelvis of newborn and that of the extirpated specimen after OKABAYASHI's hysterectomy as well as in the observations of pelvic nerves at autopsy, it has been verified that the vesical nerves are extensively extirpated and severed by the radical extensive hysterectomy for cancer of the uterus. Moreover, the micturitional functions after the disruption of communication with the center of micturition in the spinal cord seem to be undertaken by lower peripheral reflex arches located in the vesical wall and in the periurethral region. Therefore, for the recovery of postoperative urinary disturbances, systemic findings as well as findings on the vesical wall seem to be quite important.

Acta Med. Okayama 11, 338—346 (1958)

DYSURIA FOLLOWING HYSTERECTOMY

Kazuo SARATANI

*Department of Obstetrics and Gynecology Okayama University
Medical School, Okayama, Japan
(Director : Prof. Hideo Yagi)*

Received for Publication, September 30, 1957

It is generally accepted that the injury on the micturition nerve during the operation is mainly responsible for the dysuria following the radical extensive hysterectomy for carcinoma of the cervix.

HONDA¹ made report in 1938 on the urinary disturbances after extensive hysterectomy for carcinoma of the cervix showing reconstruction models of parametrial nerves in the specimens extirpated by OKABAYASHI's method and of pelvic nerves of the five-month old embryo as well as the results of macroscopic observations on the pelvic nerves at autopsy. The author presents here the results of observations conducted in a more or less similar manner.

OBSERVATIONS

1. *The three-dimensional stereometric observations of the pelvic nerves in the newborn corpse by a reconstruction model (Plate 1, Figs. 1, 2):* The material for study was obtained from a newborn female born on the 301st gravid day, that weighed 2,650 grams at the time of birth but died the next day of the newborn melena; namely, a chunk of tissues consisting of the uterus, vaginal wall, the bladder, parametrium and ureter as a whole taken out by laparotomy. Sections were prepared into serial sections of 50 μ thick and nerves with diameter over 150 μ were illustrated. The models thus constructed are each 20 times the original height and width as shown in plate 1, Figs. 1 and 2. In the Plate 1, Fig. 1 the upper part shows the side of the uterus and the lower part the pelvic wall, while the upper right half shows the cervix of the uterus, the extreme right the vagina, the left half the bladder, the anterior part facing the photo is the posterior wall of the bladder and the vesicouterine fosse is illustrated at a greater angle than normal.

A big pillar in the middle shows the ureter. There are two cords of nerve fascicles originating anteriorly to the ureter and independently of the utero-vaginal plexus to be described later, part from the parametrium

but run separately on its exterior side the outer one runs alone outside the parametrium to the bladder wall while the other approaching the ureter approximately at the middle runs parallel to the ureter and at a little anterior part of the ureter joins with a branch from utero-vaginal plexus and then enters into the bladder neck. Next, the nerve fascicles that join the utero-vaginal plexus originate from five sites on the pelvic wall, namely, four on the right side of the ureter and one immediately left side of the ureter, and advancing inward they all become united to form a big strong utero-vaginal plexus in the central part. This plexus, as it goes further inward, spreads out radially and sends out many branches; and the majority of these branches enter into the wall of the cervix and the vagina. A part, sending out branches, enters into the bladder at the point just exterior inferior the site where the ureter enters into the bladder nerve already mentioned running towards the bladder neck in line with the ureter (Plate 1, Fig. 2). The nerves penetrating into the wall of bladder neck are only a few in number.

2. *Observations on the parametrial nerves with a reconstruction model from the extirpated specimen after OKABAYASHI's hysterectomy (Plate 1, Fig. 3)*: The material employed in the experiment was a fresh cervical cancer of second stage removed from woman fifty-two and four months old with the history of six deliveries, after OKABAYASHI's radical extensive hysterectomy performed on February 22, 1955.

As for the findings at the time of operation, a moderate infiltration in the left parametrium was recognized but hardly any in its right parametrium and metastasis of lymphnodes as large as the tip of the thumb was observed in the left parametrium; and the diagnosis after operation was cancer of the cervix in Stage III. Immediately after extirpation, by separating the right parametrium from the uterus and fixing it as much in natural condition as possible, a wax model of reconstruction was prepared as in the precious case. As shown in Fig. 3, the upper part shows the wall of uterus and the ground part shows the side of the pelvis, and the right hand side facing the photo is the anterior part of the parametrium, the left hand side of the photo the deep interior part, the front of the photo the outer portion of the parametrium, respectively. The nerve fascicle, originating from four places on the side of pelvis of the extirpated parametrium and forming in the middle part of stump the nerve plexus (utero-vaginal plexus) which consists of big nerve fascicle with large ganglion cells, sends out more and more branches as it approaches the side of uterus; and although it runs straight to the uterus with its small branches intermingling with one another, at the side of uterus these

branches separate into two groups, the one running towards the vagina (the left upper part facing the photo) and the other in the direction of the uterin cervix and vesicouterine ligament (the upper right hand side facing the photo).

3. *Anatomical observations of pelvic nerves in female corpse (Plate 2, Figs. 1 and 2)*: The iliac plexus descended from aortic plexus, dividing itself into two groups of right the left nerve fascicles in front of the sacral promontory, descends still further along the direction of branches of the superior gluteal artery branching out from the internal iliac artery at the inner surface of the pelvis, or runs in the direction of superior gluteal vein branching out from the internal iliac vein; and first it runs in the exterior posterior direction and then runs through the periproctal connective tissue in the direction a little inwards and forms a big sturdy nerve plexus, the utero-vaginal plexus, along the inner side of cardinal ligament at about the level of the cervix of uterus between the rectum and the side wall of pelvis. In the meantime into the utero-vaginal plexus enter nerve fibers (those from S₃ and S₄ are big) branching from the sacral nerves S₁, 2, 3, and S₄ and nerve fibers of the sympathetic trunk situated in front of the sacrum. The nerve fibers that constitute the utero-vaginal plexus are the nerve fibers derived from the iliac plexus, the sympathetic trunk, and the sacral nerve. The main trunks from the iliac plexus (hypogastric plexus), constituting the anterior exterior portion of the utero-vaginal plexus and forming network in the central part of the cardinal ligament, are distributed radially from the side wall of the cervix of uterus and from the exterior inferior part of ureter on the side wall of the bladder along with numerous venous branches; and a part, sending out small branches to the ureter. The big sturdy nerve trunk, constituting the posterior interior part of the utero vaginal plexus, communicate with nerve fibers from S₂, 3, 4, and a part of the most low interior fascicles is sended to rectum wall while the majority of them are distributed radially from the side a little posterior and exterior to the nerve trunk (aforementioned) distributed on the side wall of the bladder and on the wall of vagina together with uterine veins.

The width of center part of the utero-vaginal plexus measured about 2 cm., the distance from the central part of the nerve plexus to the outer wall of uterine cervix was 3 cm. while from the exterior margin of the nerve plexus to the outer wall of uterine cervix measured 5.5 cm.

COMMENT

Recently the construction of muscle layer of the bladder and the mechanism of micturition have come to be rescrutinized ; for example, the internal sphincter, being an elongation of diuretic muscle, is considered to be consisted primarily of the same unstriated muscle fibers and the opening of internal urethral meatus at the time of urination is not controlled by relaxation of the internal sphincter. Furthermore, it is generally believed that the sympathetic and the parasympathetic nerves do not act antagonistically against these muscles. According to description of text books, the outlay of nerve distribution in the bladder is as follows. Parasympathetic nerve fibers are mainly contained in the pelvic nerve and the nerve center is within the sacral marrow, while sympathetic nerve fibers are contained in the hypogastric nerve and its center within the thoracolumbal marrow. Both these nerve fibers, constituting utero-vaginal plexus at the posterior lateral side of the uterus, sends out branches from the plexus to the uterus, vagina and the rectum but the anterior parts of these fibers further reach both sides of the fundus of bladder to form vesical plexus, and the intramural ganglions are said to lie in the vesical wall. The spinal cord center for micturition reflex is located within sacral marrow but it is also controlled by the center still further up ; and when the vesical wall dilatates to a certain extent the centripetal stimulus from the posterior root being transmitted to the reflex center and the stimulus further being relayed to motor branches by way of the anterior root, the contraction of diuretic muscle takes place ; and although opinions on the working conditions of the diuretic muscle, perineal muscle and sphincter as well as of the order in which they act are variegated, it is generally accepted that the parasympathetic nerve plays a role in enhancing urination.

On the other hand, it is easily conceivable that pelvic nerves are unavoidably injured in the case of radical extensive hysterectomy for cancer of the cervix and as already mentioned HONDA¹ actually demonstrated this point with reconstruction model of extirpated specimen. Likewise in my experiment numerous pelvic nerves were found actually contained in the parametrium extirpated following radical extensive hysterectomy. In the same operation while detaching the rectum and exposing the pararectal cavity prior to the dissection of cardinal ligament, a part of the hypogastric plexus is severed ; and while separating the connective tissue fibers inside the cardinal ligament, the nerve fascicls originating from the sacral nerve are severed ; and at the time to dis-

secting the cardinal ligament as the groups of nerve plexus entering into the ligament from the pelvic wall conglomerate together, the very uterovaginal plexus themselves are found all cut into two. It has been revealed in an embryonal specimen model that the majority of vesical nerves that branch out from uterovaginal plexus pass the exterior inferior side of ureter before reaching the vesical wall. Consequently in the dissection of the posterior layer of the vesico-uterine ligament this nerve plexus is severed just before the site where it enters vesical sidewall. Namely, in the radical extensive hysterectomy the sympathetic and the parasympathetic nerve fibers distributed in the bladder are practically almost all severed, and after the operation retention of urine as well as paralysis of normal micturition occurs.

Although the nerves distributed in the rectum are likewise partly severed and become a source for disturbance of defecation, and the striated sphincter is controlled by the internal pudendal nerve (voluntary) and usually it is not injured at the time of operation, practically no absolute incontinence of urine is brought about directly by operation. As is evident from the above, postoperative disturbances of micturition lie mainly in organic factors. Usually retention of urine occurs during about two weeks after operation and the retained urine decreases around the fourth week. But on the other hand irrespective of stages of cancer (Stages I and II), the intensity of urinary disturbances frequently has been found to show a considerable variation even in the cases to which the operations and postoperative micturitional treatments were given overall systematically. Concerning this point, HONDA² claims that it is dependent on the degree of injury at the time of operation to the autonomic nerves distributed in the bladder, and YASUI³ presumes that it must be considered in correlation with postoperative treatments of the bladder, while YASUNAGA³ states that micturition is associated with stages of cancer and existence or non-existence of vesical infiltration as well as with postoperative complication of pyelocystitis. According to the results of my postoperative statistical examinations in our laboratory in the cases of postoperative complications such as urinary tract infection and retroperitoneal infection, patients with severe urinary disturbances have been found to increase in number, but no significant relationship can be recognized between stages of cancer and the length of time consumed in operation on one hand and duration of urine retention and severity of urinary disturbance on the other.

No matter how overall and systematic postoperative treatments may be, some slight discrepancies in minor points will unavoidably arise; but

it seems that changes brought directly upon the vesical wall itself and accuracy in systemic as well as local postoperative findings will have an important bearing on the function of micturition. MÜLLER⁵ states that when the normal function of the bladder is disrupted, the intramural ganglion will exhibit its autonomy, and TANAHASHI⁶ maintains that the recovery of the function of micturition after radical extensive hysterectomy is dependent upon an increased in the contraction power of the diuretic muscle due to the recovery of accommodation functions in urethral sphincter as well as in the ganglion of vesical wall. More recently MCCREA⁷ states that there is a vesical nerve different from the one commonly known to reach the bladder along with pelvic-wall blood vessels and that this nerve system manages the functions of bladder in the case of emergency such as an injury to the pelvic plexus. Even in the case in which postoperative retention of urine has been eradicated and the micturitional function has turned for the better, it must be conceded that the real functional efficiency can not be sufficiently functioning for a long period of time after radical extensive hysterectomy. The gradual recovery of micturitional function, though not complete, along with lapse of time after the retention of urine brought about by severance of the reflex arch of spinal cord seems to lie in the fact that the intramural ganglion assumes the management of micturitional function in place of the reflex arch though not so efficiently; and the function of micturition after the severance of reflex arch of spinal cord may be thought to be managed in turn by the peripheral reflex arch included in the nerve constructions locating in the vesical wall and in the neighborhood of urethra. Therefore, the degree of damage to the vesical wall at the time of operation and inflammatory mechanism as well as cicatricial changes of perivesical region after operation seem to be intimately related to the recovery of micturitional function after operation.

SUMMARY

In the observations of the pelvic nerves both in the reconstruction model of the pelvis of newborn and that of the extirpated specimen after OKABAYASHI's hysterectomy as well as in the observations of pelvic nerves at autopsy, it has been verified that the vesical nerves are extensively extirpated and severed by the radical extensive hysterectomy for cancer of the uterus. Moreover, the micturitional functions after the disruption of communication with the center of micturition in the spinal cord seem to be undertaken by lower peripheral reflex arches located in

the vesical wall and in the periurethral region. Therefore, for the recovery of postoperative urinary disturbances, systemic findings as well as findings on the vesical wall seem to be quite important.

ACKNOWLEDGEMENTS

The author is greatly indebted to Prof. Yagi and Ass. Prof. Hashimoto for their valuable advices and proof reading in preparation of this manuscript and wishes also to express his deep gratitude to Prof. Ouchi and Dr. Fujimoto of the Department of Anatomy for making it possible for me to perform autopsies in their laboratory.

REFERENCES

1. HONDA, M. : Pelvis-neurogenic dysuria. *Kurashiki Chuo Byoin Nenppo* 12, 2, 1938 (in Japanese)
2. HONDA, M. : Pelvis-neurogenic dysuria. *Sanfu-Jissai* 2, 1070, 1953 (in Japanese)
3. YASUI, Sh. : Dysuria after the radical operation of the cervical uterine cancer. *Sanfu-Jissai* 1. 199, 1952 (in Japanese)
4. YASUNAGA, T. : On the changes of bladders following the radical operation the cervical uterine cancer. *Nissanfu-Shi* 5, 395, 1953 (in Japanese)
5. MÜLLER, L. R. : Die Blaseninnervation. *Deutsch Arch. f. klin. Med.* 128, 81, 1919
6. TANAHASHI, K. : The clinical studies on the function of the bladder following the extensive hysterectomy for cancer of the uterine cervix. *Sanfu Kiyo* 22, 1280, 1939; 25, 105, 1942 (in Japanese)
7. McCREA, E. : New concept of vesical innervation, *Amer. Med. Asos. Arch. Surg.* 66, 84, 1953

LEHEND OF PLATES

Plate 1.

- Fig. 1. Reconstruction model of pelvic nerves of newborn; the upper shows the uterus side and the lower, the pelvic wall side.
- Fig. 2. Reconstruction model of pelvic nerves of newborn; big pillar in the middle is the ureter.
- Fig. 3. Reconstruction model of parametrial nerves in the specimen after Okabayashi's hysterectomy; the upper shows the uterus side, the low, the pelvic wall side. The right is the anterior part and the left, the interior part.

Plate 2.

- Fig. 1. Specimen. Corpus uteri and A. and V. uterina had been removed.
- Fig. 2. Diagram of Fig. 1.

Dysuria Following Hysterectomy

Plate 1.




Fig. 1.




Fig. 2.



Fig. 3.

Plate 2.

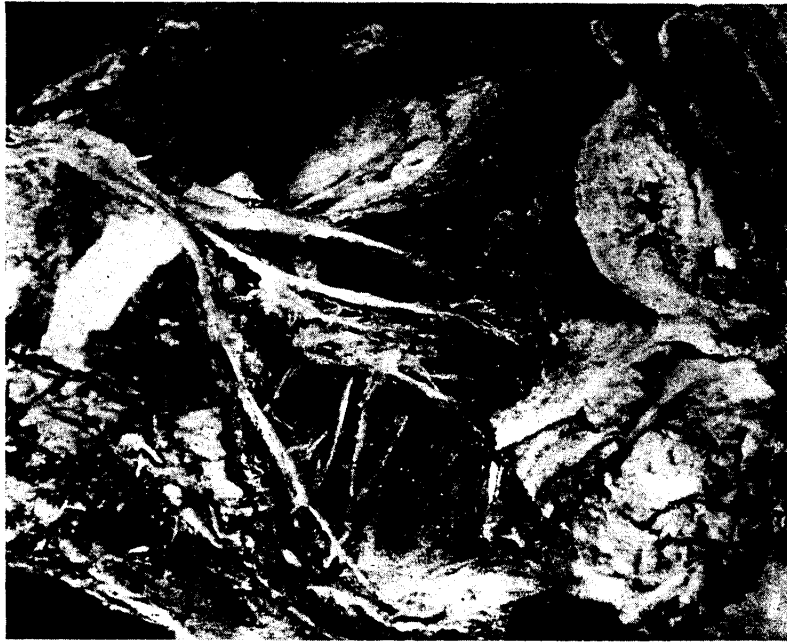

Fig. 1.

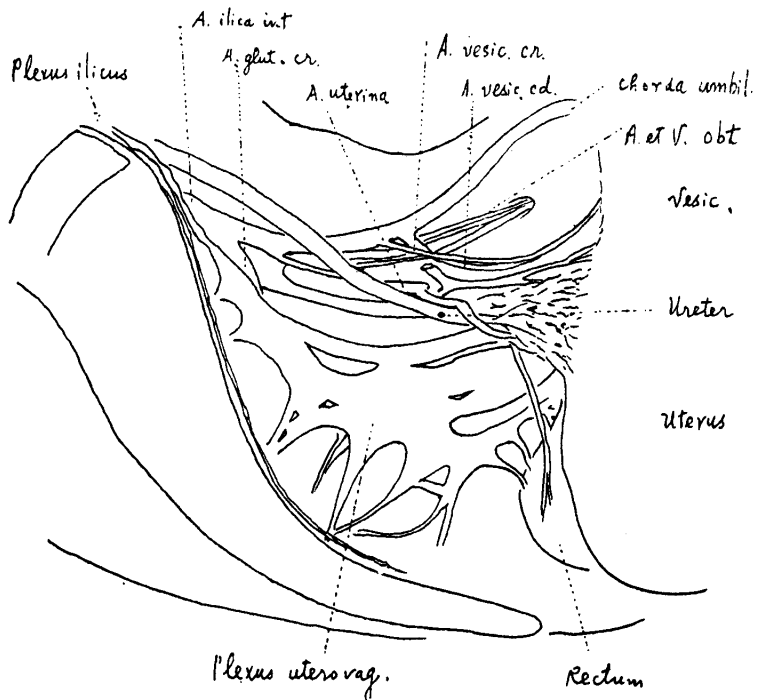


Fig. 2.