Acta Medica Okayama

Volume 47, *Issue* 6 1993 *Article* 7

DECEMBER 1993

Diagnosis of Rejection in the Allografted Rat Lung: Using Monoclonal Antibodies to T Cell Subsets for Immunologic Monitoring

Shuichirou Maruyama* Yoshifumi Sano† Hiroshi Date‡
Nobuyuki Shimizu** Shigeru Teramoto††

*Okayama University,
†Okayama University,
‡Okayama Univerisity,
**Okayama University,
††Okayama University,

Copyright ©1999 OKAYAMA UNIVERSITY MEDICAL SCHOOL. All rights reserved.

Diagnosis of Rejection in the Allografted Rat Lung: Using Monoclonal Antibodies to T Cell Subsets for Immunologic Monitoring*

Shuichirou Maruyama, Yoshifumi Sano, Hiroshi Date, Nobuyuki Shimizu, and Shigeru Teramoto

Abstract

Early diagnosis of rejection and timely immunosuppression are absolutely important in clinical lung transplantation. We studied surface markers of peripheral blood lymphocytes (PBL), graft infiltrating lymphocytes (GIF) and bronchoalveolar lavage fluid (BALF) in a rat using flow cytometric monitoring to diagnose rejection. Left lung transplantation was performed on Brown Norway (BN) rats and Lewis (LEW) rats in the following groups; Group 1: LEW-LEW (isograft), Group 2: BN-LEW (allograft; no immunosuppression), Group 3: BN-LEW (allograft; treated with Cyclosporine A at a dose of 15 mg/kg/day i.m.). In each group, rats were killed 3, 5, 7 days postoperatively (n = 6 on each day). Monoclonal antibodies investigated in this study were W3/25 (anti-helper T lymphocyte), OX8 (anti-suppressor/cytotoxic T lymphocyte), and OX39 (anti-interleukin 2 receptor). Histological classification of rejection in Group 2 showed vascular phase at 3 days, alveolar phase at 5 days, and destructive phase at 7 days, respectively. No evidence of rejection was found in Group 1 or 3. In Group 2, W3/25 positive cell proportion in GIL and BALF significantly decreased as the rejection progressed, but OX8 positive and OX39 positive cell proportion increases were significantly greater than in Groups 1 and 3 as the rejection progressed. These results lead us to speculate that the studies of T cell subsets in GIL and BALF lymphocytes are useful for diagnosis of rejection in lung transplantation.

KEYWORDS: lung transplantation, rejection, lymphocyte subsets, flow cytometry, BALF

---

*PMID: 8128914 [PubMed - indexed for MEDLINE]
Copyright (C) OKAYAMA UNIVERSITY MEDICAL SCHOOL

Acta Med Okayama 47 (6) 399-406 (1993)

Diagnosis of Rejection in the Allografted Rat Lung: Using Monoclonal Antibodies to T cell Subsets for Immunologic Monitoring

Shuichiro Maruyama*, Yoshifumi Sano, Hiroshi Date, Nobuyoshi Shimizu and Shigeru Teramoto

Second Department of Surgery, Okayama University Medical School, Okayama 700, Japan

Early diagnosis of rejection and timely immunosuppression are absolutely important in clinical lung transplantation. We studied surface markers of peripheral blood lymphocytes (PBL), graft infiltrating lymphocytes (GIF) and bronchoalveolar lavage fluid (BALF) in a rat using flow cytometric monitoring to diagnose rejection. Left lung transplantation was performed on Brown Norway (BN) rats and Lewis (LEW) rats in the following groups; Group 1: LEW-LEW (isograft), Group 2: BN-LEW (allograft; no immunosuppression), Group 3: BN-LEW (allograft; treated with Cyclosporine A at a dose of 15mg/kg/day i.m.). In each group, rats were killed 3, 5, 7 days postoperatively (n = 6 on each day). Monoclonal antibodies investigated in this study were W3/25 (anti-helper T lymphocyte), OX8 (anti-suppressor / cytotoxic T lymphocyte), and OX39 (anti-interleukin 2 receptor). Histological classification of rejection in Group 2 showed vascular phase at 3 days, alveolar phase at 5 days, and destructive phase at 7 days, respectively. No evidence of rejection was found in Group 1 or 3. In Group 2, W3/25 positive cell proportion in GIL and BALF significantly decreased as the rejection progressed, but OX8 positive and OX39 positive cell proportion increases were significantly greater than in Groups 1 and 3 as the rejection progressed. These results lead us to speculate that the studies of T cell subsets in GIL and BALF lymphocytes are useful for diagnosis of rejection in lung transplantation.

Key words : **lung transplantation, rejection, lymphocyte subsets, flow cytometry, BALF**

Lung transplantation has become a useful therapeutic option for patients with end-stage lung disease (1). Improved operative techniques and the introduction of cyclosporine for immunosuppressive therapy in lung transplant recipients have led to a worldwide increase in the survival of these recipients (2, 3).

Investigation of the development of the rejection response is necessary to solve some of the basic problems in early diagnosis and management of allograft rejection. In lung transplantation, rejection is sometimes confirmed by histological examination using specimens obtained from an open biopsy (4, 5), however, this is not a completely safe procedure in the clinical setting. The development of an accurate and safe diagnostic method for identifying the onset of rejection and assessing the damage to grafted lungs is therefore essential.

To monitor the early stage of lung rejection, we studied the intragraft event by flow cytometric analysis of surface markers.

Materials and Methods

Rats. For this study, specific pathogen-free male inbred rats of Brown Norway (BN) ($RT1^n$) and Lewis (LEW) ($RT1^l$), weighing 250-300g, were selected. They were purchased from Charles-River Co., Atsugi, Japan). All animals received humane care in compliance with the "Principles of Laboratory Animal Care" published by the National Society for Medical Research and the "Guide for the Care and Use of Laboratory Animals" (National Institutes of Health Publication No.85-23, revised 1985).

* To whom correspondence should be addressed.

Produced by The Berkeley Electronic Press, 1993

Transplantation. To perform orthotopic left lung transplantation in the rat, we have modified surgical techniques described by other investigators (6, 7). The rats were anesthetized by inhalation of ether. Then the rats were premedicated with an intramuscular injection of atropine (0.25 mg/kg) and anesthetized with an intraperitoneal administration of pentobarbital (20 mg/kg) and ketamine (25 mg/kg). After orotracheal intubation with a 6.4 cm 16-gauge angiocatheter, the lungs were ventilated with room air at a tidal volume 2.5 to 3.0 ml and respiratory rate 70 to 100 breaths/min. Positive end-expiratory pressure was adjusted to 2-5 cm H_2O. Operating glasses (3.5 X) were used for the procedure. The operation was performed with a clean technique by a single surgeon. The donor was placed in the supine position and a median sternotomy was performed. The inferior pulmonary ligament was carefully divided. Heparin (1,000 units/kg) was injected intravenously. The donor's heart and lungs were then removed en bloc. The heart-lung block was wrapped in a bed of gauze soaked with 0°C preservation, placed in a plastic container surrounded by ice, and stored in a refrigerator. The organs were thus maintained at 0 °C for the duration of the ischemic storage period. Before implantation, the left pulmonary artery, pulmonary vein, and main bronchus were dissected to permit procurement of a graft when needed. A cuff was attached to the pulmonary artery first. The cuffs were made from segments of 16-gauge polyethylene tubing and consisted of a body 2 mm in length and a 1 mm extension. The donor pulmonary artery was passed through the cuff with the extension directed to the backside of the vessel. The proximal end of the vein was everted over the cuff and then firmly fixed with a circumferential ligature of 6-0 silk. The pulmonary vein was cuffed in the same way. The recipient was then anesthetized, incubated, and ventilated with the same procedure and ventilation as the donor. The recipient was placed in the left-side-up position and a left thoracotomy was performed at the fourth intercostal space. The hilum was dissected and the bronchus was ligated with 4-0 silk and transected as distally as possible. The pulmonary artery and pulmonary vein were successively cross-cramped with microvessel clips, incised peripherally at the anterior wall, and rinsed with heparinized saline to prevent thrombosis, while the hilum was secured with a clip to block the backflow from the left lung. The cuff of the graft pulmonary artery was inserted into the incised pulmonary artery of the recipient and complete the anastomosis. The pulmonary vein was connected to the graft in the same way, after which the cross-clamp was removed and reperfusion was established.

The cuff for the bronchial anastomosis consisted of a cuff body, 1.0 mm in length, and a 3.0 mm cuff extension. The inside diameter was 1.7 mm. The open end of the left main bronchus of the recipient was passed through the cuff, everted and ligated with an 8-0 polypropylene circumferential suture, inserted into the graft bronchus, and completed with a 6-0 silk circumferential ligature. The extension was cut off to avoid compression of the residual bronchus. The thorax was closed after grafting. A drain was left in the pleural cavity, the ribs were joined by four interrupted sutures of 3-0 silk, and the muscles and skin were sutured by 3-0 silk. The rat was disconnected from the respirator and started breathing room air spontaneously.

Experimental protocol. Rats with transplants were divided into three groups; Group 1: lung isograft (LEW-LEW); Group 2: lung allograft without immunosuppression (BN-LEW); and Group 3: lung allograft with cyclosporine (CyA) at a dose of 15 mg/kg/day injected intramuscularly. In each group, rats were killed 3, 5, 7 days postoperatively (n = 6 on each day).

Histological examination. The basal half of the graft lung was fixed by 10 % neutral buffered formaline and stained with hematoxyline and eosin for microscopic examination. Histological examination was done without knowledge of the individual protocol, and changes were assigned to a rejection phase based on the classification of Prop *et al.* (8, 9). The latent phase shows no evidence of rejection. The vascular phase has perivenous lymphocytic infiltration (early) or periarterial and peribronchial cuffs of lymphocytes and immunoblasts (late) with a marked increase in bronchus associated lymphoid tissue (BALT). The alveolar phase has prominent perivascular and peribronchial cuffs if there was focal extension into the interstitium by mononuclear cells, intra-alveolar and pleural mononuclear cells (early, cellular), and intra-alveolar neutrophils and edema (late, edematous). The destructive phase shows necrosis of pulmonary parenchyma, often with hemorrage.

Flow cytometric analysis. Lymphocytic surface marker analysis by flow cytometry with the use of an electronically programmable indivisual cell sorter (EPICS, model 753; Coulter Electronic Co., Hialeah, Fla, USA) was performed using peripheral blood lymphocytes (PBL), graft infiltrating lymphocytes (GIL) and bronchoalveolar lavage fluid lymphocytes (BALF).

PBL and BALF preparation. Under slight anesthesia with inhalation of ether, 2 ml of peripheral blood was collected from the inferior vena cava. BALF was obtained by washing the graft with 1 ml of saline which was injected into the graft's bronchus and aspirated. This procedure was repeated until the amount of collected BALF reached 5 ml. PBL was prepared from heparinized blood using Lympholyte-R (Cedarlane Lavoratories Limited, Hornby, Ontario, Canada). Blood was overlaid on Lympholite-R and centrifuged at 2,200 rpm for 30 min at room temperature. The layer of lymphocytes was carefully aspirated. Lymphocytes were suspended in Roswell Park Memorial Institute (RPMI) 1640 culture medium containing 1 % fetal serum and 0.1 % NaN_2. BALF was also separated in the same way.

GIL preparation. A small segment of graft lung was minced in a tissue homogenizer, and cells were released according to the technique described by Totterman *et al.* (10). The tissue homogenate was incubated with 3 ml of digestion medium (20 mmol/l HEPES buffer solution from Sigma, 136 mmol/l NaCl, 4.7 mmol/l KCl, 0.65 mmol/l $MgSO_4$, 1.2 mmol/l $CaCl_2$, PH 7.45) containing collagenase 2 mg/ml, DNAse 0.05 mg/ml and 1.5 % bovine serum albumin. After agitation and incubation at 37°C for 1 h, cells were filtered through nylon mesh (100 μm) to remove aggregates and overlaid on Lympholite-R. Thereafter centrifugation at 2,200 rpm for 30 min made a clear lymphocytic layer, and

these cells were carefully aspirated and suspended in the same type of medium as PBL and BALF (11, 12).

Antibody incubation. The lymphocyte suspensions of PBL, GIL or BALF were incubated with the optimal concentration of monoclonal antibodies (Sera-Lab Limited, Sussex, UK) at 4°C for 30 min in a dark incubation chamber. The following lymphocyte surface markers were studied: W3/25 anti-helper T lymphocyte antibody labelled with fluorescein (FITC), OX8 anti-suppressor/cytotoxic T lymphocyte antibody labelled with phycoerythrin (PE), OX39 anti-interleukin-2 receptor labelled with FITC (Table 1). The combination of the antibodies, W3/25 with OX8 was doubly stained and submitted to two-color flow cytometric analyses. And OX39 was stained singly. The cells were gated optimally by forward scatter (cell size) and lateral scatter (granularity) for lymphocytes. Appropriate filters, 560 nm short-pass filter for FITC and 590 nm long-pass filter for PE, used in the analysis. All statistical analyses were performed by ANOVA test (13). Statistical significance was accepted at 95% confidence limit, $p < 0.05$. All values were presented as mean ± standard deviation.

Table 1 Panel of monoclonal antibodies (Ab) used in this study

Monoclnal Ab	CD design	Cell specificity
W3/25	CD4	T helper/inducer
OX8	CD8	T suppressor/cytotoxic
OX39	CD25	anti-interleukin 2 receptor (IL2-R)

Results

Histological findings. Histological examination of allograft tissues recovered from Group 2 rats at day 3

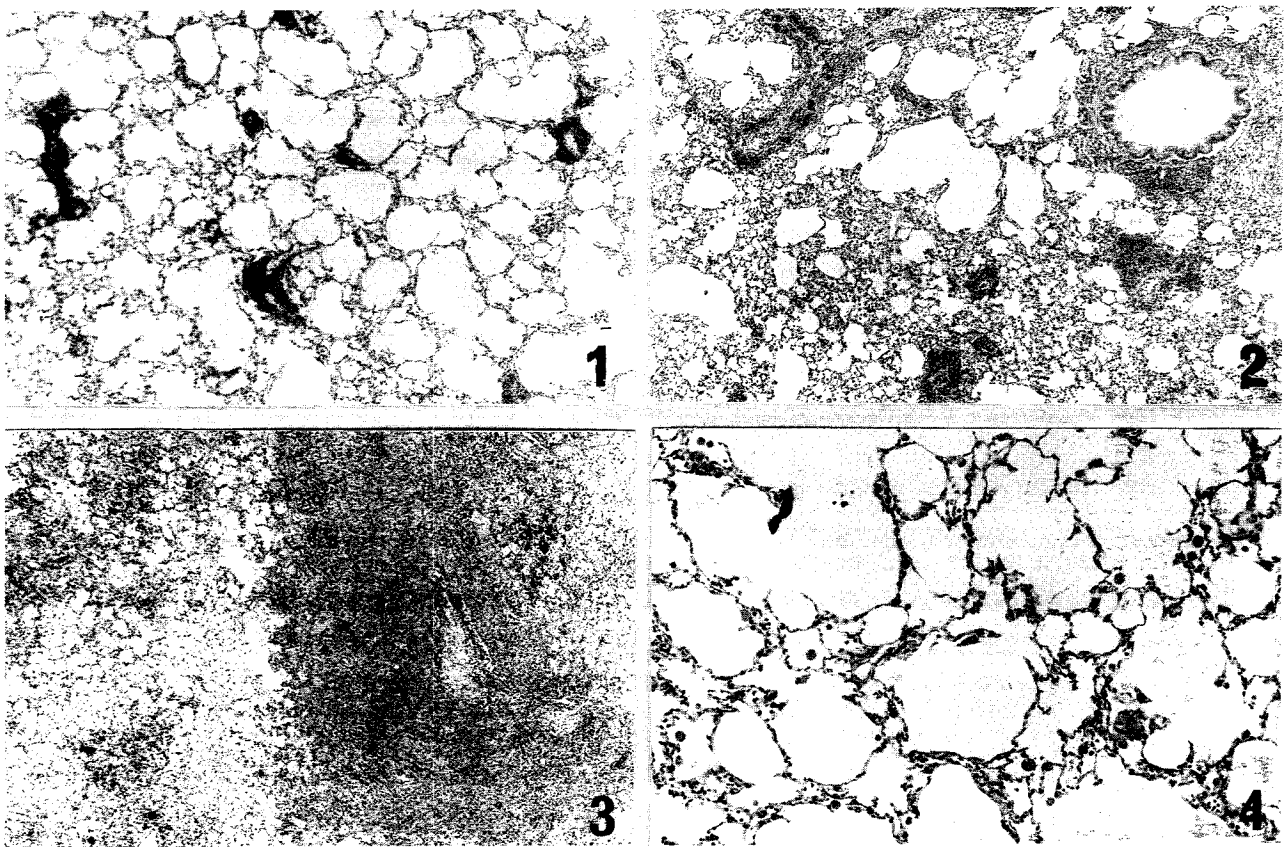

Fig. 1 Photomicrograph of a rat lung from Group 2 sacrificed three days after transplantation. Some of the vessels are surrounded by cuffs of mononuclear cells. The alveolar walls are not infiltrated in this phase (H & E, × 32). Vascular phase of rejection.

Fig. 2 Photomicrograph of a rat lung from Group 2 five days after transplantation. Infiltrating cells have formed thick, coalescent cuffs around vessels and bronchi. The alveolar walls are thickened and the alveolar spaces contain increased numbers of intraalveolar cells (H & E, × 32). Alveolar phase of rejection.

Fig. 3 Photomicrograph of a rat lung from Group 2 seven days after transplantation. The alveolar spaces eventually filled with fibrinous edema and erythrocytes. The cellular infiltrates have been thinned by necrosis (H & E, × 32). Destructive phase of rejection.

Fig. 4 Photomicrograph of a rat lung from Group 3 five days after transplantation. A scant perivascular and peribronchiolar infiltrate of mononuclear cells (H & E, × 32). No evidence of rejection.

after transplantation showed the presence of prominent perivascular and peribronchiolar cuffs induced by mononuclear cell infiltration. The alveolar walls had not infiltrated in the vascular phase of rejection (Fig. 1). At day 5, allografts showed dense cuffing around vessels by lymphoid cell infiltration which extended into the alveolar septa and into adjacent air spaces (alveolar phase) (Fig. 2). At day 7, extensive destruction of the lung parenchyma was observed, and the intensity of the perivascular and peribronchial infiltration had decreased. The bronchial, bronchiolar, alveolar spaces and their epitherial cells had degenerated into necrosis by infiltration of mononuclear cells, which is characteristic of the destructive phase of rejection (Fig. 3).

Group 3 allograft administered with CyA showed no evidence of rejection (Fig. 4).

Flow cytometric analysis. Flow cytometric analysis of GIL and BALF specimens using lymphocytic markers revealed interesting differences among the three experimental groups.

The W3/25-positive cells in GIL, a helper T lymphocyte subpopulation, was significantly lower in Group 2 than in Groups 1 and 3 seven days after transplantation (Fig. 5a).

The OX8-positive cell proportion in GIL that is a suppressor and cytotoxic T-lymphocyte subpopulations, showed no statistically significant difference among the three groups on the 3rd day after transplantation, but it was significantly higher in Group 2 than in Groups 1 and 3 on the 5th and 7th days after transplantation (Fig. 5b).

The OX39-positive cell proportion in GIL, the interleukin-2 receptor of activated lymphocytes, showed no statistically significant difference among the three groups on the 3rd day after transplantation, but it was significantly greater in Group 2 than in Groups 1 and 3 on the 5th and 7th days after transplantation (Fig. 5c).

The W3/25-positive cell proportion in BALF showed no statistically significant difference among the three groups on the 3rd day after transplantation, but it was signifficantly lower in Group 2 than in Groups 1 and 3 on the 5th and 7th days after transplantation (Fig. 6a).

The OX8-possitive cell proportion in BALF showed no statistically difference among the three groups on the 3rd day after transplantation, but it was significantly greater in Group 2 than in Groups 1 and 3 on the 5th and 7th days after transplantation (Fig. 6b).

The OX39-positive cell proportion in BALF showed no statistically difference among the three groups on the

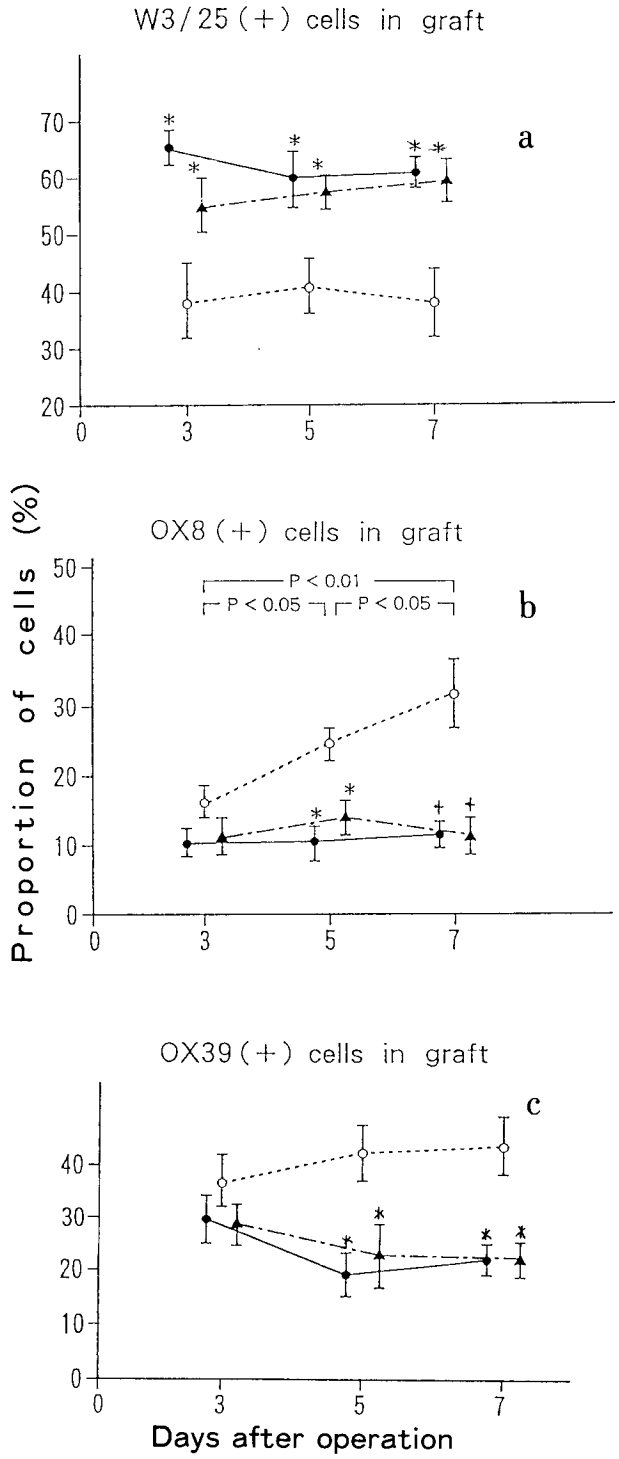

Fig. 5 Flow cytometric analysis of graft infiltrating lymphocyte (GIL) subsets. Values are mean ± SD. Group 1 (●——●) (n = 6); Group 2 (○----○) (n = 6) and Group 3 (▲--▲) (n = 6). *, P < 0.05 vs Group 2. +, P < 0.01 vs Group 2.

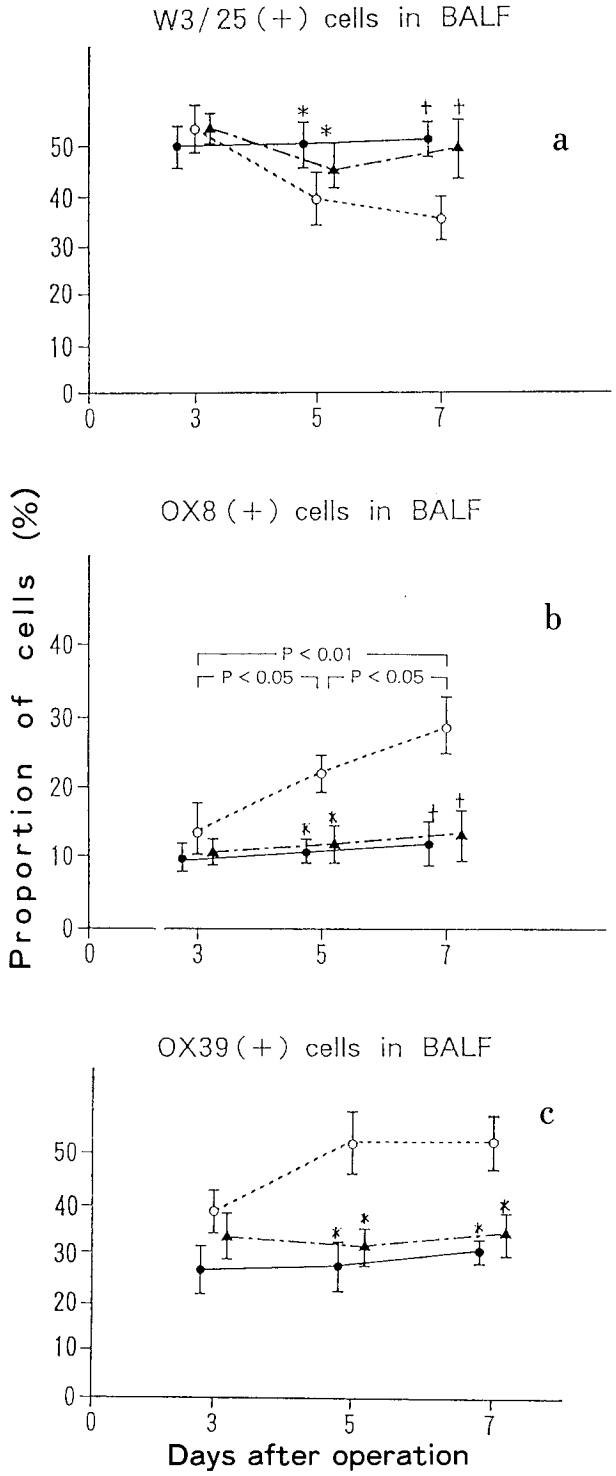

Fig. 6 Flow cytometric analysis of bronchoalveolar lavage fluid (BALF) lymphocyte subsets. Values are mean ± SD. Group 1 (●——●) (n = 6); Group 2 (○-----○) (n = 6) and Group 3 (▲-·-·▲) (n = 6). ∗, $p < 0.05$ vs Group 2. +, $p < 0.01$ vs Group 2.

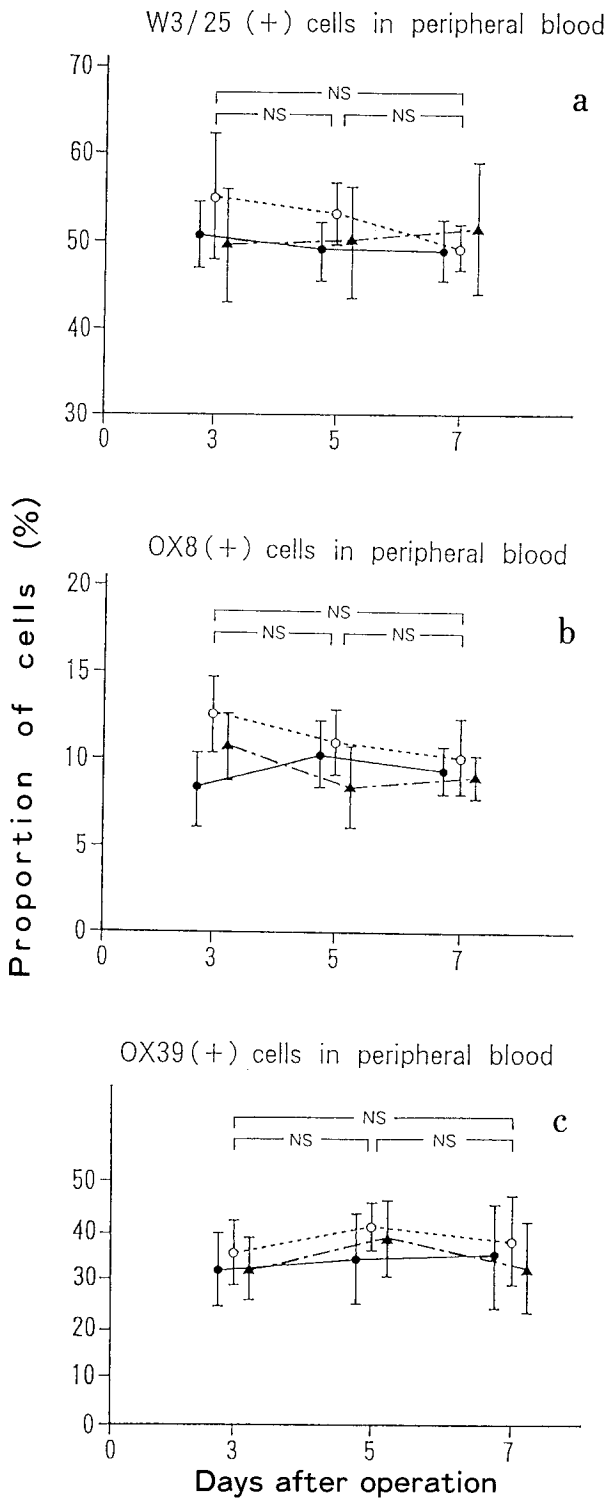

Fig. 7 Flow cytometric analysis of peripheral lymphocyte (PBL) subsets. Group 1 (●——●) (n = 6); Group 2 (○-----○) (n = 6) and Group 3 (▲-·-·▲) (n = 6).

3rd day after transplantation, but it was significantly greater in Group 2 than in Groups 1 and 3 on the 5th and 7th days after transplantation (Fig. 6c).

In the flow cytometric analysis of the peripheral blood lymphocytes, none of these markers was significantly different among the three groups during the observation period (Fig. 7).

Discussion

After the first successful human heart-lung transplantation was performed by Reitz *et al.* (14), lung transplantation has been accepted as a treatment option for end-stage lung disease (15–17). While advances in surgical technique (16, 18), lung preservation (19, 20), patient selection (21, 22), and immunosuppressive therapy have improved survival rates (23), it is also true that there remains many problems to be solved. Among these problems, early and accurate diagnosis of rejection is important for proper immunosuppression.

Acute rejection after lung transplantation is diagnosed at present by evaluation of clinical symptoms, such as fever and dyspnea, findings from chest roentgenograms, pulmonary function tests, bronchoalveolar lavage (BAL), and lung biopsy (24). However, there is no definite diagnostic procedure for detecting early acute rejection. The purpose of this study was to analyze T-cell surface markers with a variety of anti-rat monoclonal antibodies (MoAb) via flow cytometry and to evaluate whether such analysis is useful in the early diagnosis of acute rejection.

In this study, we observed that the proportion of OX8 positive cells (suppressor/cytotoxic T cells) increased in the graft and bronchoalveolar lavage fluid as rejection progressed. On the 5th postoperative day, when rejection peaked, suppressor/cytotoxic T cells were predominant among the T cells, and infiltrating cells had increased markedly, suggesting that suppressor/cytotoxic T cells were mobilized in the pulmonary alveoli, where target parenchymal cells are abundantly present.

Hancock *et al.* (25) studied the composition of infiltrating cells that occur at different levels of severity of acute rejection after kidney transplantation and reported that in mild rejection, T cell accounted for 32 % of the infiltrating cells and 90 % of the T cells represented OKT8-positive cytotoxic T cells. Macrophages composed 52 % of the infiltrating cells. In moderate rejection, T cells accounted for 42 % of the infiltrating cells and 67 % of the T cells represented OKT8-positive cytotoxic T cells. Macrophage composed 38 % of the infiltrating cells. In severe rejection, T cells accounted for 15 % of the infiltrating cells and 78 % of the T cells represented OKT8-positive cytotoxic T cells. Sixty and 22 % of the infiltrating cells were composed of macrophages and polymorphic cells, respectirely. Yamamoto *et al.* (26), who used immunostaining analysis of a lung allograft in rat models, reported that the proportion of OX8-positive cells rose and that of W3/25-positive cells declined at the 4th postoperative day. These results are consistent with those we obtained from flow cytometry.

In an attempt to determine the usefulness of BALF in the monitoring of rejection after lung transplantation in rats, Saito *et al.* (27) examined BALF lymphocytes. The ratio of CD4 (+) to CD8 (+) cells was found to decrease and the total number of lymphocytes in BALF was increased during the rejection period. In moderate rejection, CD4: CD8 ratio showed less than 1.0, and it decreased as the rejection progressed. Because the CD4: CD8 ratio is well known to be an imprecise measure of determining the cause of the rejection. In general, a decrease in the CD4: CD8 ratio associated with a rise in the absolute numbers of CD8 cells is highly suggestive of an acute rejection. The findings in this study suggest that the increasing OX8 positive lymphocytes may be a useful aid in the surveillance for rejection.

Lymphocytes activated through acute rejection express the receptors for transferrin and interleukin 2. In this study, we detected an increase in OX39-positive cells (IL-2R) in the graft and BALF. Thedrez *et al.* (28) used immunoscintigraphy to demonstrate that ^{131}I-labeled OX39 positive lymphocytes were trapped by the heart graft during acute rejection (29, 30).

In lung transplantation, more rapid changes occurred in the T cell subset than in heart and kidney transplantation. Bronchus-associated lymphoid tissue (BALT) is believed to play an important role in this change. The heart lacks local lymphoid tissue while the lung has BALT. We reason that the BALT of lung grafts influence the rejection process possibly as a stimulant that induces suppressor T cells. BALT lymphocytes have an essential role in the stimulation of the rejection response. Grafted lymphocytes disseminate into the recipient's lymphoid organs. Prop *et al.* (31) showed that pretreatment of lung donor rat with irradiation can prevent this accelerated rejection of the lung. This donor pretreatment with radiation results in diminution of the donor BALT.

In the lung graft, BALT is the initial site of infiltration by recipient lymphocytes, thereafter, BALT lymphocytes disseminate from the graft and induce a similar systemic response in the recipient's lymphoid tissue. Those rats were reported to have well tolerated and functioning grafts when they entered the graft-induced immunocompromised condition. Therefore, we believe that the lymphocytes found in the graft and BALF in our study were principally recipient cells, which were derived from BALT, as in the forefront of the rejection reaction.

In heart and lung transplantation, transbronchial biopsy (5, 32) and BALF (33, 34) have attracted attention as alternatives to endomyocardial biopsy in heart transplantation. Results of our study suggested that immunological monitoring of the lymphocytes obtained with these procedures is useful for diagnosing acute rejection. However, monitoring T cell subsets in infections, such as cytomegalovirus and bacterial pneumonia (35, 36), has not been fully studied and will require further research.

In conclusion, flow cytometric analysis of surface markers on the graft infiltration and BALF reflects the rejection process more accurately than the same analysis on peripheral blood lymphocytes. Our method of preparation of graft infiltrating lymphocytes is highly efficient and specific, thus the results were reproducible and excellent for immunologic analysis of the intragraft event. We believe our methods can be useful for the diagnosis of rejection in the clinical practice.

References

1. Toronto Lung Transplant Group: Unilateral lung transplantation for pulmonary fibrosis. N Engl J Med (1988) **314**, 1140-1145.
2. Patterson GA, Cooper JD, Goldman B, Weisel RD, Pearson FG, Wa-ters PF, Todd TR, Scully H, Goldberg M and Ginsberg RJ: Techniques of successful clinical double lung transplantation. Ann Thorac Surg (1988) **45**, 626-633.
3. Cooper JD: Lung transplantation. Ann Thorac Surg (1989) **47**, 28-44.
4. Koerner SK, Hangstrom JWC and Vieth FJ: Transbronchial biopsy for the diagnosis of lung transplant rejection. Am Rev Res Dis (1976) **114**, 575-579.
5. Higenbottam T, Stewart S, Penketh A and Wallwork J: Transbronchial lung biopsy for the diagnosis of rejection in heart-lung transplant patients. Transplantation (1988) **46**, 532-539.
6. Marck KW and Wildevuur CRH: Lung transplantation in the rat: I. Technique and survival. Ann Thorac Surg (1982) **34**, 74-80.
7. Mizuta T, Kawaguchi A, Nakahara K and Kawashima Y: Simplified rat lung transplantation using a cuff technique. J Thorac Cardiovasc Surg (1989) **97**, 578-581.
8. Prop J, Tazelaar HD and Billingham ME: Rejection of combined heart-lung transplants in rats: Function and pathology. Am J Pathol (1987) **127**, 97-105.
9. Tazelaar HD, Prop J, Nieuwenhuis P, Billingham ME and Wildevuur CRH: Airway pathology in the transplanted rat lung. Transplantation (1988) **45**, 864-869.
10. Totterman TH, Hanas E, Bergstrom R, Larsson E and Tufveson G: Immunologic diagnosis of kidney rejection using FACS analysis of graft infiltrating functional and activated T and NK cell subsets. Transplantation (1989) **47**, 817-823.
11. Arai S, Senoo Y and Teramoto S: The impact of FK506 on graft coronary disease of rat cardiac allograf: A comparison with cyclosporine A. J Heart Lung Transplant (1992) **11**, 757-762.
12. Okada M, Senoo Y and Teramoto S: Difference of rejection between heart and heart-lung transplantation in rats: Flowcytometric analysis of graft infiltrating lymphocyte subsets. Acta Med Okayama (1992) **46**, 37-44.
13. Sendecor GW and Cochran: Statistic Methods. Iowa State Univ Press, Iowa (1971).
14. Reitz BA, Wallwork JL, Hunt SA, Pennock JL, Billingham ME, Oyer PE, Stinson EB and Shumway NE: Heart-lung transplantation: Successful therapy for patients with pulmonary vascular disease. N Engl J Med (1982) **306**, 557-564.
15. Kriett JM and Kaye MP: The registry of the international society for heart transplantation: Seventh official report-1990. J Heart Transplant (1990) **9**, 323-330.
16. Griffith BP, Hardesty RL, Trento A, Paradis IL, Duquensnoy RJ, Zeevi A, Dauber JH, Dummer JS, Thompson ME, Gryzan S and Barhson HT: Heart-lung transplantation: Lessons learned and future hopes. Ann Thorac Surg (1987) **43**, 6-16.
17. Hutter JA, Despins P, Higenbottam T, Stewart S and Wallwork J: Heart-lung transplantation: Better use of resourses. Am J Med (1988) **85**, 4-11.
18. Novitzky D and Cooper DKC: The transplantation and replacement of thoracic organs; in The Present Status of Biological and Mechanical Replacement of the Heart and Lungs. Kluwer Academic Publishers, Dordrecht (1990) pp289-298.
19. Hakin M, Higenbottam T, Bethune D, Cory-Pearce R, English TAH, Kneeshaw J, Wells FC and Wallwork J: Selection and procurement of combined heart and lung grafts for transplantation. J Thorac Cardiovasc Surg (1988) **95**, 474-479.
20. Hardesty R and Griffith BP: Autoperfusion of the heart and lungs for preservation during distant procurement. J Thorac Cardiovasc Surg (1987) **93**, 11-18.
21. Hutter JA, Scott J, Wreighitt T, Higenbottam T and Wallwork J: The importance of cytomegalovirus in heart-lung transplant recipients. Chest (1989) **95**, 627-631.
22. Harjula A, Baldwin JC, Starnes VA, Stinson EB, Oyer PE, Jamieson SW and Shumway NE: Proper donor selection for heart-lung transplatation. J Thorac Cardiovasc Surg (1987) **94**, 874-880.
23. Heck CF, Shumway SJ and Kaye MP: The registry of the international society for hart transplantation: Six official report-1989. J Heart Transplant (1989) **8**, 271-276.
24. Hutter JA, Stewart S, Higenbottam T, Scott JP and Wallwork J: Histologic changes in heart-lung transplant recipients during rejection episodes and at routine biopsy. J Heart Transplant (1988) **7**, 440-444.
25. Hancock WW, Gee D, Moerloose PD, Rickles FR, Evan VA and Atkins RC: Immunohistological analysis of serial biopsies taken during human renal allograft rejection. Transplantation (1985) **39**, 430-438.
26. Yamamoto R, Kinoshita H, Kinoshita Y, Mizoguchi S, Inoue K and Kishi A: Immunohistochemical aspects of acute rejection of the allografted rat lung. Transplantation (1990) **49**, 631-632.

27. Saito A, Kondo T, Fujimura S, Handa M, Ichinose T, Shiraishi Y and Nakada T: Study of bronchoalveolar lavage fluid in rat lung graft for early diagnosis of rejection. Ishoku (1989) **24**, 262-269 (in Japanese).
28. Thedrez P, Paineau J, Jacques Y, Chatal JF, Pelegrin A, Bauchaud C and Soulillou JP: Biodistribution of an anti-interleukin 2 receptor monoclonal antibody in rat recipients of a heart allograft, and its use as a rejection marker in gamma scintigraphy. Transplantation (1989) **48**, 367-371.
29. Cooper DSK, Novisky D, Rose AG and Reichart BA: Acute pulmonary rejection precedes cardiac rejection following heart-lung transplantation in a primate model. J Heart Transplant (1986) **5**, 29-32.
30. Gregory TS, Kenneth RM, Robert EL and Sherry LW: Alternations in T lymphocyte subpopulations associated with renal allograft rejection. Transplantation (1984) **37**, 261-264.
31. Prop J, Nieuwenhuis P and Charles RHW: Lung allograft rejection in the rat: I. Accelerated rejection caused by graft lymphocytes. Transplantation (1985) **40**, 25-30.
32. Scott JP, Fradet G, Smyth RL, Mullins P, Pratt A, Clelland CA, Hingenbottam T and Wallwork J: Prospective study of transbronchial biopsies in the management of heart-lung and single lung transplant patients. J Heart Lung Transplant (1991) **10**, 626-637.
33. Achterrath U, Blumcke S, Koerner SK, Yipintsoi T, Siegelman SS, Chandler P, Hagstrom JWC, Torres M, Cobbah JE, Fujii P and Veith FJ: Alveolar lavage cytology in transplanted lungs: I. Staining methods and findings in dogs with autografts and allografts without immunosuppression. J Thorac Cardiovasc Surg (1975) **69**, 510-520.
34. Yagyu K, Steinhoff G, Schafers HJ, Dammenhayn L, Haverich A and Borst HG: Comparison of mononuclear cell subpopulations in bronchoalveolar lavage fluid in acute rejection after lung transplantation and mycoplasma infection in rats. J Heart Transplant (1990) **9**, 516-525.
35. Schooley RT, Hirsch MS, Colvin RB, Cosimi B, Tolkoff-Rubin NE, McCluskey RT, Burton RC, Russel PS, Herrin JT, Delmonico FL, Giorgi JV, Henle W and Rubin RH: Association of herpesvirus infections with T-lymphocyte-subset alterations, glomerulopathy, and opportunistic infections after renal transplantation. N Engl J Med (1983) **308**, 307-317.
36. Maher P, O'Toole CM, Wreghitt TG, Spiegelhalter DJ, English TAH: Cytomegarovirus infection in cardiac transplant recipients associated with chronic T cell subset ratio inversion with expansion of a Leu-7 Ts-c subset. Clin Exp Immunol (1985) **62**, 515-524.

Received May 14, 1993; accepted June 28, 1993.