Acta Medica Okayama

Volume 35, *Issue* 6 1981 *Article* 5

DECEMBER 1981

Hyperbilirubinemia and enhanced mitosis of hepatocytes in phalloidin-treated female rats.

Takahiro Obata[*] Akiharu Watanabe[†] Shosuku Hayashi[‡]

Nobuyuki Takei[**] Tatsuro Sakata[††] Tetsuya Shiota[‡‡]

Toshihiro Higashi[§] Tatsuya Itoshima[¶] Hideo Nagashima[‖]

[*]Okayama University,
[†]Okayama University,
[‡]Okayama University,
[**]Okayama University,
[††]Okayama University,
[‡‡]Okayama University,
[§]Okayama University,
[¶]Okayama University,
[‖]Okayama University,

Copyright ©1999 OKAYAMA UNIVERSITY MEDICAL SCHOOL. All rights reserved.

Hyperbilirubinemia and enhanced mitosis of hepatocytes in phalloidin-treated female rats.*

Takahiro Obata, Akiharu Watanabe, Shosuku Hayashi, Nobuyuki Takei, Tatsuro Sakata, Tetsuya Shiota, Toshihiro Higashi, Tatsuya Itoshima, and Hideo Nagashima

Abstract

Cholestasis with htperbilirubinemia was induced in female, but not male, Sprague-Dawley rats by daily treatment with phalloidin for 7 days. Increases in serum direct bilirubin level and alkaline phosphatase (Al-Pase) activity were observed concomitantpy with diminished bile flow and a decreased output of bile acid and cholesterol. Kidht microscope findings of the liver revealed proliferated bile ductules and enhanced mitosis of hepatocytes.

KEYWORDS: phalloidin, cholestasis, hyperbilirubinemia, mitosis, bile ductule.

---

*PMID: 6459712 [PubMed - indexed for MEDLINE]
Copyright (C) OKAYAMA UNIVERSITY MEDICAL SCHOOL

Acta Med. Okayama 35, (6), 411–415 (1981)

HYPERBILIRUBINEMIA AND ENHANCED MITOSIS OF HEPATOCYTES IN PHALLOIDIN-TREATED FEMALE RATS

Takahiro OBATA, Akiharu WATANABE, Shosaku HAYASHI, Nobuyuki TAKEI, Tatsuro SAKATA, Tetsuya SHIOTA, Toshihiro HIGASHI, Tatsuya ITOSHIMA and Hideo NAGASHIMA

First Department of Internal Medicine, Okayama University Medical School, Okayama 700, Japan
(Director : Prof. H. Nagashima)

Received July 13, 1981

Abstract. Cholestasis with hyperbilirubinemia was induced in female, but not male, Sprague-Dawley rats by daily treatment with phalloidin for 7 days. Increases in serum direct bilirubin level and alkaline phosphatase (Al-Pase) activity were observed concomitantly with diminished bile flow and a decreased output of bile acid and cholesterol. Light microscope findings of the liver revealed proliferated bile ductules and enhanced mitosis of hepatocytes.

Key words : phalloidin, cholestasis, hyperbilirubinemia, mitosis, bile ductule.

During studies on intrahepatic cholestasis in experimental animals, we found that daily administration of phalloidin for 7 days to female Sprague-Dawley rats resulted in marked elevation of serum bilirubin levels. Except for taurolithocholate(1,2), chemicals known to produce cholestasis could not induce hyperbilirubinemia without marked elevation of serum glutamic oxaloacetic transaminase (GOT) and glutamic pyruvic transaminase (GPT). In the present paper, an animal model of cholestasis with hyperbilirubinemia similar to patients with intrahepatic cholestasis is described in detail. The model uses phalloidin isolated from the poisonous green fungus Amanita phalloides.

MATERIALS AND METHODS

Female and male Sprague-Dawley rats with body weights between 170-200 g were used in this experiment. Phalloidin(Sigma Chemical Co., St. Louis)was administered intraperitoneally at a dose of 40 μg per 100 g of body weight. Control rats were given an identical volume of physiological saline. Animals were fed *ad libitum* on Laboratory Chaw MF during the experiment. Rats were weighed daily, and the following procedures were performed on the 8th day. A polyethylene tubing with an outer diameter of 0.9 mm was placed in the common bile duct under light ether anesthesia, and bile was collected serially for 6 h at intervals of 60 min. Animals were then sacrificed by a blow to the head, and blood was collected from the cervical vessels. Serum biochemical tests for liver function were determined according to a conventional method. Bile flow, bile acid and the cholesterol content of bile were also

Produced by The Berkeley Electronic Press, 1981

measured routinely. Liver specimens were stained with hematoxylin and eosin and observed by light microscopy. The results were expressed as mean ± standard error of the mean. The statistical significance was evaluated by the Student *t*-test.

RESULTS

The relative percentage of liver weight per body weight increased significantly in phalloidin-treated female rats (Table 1). By the 8th day, body weight had decreased by 3% in control rats, by 11% in phalloidin-treated female rats, and by 5% in male rats. The serum bilirubin concentration, mainly direct bilirubin level, and serum Al-Pase activity elevated significantly in treated female rats as compared to control rats. Serum GPT activity also increased to a small extent. In male rats treated with phalloidin, however, serum bilirubin level only elevated slightly as compared to treated female rats.

TABLE 1. LIVER WEIGHT AND BLOOD BIOCHEMISTRY IN PHALLOIDIN-TREATED RATS

Treatment	No. of rats	Liver weight / Body weight × 100 (%)	Bilirubin (mg/dl) Total	Bilirubin (mg/dl) Direct	Al-Pase (BLU)	GPT (IU)
Control						
Female	7	3.4± 0.3	0.34± 0.09	0.21± 0.05	3.60± 0.43	22± 8
Male	4	3.2± 0.5	0.32± 0.01	0.18± 0.04	3.53± 0.52	29± 8
Phalloidin						
Female	4	4.3± 0.2*	3.58± 0.94**	3.21± 0.94**	8.26± 3.46**	118± 26**
Male	4	3.8± 0.1	0.66± 0.05	0.41± 0.04	6.97± 0.58**	47± 12

* $P<0.05$ ** $P<0.01$

TABLE 2. BILE VOLUME AND BILE BIOCHEMISTRY IN PHALLOIDIN-TREATED FEMALE RATS

Treatment	No. of rats	Volume (μl/min/g liver)	Bilirubin Concentration (mg/dl)	Bilirubin Output (μg/min/g liver)	Bile acid Output (nM/min/g liver)	Cholesterol Output (μg/min/g liver)
Control	7	1.09± 0.09	9.2± 1.8	0.11± 0.02	14.3± 0.1	2.0± 0.2
Phalloidin	4	0.31± 0.10**	35.4± 3.7*	0.12± 0.05	9.0± 1.6*	0.4± 0.1**

* $P<0.05$ ** $P<0.01$

Bile volume diminished markedly, and the output of both bile acid and cholesterol into bile also decreased significantly in phalloidin-injected female rats (Table 2). However, bilirubin concentration increased in bile, although bilirubin output remained unchanged.

Bile volume vs serum bilirubin concentration and serum bilirubin concentration vs bile bilirubin output showed a negative correlation with the r of the correlation coefficients being 0.85 and 0.77, respectively. However, serum

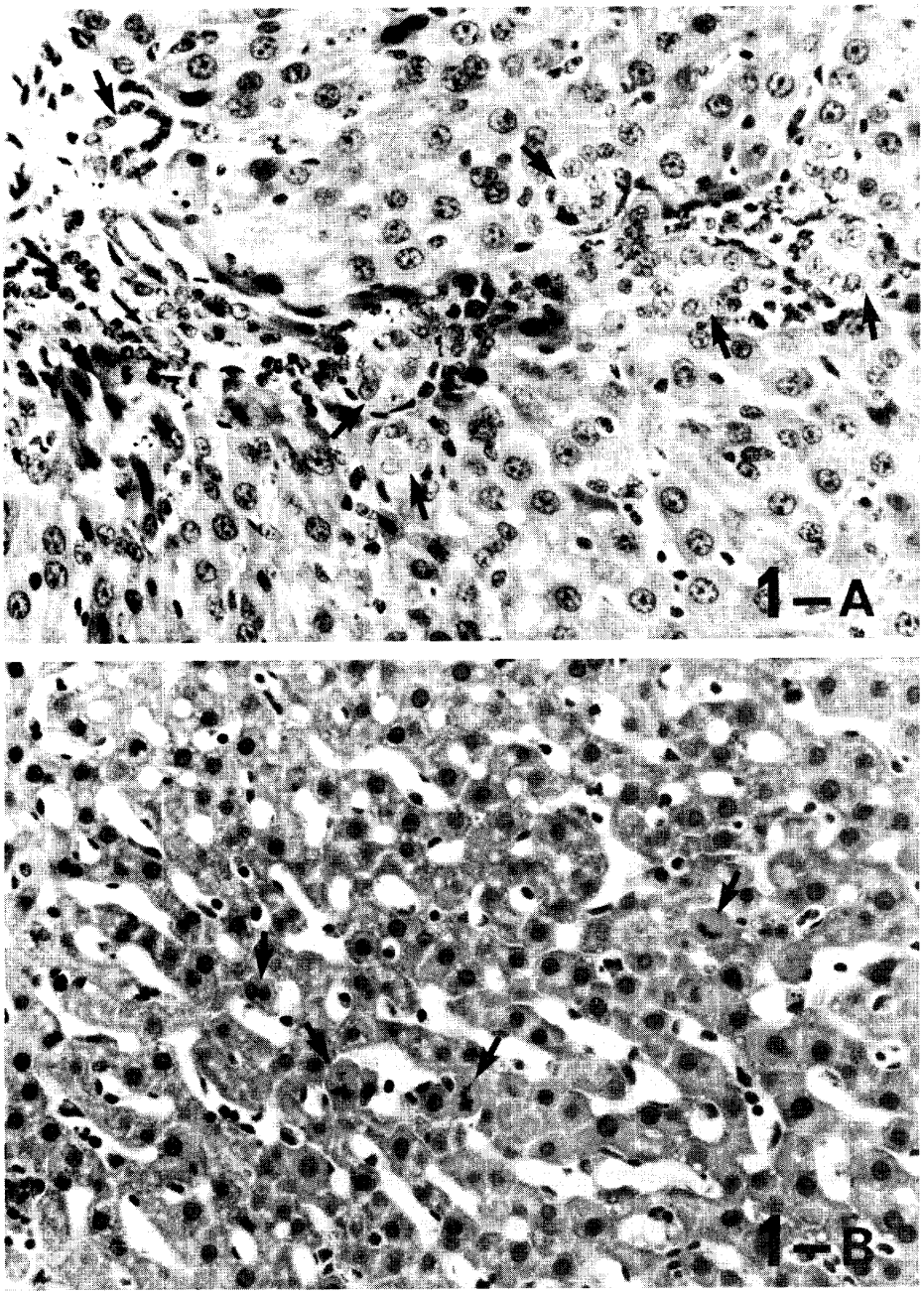

Fig. 1. Microscopic findings of the liver in phalloidin-treated female rats (× 250 H & E). Note: Proliferation of bile ductules (arrow heads) (Fig. 1-A) and mitosis of hepatocyte (arrow heads) (Fig. 1-B).

bilirubin concentration did not correlate with serum leucine aminopeptidase or Al-Pase activity. Bile volume correlated positively with bile bilirubin, cholesterol or bile acid output in phalloidin-treated female animals.

Microscopic observation of the liver revealed marked proliferation of bile ductules and enhanced mitosis of hepatocytes, but bile components were not detected in hepatocytes and bile canaliculi (Fig. 1).

DISCUSSION

An experimental model of cholestasis with hyperbilirubinemia, which resembles human intrahepatic cholestasis, was obtained by daily treatment of female Sprague-Dawley rats with phalloidin for 7 days. This treatment, however, did not induce hyperbilirubinemia in male rats. No animal model of intrahepatic cholestasis with jaundice has been presented without marked elevation of serum GPT activity except for taurolithocholate-induced cholestasis. α-Naphthylisothiocyanate is also known to be a substance which induces cholestasis with hyperbilirubinemia in rats, but it causes hepatic necrosis (elevation of serum GPT activity) and biliary tract damage (3, 4). Intrahepatic cholestasis without hyperbilirubinemia and liver cell necrosis has been developed by ethynyl estradiol (5) and cytochalasine B (6). However, models of intrahepatic cholestasis without hyperbilirubinemia as an essential feature of cholestasis are insufficient for studying human intrahepatic cholestasis.

Physiological and morphological studies on the effect of phalloidin administration to rats have already been reported (7, 8). However, there have been no reports of phalloidin-induced hyperbilirubinemia in rats. Phalloidin is known to accelerate polymerization of actin into microfilaments (8), increase microfilaments of hepatocytes and diminish bile flow in rats (7). Dubin *et al.* (7) reported that in phalloidin-treated male rats, bile flow and bile acid secretion into bile significantly decreased and bile acid-independent bile flow probably of canalicular origin also decreased. We are now further studying whether phalloidin-induced jaundice is dependent on the age or strain of rats. The detailed mechanism of hyperbilirubinemia in phalloidin-treated female rats is obscure at the present time.

Enhanced mitosis of hepatocytes by phalloidin has not been reported so far, and the mechanism also remained to be clarified.

REFERENCES

1. Javit, N.B. : Cholestasis in rats induced by taurolithocholate. *Nature* **210**, 1262-1263, 1966.
2. Tanigawa, K., Abe, H. and Maegawa, K. : Experimentally induced intrahepatic cholestasis. *The Saishin-Igaku* **10**, 1857-1862, 1977.
3. Goldfarb, S., Singer, E. and Popper, H. : Experimental cholangitis due to alpha-naphthylisothiocyanate (ANIT). *Am. J. Pathol.* **40**, 685-695, 1962.

4. Schaffner, F., Scharnbeck, H.H., Hutter ER, F., Denk, H., Greim, H.A. and Popper, H. : Mechanism of cholestasis Ⅶ. α-Naphthylisothiocyanate-induced jaundice. *Lab. Invest.* **28,** 321-331, 1973.
5. Kreek, M.J., Peterson, R.E., Sleisenger, M.H. and Jeffries, G.H. : Influence of ethynyl estradiol-induced cholestasis on bile flow and biliary excretion of estradiol and bromosulfophthalein by the rat. *J. Clin. Invest.* **46,** 1080, 1967.
6. Phillips, M.J., Oda, M., Mak, E., Fisher, M.M. and Jeejeebhoy, K.N. : Microfilament dysfunction as a possible cause of intrahepatic cholestasis. *Gastroenterology* **69,** 48-58, 1975.
7. Dubin, M., Maurice, M., Feldmann, G. and Erlinger, S. : Phalloidin-induced cholestasis in the rat : Relation to changes in microfilaments. *Gastroenterology* **75,** 450-455, 1978.
8. Agostini, B., Govindan, V.M., Hofmann, W. and Wieland, Th. : Phalloidin-induced proliferation of actin filaments within rat hepatocytes. *Z. Naturforsh* **30**c, 793-795, 1975.