

Acta Medica Okayama

Volume 48, Issue 1

1994

Article 3

FEBRUARY 1994

Clinicopathological Analysis of de Quervain's Disease

Yuhiko Takahashi*

Hiroyuki Hashizume†

Hajime Inoue‡

Takashi Ogura**

*Okayama University,

†Okayama University,

‡Okayama University,

**Okayama University,

Clinicopathological Analysis of de Quervain's Disease*

Yuhiko Takahashi, Hiroyuki Hashizume, Hajime Inoue, and Takashi Ogura

Abstract

Excised extensor retinacula of the first compartment and tenosynovium from 35 patients (6 men and 29 women) with de Quervain's disease were examined by light and electron microscopy to investigate the pathogenic mechanism. The patients, aged from 22-78 years, averaging 50 years, comprised the study group. Two hundred and thirty-two specimens from cadavers of 95 men and 75 women were macroscopically examined as the control. In the study group, the extensor retinaculum and tenosynovium were macroscopically thickened, and were histologically classified into 4 groups based on presence or absence of septum, and the location of retinacular thickening. Morphologically, the thickening of the tenosynovium and retinaculum was due to fibrosis in every layer, although fibroses were seen mainly in the middle layer. The ratios of proliferation of fibroblasts, myxoid changes and/or hyaline degeneration, and vascular proliferation were varied between layers. Minimal round cell infiltration was found in the retinaculum as well as in the tenosynovium. The results also indicate that the Iwahara-Nozue test can be used to accurately predict relatively greater thickening of the retinaculum on the extensor pollicis brevis side. Based on clinicopathological analyses, it appears that de Quervain's disease is induced not only by extrinsic factors such as superficial friction but also by intrinsic factors.

KEYWORDS: de Quervain's disease, stenosing tenosynovitis, ultrastructural study, histopathology

*PMID: 8191920 [PubMed - indexed for MEDLINE]

Copyright (C) OKAYAMA UNIVERSITY MEDICAL SCHOOL

Clinicopathological Analysis of de Quervain's Disease

YUHIKO TAKAHASHI*, HIROYUKI HASHIZUME, HAJIME INOUE AND TAKASHI OGURA

Department of Orthopaedic Surgery, Okayama University Medical School, Okayama 700, Japan

Excised extensor retinacula of the first compartment and tenosynovium from 35 patients (6 men and 29 women) with de Quervain's disease were examined by light and electron microscopy to investigate the pathogenic mechanism. The patients, aged from 22-78 years, averaging 50 years, comprised the study group. Two hundred and thirty-two specimens from cadavers of 95 men and 75 women were macroscopically examined as the control. In the study group, the extensor retinaculum and tenosynovium were macroscopically thickened, and were histologically classified into 4 groups based on presence or absence of septum, and the location of retinacular thickening. Morphologically, the thickening of the tenosynovium and retinaculum was due to fibrosis in every layer, although fibroses were seen mainly in the middle layer. The ratios of proliferation of fibroblasts, myxoid changes and/or hyaline degeneration, and vascular proliferation were varied between layers. Minimal round cell infiltration was found in the retinaculum as well as in the tenosynovium. The results also indicate that the Iwahara-Nozue test can be used to accurately predict relatively greater thickening of the retinaculum on the extensor pollicis brevis side. Based on clinicopathological analyses, it appears that de Quervain's disease is induced not only by extrinsic factors such as superficial friction but also by intrinsic factors.

Key words: de Quervain's disease, stenosing tenosynovitis, ultrastructural study, histopathology

In 1895, de Quervain described a previously unrecognized condition affecting the tendon sheath and tendons of the extensor pollicis brevis (EPB), and abduc-

tor pollicis longus (APL) that occupy the first compartment on the dorsal surface of the radius near the styloid process (1). The condition became known as de Quervain's disease, or stenosing tendovaginitis at the first compartment of the extensor retinaculum. Although the disorder is relatively common, there are few histopathological studies in the literature (2, 3). The early reports focused on inflammation and identified three etiologic factors: repetitive movement, and anatomical and hormonal factors. Repetitive movement was considered to be an extrinsic factor, and anatomical and hormonal factors were intrinsic. The presence or absence of a septum and number of tendons have been discussed in relation to the onset mechanism of de Quervain's disease (4, 5). To better understand the onset mechanism, we examined tissue structures of the first compartment of the extensor retinaculum of patients diagnosed as having de Quervain's disease, and compared the results with a cadaveric control group. In the early reports, chronic inflammation has been cited as the main cause of this disorder. However, Ippolito et al. (6) observed degenerative changes in collagen fibers by electron microscopy. De Quervain declared that the synovial surface was uninvolved, and the adjacent tissue was thickened but not due to inflammatory reactions or round cell infiltration. He never found any gross pathological changes in the tendons (1).

In this study, surgical specimens from the patients with de Quervain's disease were examined by light and electron microscopy, and the correlation between the morphology and functional disturbances in clinical presentation are discussed.

Materials and Methods

Thirty-five patients diagnosed as having de Quervain's disease who were treated in our department from 1985 to 1992 comprise the study group. Our diagnostic criteria of de Quervain's disease were: a) pain on the radial side of

* To whom correspondence should addressed.

Table 1 Age and sex distribution of patients and cadavers examined

Gender	Number of patients and cadavers classified by age (year)							
	0~19	20~29	30~39	40~49	50~59	60~69	70~79	80~
Patients with de Quervain's disease								
Men	0	2	0	0	1	2	1	0
Women	0	4	3	7	9	4	2	0
Cadaveric controls								
Men	0	1	1	2	7	11	33	40
Women	0	0	0	0	4	4	21	42

the wrist, b) tenderness or swelling on the radial styloid, and c) a positive Finkelstein's test (2). Extensor retinacula and synovial tendon sheaths were excised from 35 wrists of 35 patients during surgical treatment. In the study group, there were 6 men and 29 women, ranged in age from 22 to 78 years, averaging 50 years (Table 1). The occupation of the patients were homemaker (n = 20), office worker (n = 6), laborer (n = 5), and no reported occupation (n = 4). All patients who underwent surgery had voluntarily limited their activities due to pain for over 6 weeks.

Cadaveric specimens were used as controls because they were the best available anatomical specimens (7). The anatomical control group was not and could not be a truly representative sample of a normal population. The extensor retinacula of 232 wrists were obtained from 170 cadavers (Table 1). None of them had a past history of functional disorders of the wrists. All were Japanese and had been preserved for less than 5 years.

The Iwahara-Nozue test (8) which can only be used with conscious patients was defined as positive if the patients felt pain with passive flexion of the wrist and active extension of the thumb. The EPB and APL, presence or absence of a septum, and thickening of the retinaculum and tenosynovium of the wrists were compared with the anatomical controls before sectioning.

Each retinaculum was cut perpendicular to the long axis of the tendon, and the thickest or distal part was examined. The specimens from the patients were fixed with 10% neutral buffered formalin and stained with hematoxylin and eosin (HE), Mallory-Azan, Masson-trichrom, and Toluidine blue. They were also examined by light microscopy and polarized light microscopy (PLM).

The specimens from the study group for examination by scanning electron microscopy (SEM) were fixed with 2.5% glutaraldehyde (buffered to pH 7.4 with 0.1M PBS), frozen and cracked in liquid nitrogen after washing in 0.2M cold cacodylic acid buffer. Some were frozen and cracked to examine the central portion. Each sample was dried, evaporated and examined by SEM (JSM-T20 type, JEOL Ltd.). The specimens for examination by transmission electron microscopy (TEM) were fixed after washing by the same method as SEM, and post-fixed with 1% osmium tetroxide. Double staining was done with uranyl acetate and ruthenium red. They were then examined by TEM (JEM-100S type, JEOL Ltd.).

The specimens were classified into four groups based on anatomical criteria. The results of statistical analyses were subjected to chi-square test (with Yates' correction in the case of degree of freedom). A *p* value of <0.05 was considered significant for all tests.

Results

Anatomical and histopathological variations in the first compartment of extensor retinaculum are summarized in Table 2. A septum was observed more frequently in the study group than in controls. EPB and APL were also more numerous in patients with de Quervain patients. The percentage of specimens containing septa was 74% in the study group and 49% in the control group, and the difference was statistically significant (*p* < 0.01). The numbers of EPB and APL tendons in the de Quervain's disease were also higher than the cadavers, and this difference was also statistically significant (*p* < 0.001) (Tables 1, 2). In the control group, there was no significant difference by gender in the proportion of septa found

Table 2 Variations in the first compartment of extensor retinaculum

	Gender	Group				Number of EPB			Number of APL				
						0	1	2	1	2	3	4	
Patients ^a		I	II	III	IV								
	Men	2	0	1	3	0	6	0	0	1	4	1	
	Women	10	9	4	6	0	25	4	10	9	6	4	
	Total	12	9	5	9	0	31	4	10	10	10	5	
Cadaveric controls ^b		(+) ^c		(-) ^d									
	Men	61		60		7	114	0	47	60	17	3	
	Women	53		58		2	108	1	43	51	9	2	
	Total	114		118		9	222	1	90	111	26	5	

a: 35 samples from 35 patients

EPB: extensor pollicis brevis

b: 232 samples from 170 cadavers

APL: abductor pollicis longus

c: presence of septum

d: absence of septum

or in the number of EPB and APL tendons. In the study group, both the retinaculum and tenosynovium were thickened in 30 patients, and only the retinaculum was thickened in 5 patients (Fig. 1). The diameters of retinacula for both groups are illustrating in Fig. 2. The number of women was higher than men with de Quervain's disease.

The tenosynovium and retinaculum consisted of the synovial, inner, intermediate, and the outer layers of the retinaculum (Fig. 3). The histological findings in the study group were classified into 4 groups according to the presence or absence of septum and the retinaculum diameter (Fig. 3): Group I, a septum was present and the retinaculum of both EPB and APL sides were equally thickened ($n = 12$); Group II, a septum was present and the retinaculum was thickened on both sides, although the EPB side was thicker ($n = 9$); Group III, a septum was present and retinaculum was thickened on both sides, and the APL side was thicker ($n = 5$); Group IV, the retinaculum was thickened and the septum was absent ($n = 9$). EPB and APL tendons were not enlarged in any of these groups.

All of the patients with de Quervain's disease were diagnosed according to their Finkelstein test score. Twenty-six patients also tested positive in the Iwahara-Nozue test before surgery. This test was positive in 3 out of the 4 groups; 12 out of 12 patients in Group I, 9 out of 9 patients in Group II and 5 out of 9 patients in Group IV. The 5 patients in Group IV had greater thickening on the EPB side. Iwahara-Nozue test results were negative in all 5 patients in Group III. Retinaculum was thickened

in all 4 groups. Although the Iwahara-Nozue test originally was not designed to indicate EPB thickening, our

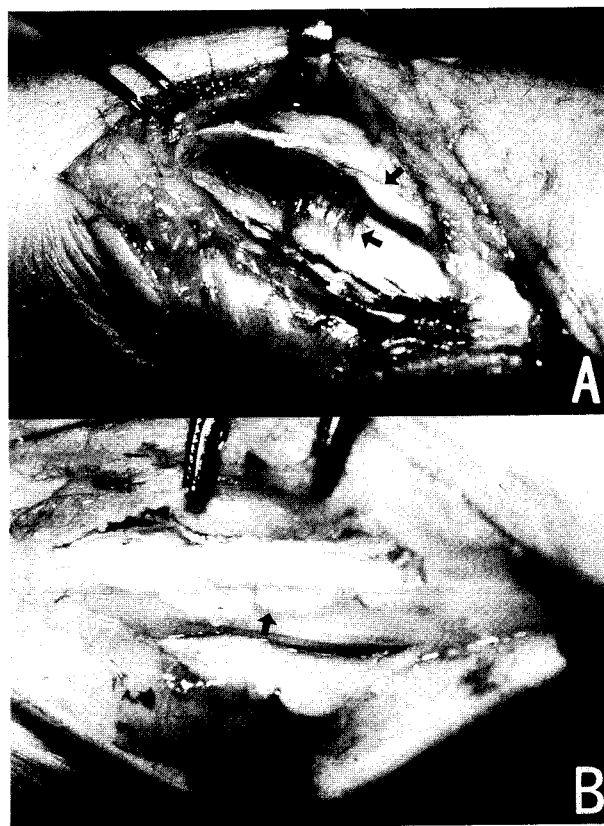


Fig. 1 Operative findings of de Quervain's disease. A: Both retinaculum and tenosynovium thickened. B: Only retinaculum thickened.

results showed a statistically significant correlation between positive test results and EPB thickening. The

test results for Groups I and IV indicated that there was some difference other than the presence or absence of the

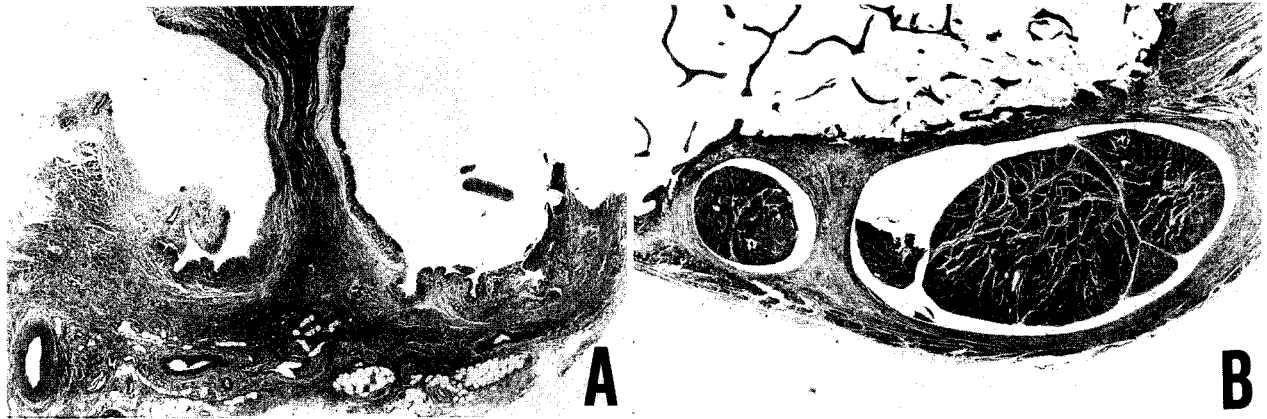


Fig. 2 De Quervain's disease and normal control. A: de Quervain's disease. B: normal control.

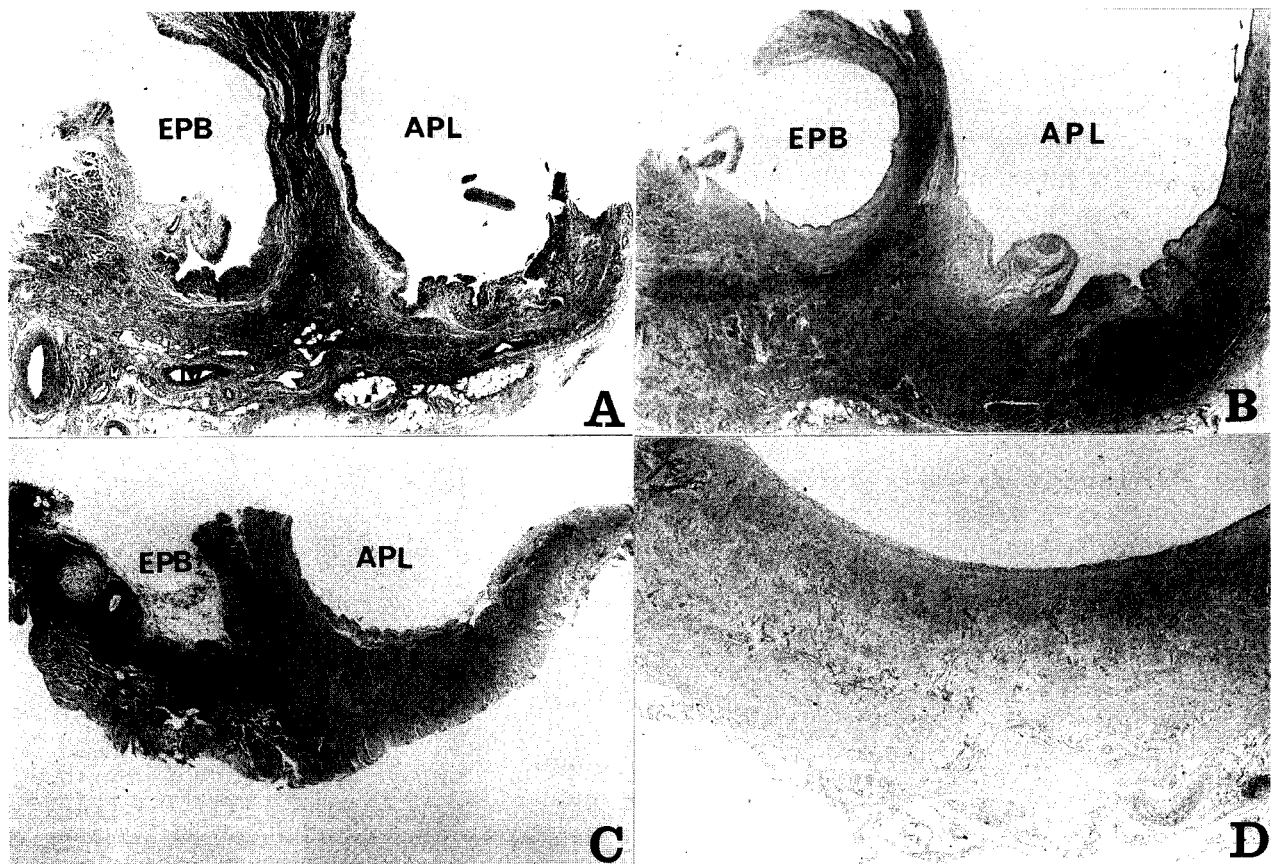


Fig. 3 Histology of classified types. A: Group I (I: superficial synovial layer, II: inner layer of the retinaculum, III: intermediate layer, IV: outer layer) (HE, X17); B: Group II (HE, X17); C: Group III (HE, X17); D: Group IV (HE, X17).

septum.

The total percentages of histological findings in the retinacula of all 4 groups are shown in Table 3. Histologically, the thickening of the tenosynovium and

retinaculum was caused by fibrosis in every layer (Fig. 4 A-D). There were also chronic inflammatory changes in all layers. In the superficial tenosynovium, the number of layers of synovial cells and capillaries increased (Fig. 4A).

Table 3 Histological findings in 35 patients

Grade	Histological findings (%)					
	Capillary proliferation	Round cell infiltration	Fibroblast proliferation	Fibrosis	Hyaline degeneration	Myxoid degeneration
Severe	11	0	20	34	0	26
Moderate	31	12	46	29	14	34
Minimal	26	17	20	20	9	11
Absent	26	71	14	17	77	29
Total	100	100	100	100	100	100

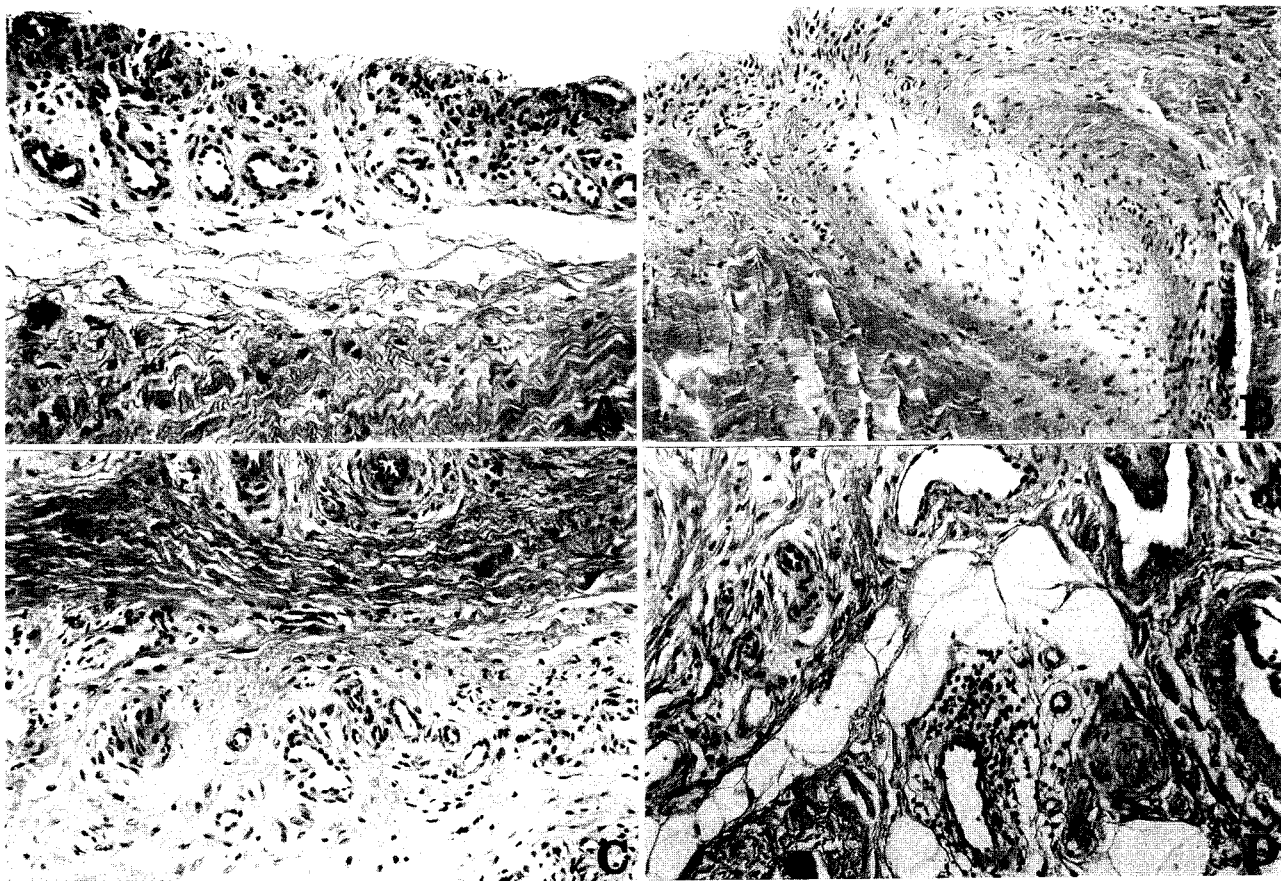


Fig. 4 Light microscopic findings of the retinaculum. **A:** Vascular proliferation in the first layer (HE, X 120); **B:** Myxoid lesion in the second layer (HE, X 120); **C:** Regularly arranged collagen fibrils and irregular fibrils around small vessels in the third layer (HE, X 120); **D:** Round cell infiltration around the small vessels and edema in the fourth layer (HE, X 120).

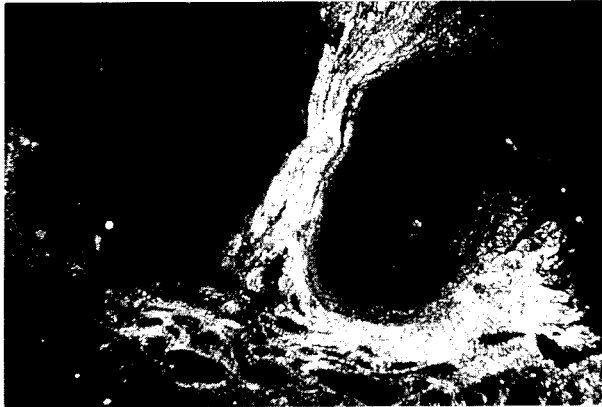


Fig. 5 Fibrillar structure of the 4 layers under polarized light microscope in Group I (HE, X17).

Round-cells had minimally infiltrated the edematous stroma (Fig. 4C). Fibroblast proliferation and an increase of collagen fibrils were observed in the inner and outermost layers (Fig. 4B, C). Capillary proliferation with stromal myxoid and/or hyaline degeneration was found in the intermediate layer (Fig. 4C). An increase of the dense fibrous connective tissue, containing numerous capillaries, and lymphocytic infiltration was also found in this layer (Fig. 4D). The fibril network of these layers was easily identified under the polarized light microscope (Fig. 5). The tendons *in situ* appeared to be normal in these patients.

Under SEM, the cracked surface disclosed the proliferation of synovial cells. Columnar cells just beneath the synovial cells were arranged in regular parallel rows (Fig.

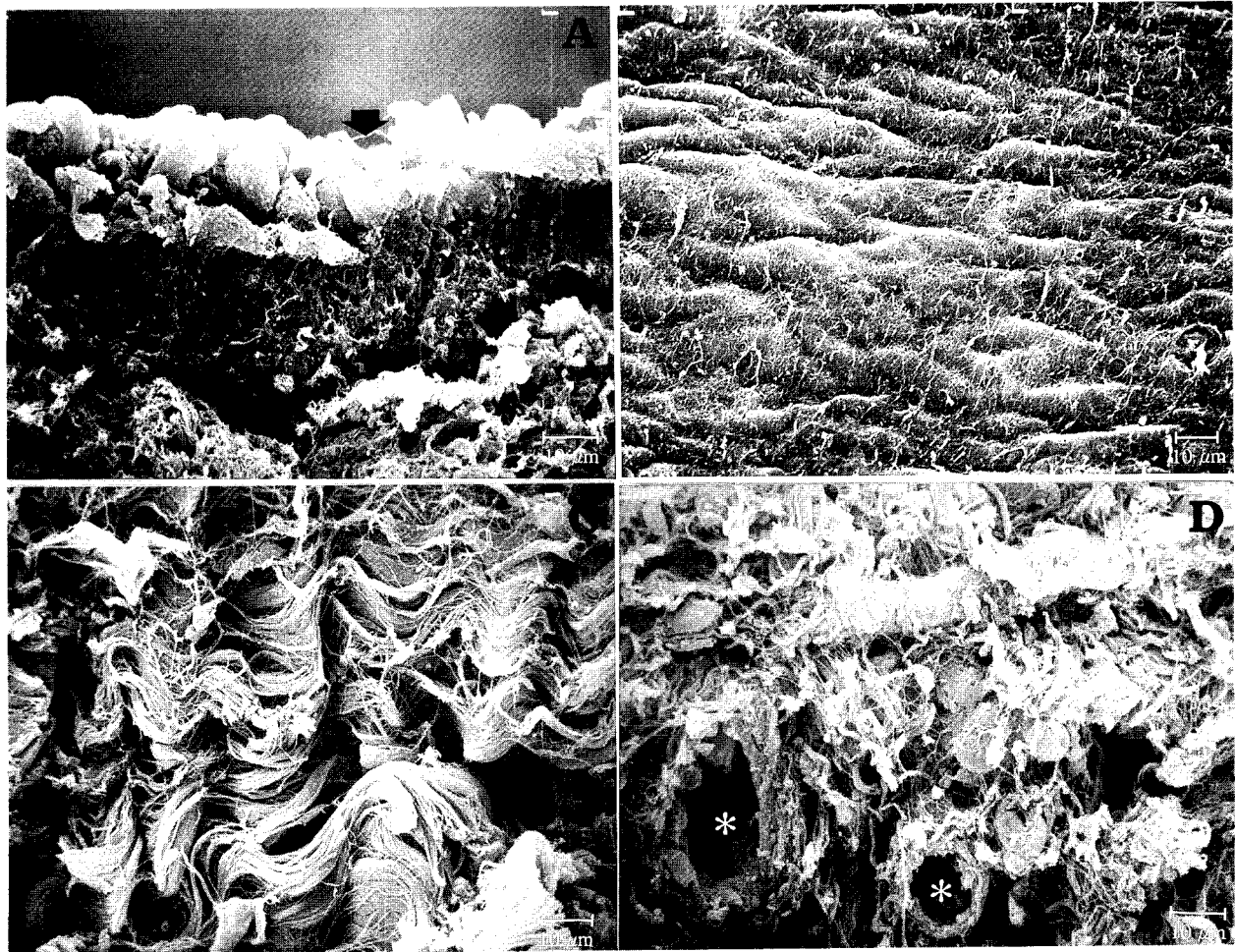


Fig. 6 Scanning electron micrographs of the retinaculum in de Quervain's disease. A: Proliferation of superficial cells; B: The surface of the first layer; C: Dense collagen bundles in the fourth layer; D: Irregular collagen fibrils around capillaries (*) in the third layer.

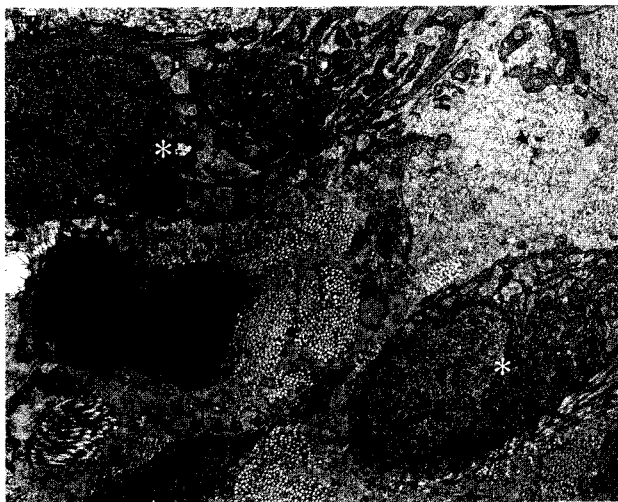


Fig. 7 Collagen fibrils around fibroblasts (*) in the fourth layer.

6A). The surface of the synovial layer was elevated by 15 μm showing an almost normal appearance (Fig. 6B). Dense collagen bundles of 15 μm wide were found in the outer layer of the retinaculum (Fig. 6C). Scattered and irregularly shrunken collagen fibrils, suggesting newly formed collagen fibrils, were mainly observed around the capillaries in the intermediate layer of the retinaculum (Fig. 6D). Under TEM, the bundles of collagen fibrils in the synovial layer were found around the fibroblasts containing rough endoplasmic reticula in their cytoplasm (Fig. 7). In the intermediate layer, histiocytes with many electron-dense particles in the extracellular space were observed.

Discussion

According to Muckart (9), the first reference on stenosing tendovaginitis of EPB and APL at the radial styloid was found in the 13th edition of Gray's Anatomy (1893) under the title "Washer-Woman Sprain". De Quervain published his original paper that described the disorder in 1895 (1). Stenosing tenosynovitis was defined as the disturbance of tendon movement due to chronic inflammation resulting in pain on the radial side of the wrist. However, there have been a few reports of histopathology or etiology (2, 9).

Finkelstein claimed that, in mild cases, the synovial membrane was thickened, and that the loose connective-tissue layer was considerably thickened and vascularized.

In severe cases, the synovial layer was completely destroyed and was totally replaced by hyalinized collagenous tissues, and the loose connective-tissue layer was compressed and thinned by the thickened hyalinized tissue. The ligamentous layer was markedly thickened and undergoes hyaline degeneration and or cartilaginous transformation. Finkelstein concluded that stenosing tendovaginitis could be produced by thermal, chemical and mechanical stimulation, and proposed that an inflammation was caused by friction between tendon and tenosynovium (2). Repetitive superficial friction produced inflammatory reactions of round cell infiltration and edema in the synovial layer. Our findings suggest that inflammation was not induced by superficial friction, because additional minimal-to-severe inflammatory changes were found in all four layers (Fig. 4). We also noted a high incidence of capillary and round cell proliferation in cases that ranged from minimal to severe, which indicated a chronic inflammatory condition. In the future, we will clarify the inflammatory reaction by the analyses of fibrosis and type of collagen produced in each layer.

According to Muckart (9), the chronic inflammatory reaction found in both fibrous retinaculum and synovium and the presence of hemosiderin in the synovium supported the contention that de Quervain's disease was an acute episode superimposed on a chronic condition. Previous histologic examination of de Quervain's disease (2, 3, 9-12) showed an inflammatory reaction in the constricted fibrous sheath. Ippolito *et al.* (6) observed an increased amount of collagen but no round cells in the thickened sheath in their ultrastructural study. In our study, the patient's specimens clearly showed round cell infiltration (12%) and fibrosis (63%) (Table 3).

Although there was a clear relationship between the histological changes and the degree of disturbance of movement, it seemed that the inflammatory reaction reflected either different stages of the disease or different parts of the involved retinaculum and tenosynovium. This may reflect a selective grouping by the health care industry of patients that require different kinds of treatment. Each researcher may be investigating different cases that represent different stages and involve the different layers of the retinaculum. This could explain some of the apparent contradictions in the reports that we have cited.

The Iwahara-Nozue test helps to identify the cases where the focus of pain is on the EPB rather than on the APL side. This test also informs the surgeon about the probability of the presence of a septum and the need to

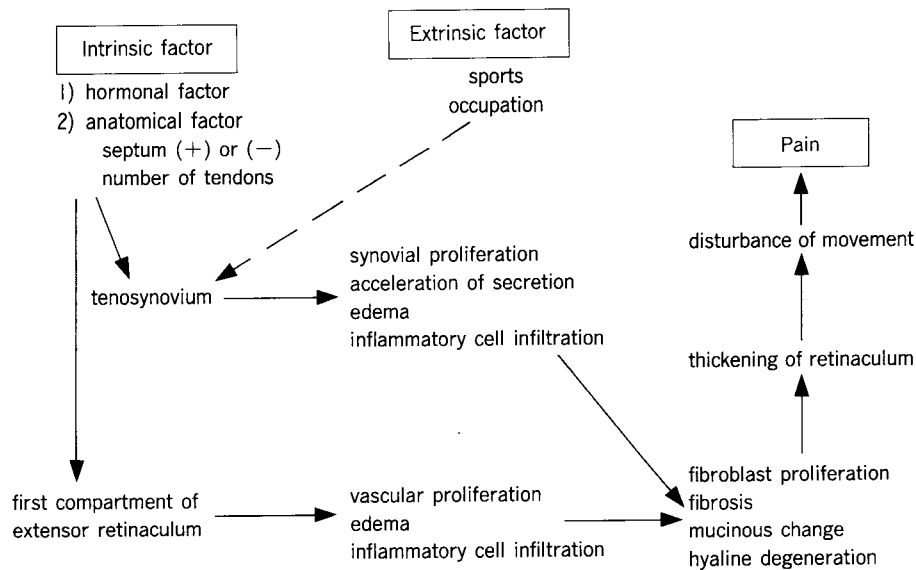


Fig. 8 Causative factors and onset mechanisms of de Quervain's disease.

look carefully for supernumerary tendons behind the septum. The persistence of pain after surgery may indicate that supernumerary tendons had been overlooked because they were obscured by the septum. Hopefully, in the future, precise identification of a focus of pain in the EPB side may allow preservation of the APL in patients who respond to anti-inflammatory agents. Because corticosteroids inhibit the inflammatory reaction and the increased synthesis of collagen, or other extracellular matrix (6), these hormones may be the treatment of first choice for de Quervain's disease. Orthopaedic surgeons must consider the high probability of thickening of the retinaculum in this disease when they make precise diagnoses and recommending treatment.

Occupational activities have been frequently cited in discussion of etiology (2, 9-11, 13, 14). Finkelstein (2) stated that cumulative trauma was the most common cause. There were many case reports where the causes were playing the piano, using a typewriter, handwriting, washing, wringing clothes, chopping wood, carrying heavy objects, farm labor, cutting cloth with heavy scissors, etc. However, Thompson *et al.* (15) reviewed 419 cases of peritendinitis crepitans occurring in factory workers after a period of intense effort where only two patients developed de Quervain's disease. These results suggest that friction does not play an important role in the development of stenosing tendovaginitis.

De Quervain's disease was, in the past, thought to consist of anatomic variations of the retinacula and tendons (4, 5, 9, 13, 14, 16). In our study, the incidence of the presence of a septum was also higher in patients with de Quervain's disease than in normal individuals (Table 2). However, there was no gender difference in the occurrence of a septum and the number of EPB and APL tendons in the cadavers (7). We agree with the anatomic factor explanation that the existence of a septum may be a predisposing etiologic factor in complaints of limitation of movement (Fig. 8). However, the high incidence in both groups of women and the differential distribution by gender and age group (Table 1) indicate that some hormonal factors may be associated.

We, therefore, conclude that the onset mechanism of de Quervain's disease includes intrinsic factors such as hormonal and anatomical variation (Table 1, 2), and extrinsic factors such as sports and occupational activities (Fig. 8). The high incidence of this disorder in women aged 40-60 years, may be mainly due to intrinsic factors, especially hormonal. The target organs seemed to be both the tenosynovium and the extensor retinaculum where thickening results in the disturbance of tendon gliding. Iwahara-Nozue test results indicated that impairment is directly related to the degree of thickening of the retinaculum in the EPB side. Complaints of limited movement with pain associated with extrinsic factors such

as sports and occupational activities are relatively acute and transient. Therefore, the extrinsic factors are probably not a primary cause in the chronic cases of this disease.

Acknowledgement. The authors wish to thank Mr. S. Watanabe, Okayama Saiseikai General Hospital, for his work on the electron microscopic specimens. The authors' grateful acknowledgement is also made to Drs. K. Hamaya and S. Nose for their advice on the electron microscopic studies.

References

1. De Quervain F: Über eine Form von chronischer Tendovaginitis. *Cor-BI f Schweiz Aerzte* (1895) **25**, 389-394.
2. Finkelstein H: Stenosing tendovaginitis at the radial styloid process. *J Bone Joint Surg* (1930) **12**, 509-540.
3. Meachim G and Roberts C: The histopathology of stenosing tendovaginitis. *J Pathol* (1969) **98**, 187-192.
4. Giles K W: Anatomical variations affecting the surgery of de Quervain's disease. *J Bone Joint Surg* (1960) **42-B**, 325-355.
5. Horiuchi Y: Analysis of operative findings of de Quervain's disease within last five years. *Seikeigeka* (1989) **40**, 199-203 (in Japanese).
6. Ippolito E, Postacchini F, Scola E, Bellocchi M and De Martino C: De Quervain's disease. *Intern Orthop (Soc Int Cong Orthop Traumotol)* (1985) **9**, 41-47.
7. Ogura T and Akahori O: An anatomical study of the first extensor compartment of the wrist. *J Jpn Soc Surg Hand* (1989) **6**, 473-476 (in Japanese).
8. Nozue Y: Conservative treatment of stenosing tenosynovitis (de Quervain's disease). *Seikeigeka* (1962) **13**, 212-216 (in Japanese).
9. Muckart RD: Stenosing tendovaginitis of abductor pollicis longus and extensor pollicis brevis at the radial styloid (de Quervain's disease). *Clin Orthop* (1964) **33**, 201-208.
10. Lipscomb PR: Stenosing tenosynovitis at the radial styloid process (de Quervain's disease). *Ann Surg* (1951) **134**, 110-115.
11. Leao L: De Quervain's disease. *J Bone Joint Surg* (1958) **40-A**, 1063-1070.
12. Keon-Cohen B: De Quervain's disease. *J Bone Joint Surg* (1951) **33-B**, 96-99.
13. Horiuchi Y, Nemoto T, Urabe T, Tasaki K, Matsumoto N, Togawa K, Uchinishi K, Takahashi M and Mochida S: De Quervain's disease. *Orthop Surg Traumatol* (1987) **30**, 1051-1056 (in Japanese).
14. Thomas L, Louis AG and Charles ET: Anatomical and clinical study of the variations in the insertions of the abductor pollicis longus tendon, associated with stenosing tendovaginitis. *J Bone Joint Surg* (1951) **33-A**, 347-350.
15. Thompson AR, Plewes LW and Shaw EG: Peritendinitis crepitans and simple tenosynovitis; A clinical study of 544 in industry. *Br J Ind Med* (1951) **8**, 150-160.
16. Strandell G: Variations of the anatomy in stenosing tenosynovitis at the radial styloid process. *Acta Chir Scand* (1957) **113**, 234-240.

Received February 5, 1993; accepted September 3, 1993.