

Acta Medica Okayama

Volume 48, Issue 3

1994

Article 8

JUNE 1994

Assessment of Myocardial Function During Mechanical Left Ventricular Support Using Serial Echocardiography: A Case Report

Kozo ishino*

Taiji Murakami†

Koji Takata‡

Koichi Kino**

Yoshimasa Senoo††

Shigeru Teramoto‡‡

*Okayama University,

†Okayama University,

‡Okayama University,

**Okayama University,

††Okayama University,

‡‡Okayama University,

Assessment of Myocardial Function During Mechanical Left Ventricular Support Using Serial Echocardiography: A Case Report*

Kozo ishino, Taiji Murakami, Koji Takata, Koichi Kino, Yoshimasa Senoo, and Shigeru Teramoto

Abstract

A 40-year-old man with valvular heart disease was successfully treated using a left ventricular assist device (LVAD) after open heart surgery. Echocardiography revealed left ventricular ejection fraction (LV-EF) at LVAD on/off: 23.4%/14.6% on the 4th, 23.8%/23.8% on the 5th, and 23.8%/26.8% on the 6th postoperative day (POD), respectively. The patient was weaned from LVAD on the 8th POD and discharged from the hospital on the 58th POD. The LV-EF improved to 54% 6 months after surgery and increased from 57% to 64% in response to exercise stress testing 1 year after surgery.

KEYWORDS: ventricular assist device, echocardiography

*PMID: 7942074 [PubMed - indexed for MEDLINE]

— Brief Note —

Assessment of Myocardial Function During Mechanical Left Ventricular Support Using Serial Echocardiography: A Case Report

KOZO ISHINO*, TAIJI MURAKAMI, KOJI TAKATA, KOICHI KINO, YOSHIMASA SENOO AND SHIGERU TERAMOTO

Second Department of Surgery, Okayama University Medical School, Okayama 700, Japan.

A 40-year-old man with valvular heart disease was successfully treated using a left ventricular assist device (LVAD) after open heart surgery. Echocardiography revealed left ventricular ejection fraction (LV-EF) at LVAD on/off: 23.4 % / 14.6 % on the 4th, 23.8 % / 23.8 % on the 5th, and 23.8 % / 26.8 % on the 6th postoperative day (POD), respectively. The patient was weaned from LVAD on the 8th POD and discharged from the hospital on the 58th POD. The LV-EF improved to 54 % 6 months after surgery and increased from 57 % to 64 % in response to exercise stress testing 1 year after surgery.

Key words: ventricular assist device, echocardiography

Despite an increase in the use of ventricular assist devices (VADs) after open heart surgery, the results recently reported are less encouraging. As of 1990, 965 patients were supported by VADs world-wide; of these, 45 % were weaned and 25 % survived (1). Although the VAD weaning criteria based on hemodynamic data established by Pierce *et al.* (2) are generally followed, the analysis of Termuhlen *et al.* indicated that more accurate assessment of ventricular function during VAD support is necessary to increase the salvage rate of critically ill patients (3).

We present our experience with a VAD in a patient in whom echocardiography was the only reliable method to evaluate the recovery of the failing heart.

Case Presentation

A 40-year-old man who received two mitral valve replacements at 25 and 33 years of age, was admitted to

Okayama University Hospital for further surgery. On admission, the echocardiogram demonstrated severe aortic regurgitation (Grade 3/4), perivalvular mitral regurgitation (3/4), and tricuspid regurgitation (4/4) with a left ventricular ejection fraction (LV-EF) of 42 %. The patient required mechanical ventilation for 7 days prior to operation. He also had liver dysfunction secondary to congestive heart failure with a total bilirubin level of 2.7 mg/dl, glutamic oxaloacetic transaminase of 77 IU/l and gamma glutamyl transpeptidase of 100 IU/l. A preoperative chest roentgenogram showed cardiomegaly with a cardiothoracic ratio of 0.92 and severe pulmonary venous congestion (Fig. 1).

Aortic and mitral valve replacement using St. Jude Medical valves and tricuspid annuloplasty were performed under standard cardiopulmonary bypass (CPB) technique and moderate hypothermia (28°C). Cold crystalloid cardioplegic solution (St. Thomas Hospital) was administered every 30 min during the ischemic period, and topical cooling with ice slush was added. The aortic clamp time was 225 min. After declamping, left ventricular contraction did not occur despite ventricular pacing. In consideration of the preoperative liver and respiratory dysfunction in addition to ischemic myocardial failure, we decided to apply a left VAD (LVAD) without trying intra-aortic balloon pumping (IABP).

The LVAD was an air-driven, diaphragm-type blood pump with an effective stroke volume of 70 ml (National Cardiovascular Center, Osaka, Japan) (4). The inflow cannula was inserted into the left atrium through the atrial septum under aortic cross-clamping. After declamping, the Dacron graft of the outflow cannula was anastomosed

* To whom correspondence should be addressed.

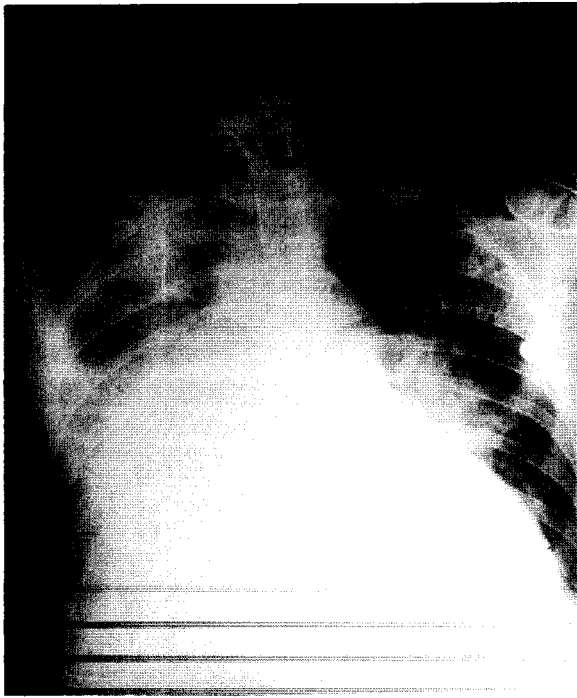


Fig. 1 Chest roentgenogram before operation showing cardiomegaly and pulmonary congestion. The intratracheal tube for respiratory support is visible.

end-to-side to the ascending aorta. The VAD was connected to the cannulae and driven in the non-synchronous fixed rate mode at 60 beats/min. CPB could be finally discontinued after 391 min. At the end of the operation, the LV-EF measured directly on the right ventricular surface by echocardiography was 10% with an arterial pressure of 113/60 mmHg, a mean pulmonary artery pressure (mPAP) of 37 mmHg, and a mean right atrial pressure (mRAP) of 17 mmHg under LVAD support.

Our weaning method from the pulsatile LVAD was as follows. During maximum left ventricular unloading by the LVAD, at first, the doses of inotropic agents such as dopamine and dobutamine were decreased as much as possible down to $5 \mu\text{g}/\text{kg}/\text{min}$. When systolic arterial pressure by the native heart had been stabilized above 100 mmHg for 24 h, the pumping rate was reduced daily by 5 beats/min to a minimum of 40 beats/min. When the pump-on/pump-off data obtained during a planned interruption for up to 1 min were satisfactory and also when mRAP was lower than 15 mmHg, the VAD support was terminated.

The postoperative course is illustrated in Fig. 2. Fig. 3 depicts serial determinations in the LV-EF by transth-

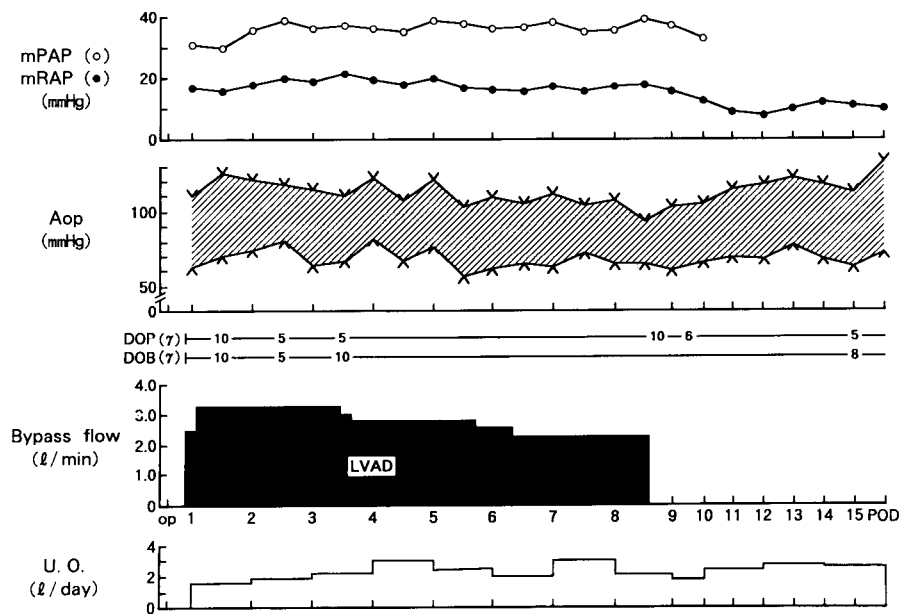


Fig. 2 Postoperative course. mPAP: mean pulmonary artery pressure, mRAP: mean right atrial pressure, Aop: aortic pressure, DOP: dopamine, DOB: dobutamine, U.O.: urine output, LAVD: left ventricular assist device.

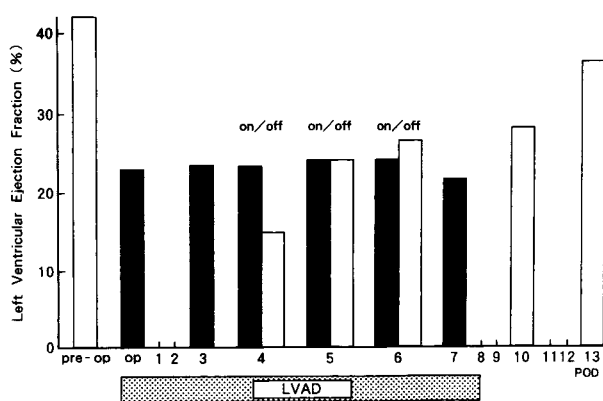


Fig. 3 Changes in the left ventricular ejection fraction during left ventricular assist device (LVAD) support after operation. (■): LVAD, on (□): LVAD, off.

oracic echocardiography. No left ventricular ejection was detected in the arterial pulse contour for the first 2 days. On the 3rd postoperative day (POD), left ventricular ejection was identified on the arterial pulse contour and the echocardiogram revealed an LV-EF of 23% under LVAD support. The pumping rate was then reduced to 55 beats/min. On the 4th POD, the pump diaphragm did not reach the end-diastolic position. Therefore, the pumping rate was reduced to 50 beats/min so that the LVAD could pump in a fill-to-empty condition. We judged that the limitation of the diaphragm movement was an indication that left ventricular function had been restored, and the first pump on/off test was carried out. While the pump was off, however, the LV-EF fell from 23.4% to 14.6%. The following day, the LV-EF at pump-on stayed the same as at pump-on (23.8%). On the 6th POD, the peak arterial pressure by left ventricular ejection increased above 100 mmHg which was greater than that by the LVAD. The LV-EF also increased from 23.8% to 26.8% with the pump off. Hence, the pumping rate was decreased to 45 beats/min. Although his hemodynamics had been stable with a mRAP of 18 mmHg, the support was kept on according to our weaning criteria and the pumping rate was reduced to 40 beats/min. On the 8th POD, the arterial pressure was adequate with a mRAP of 14 mmHg. The LVAD support could be uneventfully terminated after 186 h of pumping. The patient's condition thereafter remained stable; there were no signs of recurrent heart failure, infection or other

organ failures. The patient was discharged from the hospital on the 58th POD. Although the LV-EF was 25% at 1 month after the operation, it improved markedly to 54% at 6 months. After 1 year, the LV-EF increased to 57% and further improved to 64% during exercise stress testing with a bicycle ergometer.

Discussion

This patient with severe valvular heart disease was salvaged using an LVAD after double valve replacement. When the cardiac dysfunction is secondary to myocardial stunning, VAD can provide the heart valuable time to restore high-energy substrates, reduce myocardial edema and regain adequate ventricular function (4, 5). Thus, recovery of a failing myocardium with non-ischemic valvular heart disease seems more likely than that with ischemic heart disease.

The main causes of unsuccessful VAD support are mostly delay of the application of VAD and include irreversible heart failure and multiple organ failure (6-8). Therefore, deciding earlier whether to use a VAD is important to avoid such fatal complications. In this case, we used the LVAD without trying an IABP not only because of poor ventricular function after aortic declamping but also because of preoperative lung and liver dysfunctions. It is, however, open to discussion whether direct use of VAD is the best means of mechanical circulatory support in patients with severe heart failure. We believe that, in selected patients, especially those who develop other organ dysfunction preoperatively, direct application of VAD should be considered.

According to the report of Takano *et al.*, in 92 VAD patients, major causes of death after removal of VAD are multiple organ failure (16.3%) and recurrent heart failure (10.4%) (7). To prevent such complications, we continued the LVAD support not only until the failing ventricle had recovered but also until disturbed fluid balance such as high mRAP was improved.

The utility of echocardiography as a concomitant diagnostic tool in patients with VAD has been reported by some investigators (9-11). Nakatani *et al.* found that left ventricular function during LVAD support can be evaluated by changes in the left end-diastolic dimension, percent fractional shortening and preejection period/ejection time determined by echocardiography (12). In their report, however, it is unclear when left ventricular function recovered enough to be weaned from LVAD. Verani *et*

al. reported that the response of LV-EF to stepwise decreases in LVAD flow determined by radionuclide angiography was a good indicator of weaning a patient from LVAD and of long-term survival (13). In our case, the serial evaluation of the LV-EF by echocardiography was useful in predicting to what extent myocardial function recovered, and positive change in the LV-EF after turning off the pump was the key to weaning the patient from the LVAD. Although the weaning process should be performed based on hemodynamic data, our experience indicates that serial measurement of LV-EF coupled with hemodynamic assessment can provide more accurate information about left ventricular function during LVAD support.

References

1. Pae WE Jr, Miller CA, Matthews Y and Pierce WS: Ventricular assist device for postcardiotomy shock. *J Thorac Cardiovasc Surg* (1992) **104**, 541-553.
2. Pierce WS, Parr GVS, Myers JL, Pae WE Jr, Bull AP and Waldhausen JA: Ventricular-assist pumping in patients with cardiogenic shock after cardiac operations. *N Engl J Med* (1981) **305**, 1606-1610.
3. Termuhlen DF, Swartz MT, Pennington DG, Samuels LD, McBride LR, Kanter KR and Ruzevich SA: Predictors for weaning patients from ventricular assist devices (VADs). *Trans Am Soc Artif Intern Organs* (1987) **28**, 683-688.
4. Takano H, Taenaka Y, Nakatani T, Akutsu T and Manabe H: Successful treatment of profound left ventricular failure by automatic left ventricular assist system. *World J Surg* (1985) **9**, 78-88.
5. Pae WE Jr, Pierce WS, Pennock JL, Cambell DB and Waldhausen JA: Long-term results of ventricular assist pumping in postcardiotomy cardiogenic shock. *J Thorac Cardiovasc Surg* (1987) **93**, 434-441.
6. Pennington DG, Kanter KR, McBride LR, Kaiser GC, Barner HB, Miller LW, Neunheim KS, Fiore AC and Willman V: Seven years' experience with the Pierce-Donachy ventricular assist device. *J Thorac Cardiovasc Surg* (1988) **96**, 901-911.
7. Takano H, Taenaka Y, Noda H, Kinoshita M, Yagura A, Tatsumi E, Sekii H, Sasaki E, Umezu M, Nakatani T, Kyo S, Omoto R, Akutsu T and Manabe H: Multi-institutional studies of the National Cardiovascular Center ventricular assist system: Use in 92 patients. *Trans Am Soc Artif Intern Organs* (1989) **35**, 541-544.
8. Sato N, Mohri H, Sezai Y, Koyanagi H, Fujimasa I, Imachi K, Atsumi K, Nitta S and Miura M: Multi-institutional evaluation of the Tokyo University ventricular assist system. *Trans Am Soc Artif Intern Organs* (1990) **36**, M708-M711.
9. Kyo S, Matsumura M, Takamoto S and Omoto R: Transesophageal color doppler echocardiography during mechanical assist circulation. *Trans Am Soc Artif Intern Organs* (1989) **35**, 722-725.
10. Nasu M, Okada Y, Fujiwara H, Sono J, Nishiuchi S, Tatemichi K and Shomura T: Transesophageal echocardiographic findings of intracardiac events during cardiac assist. *Artif Organs* (1990) **14**, 377-381.
11. Brack M, Olson JD, Pedersen WR, Goldenberg IF, Gobel FL, Pritzker MR, Emery RW and Lange HW: Transesophageal echocardiography in patients with mechanical circulatory assistance. *Ann Thorac Surg* (1991) **52**, 1306-1309.
12. Nakatani T, Takano H, Beppu S, Noda H, Fukuda S, Fujita T, Akutsu T, Nimura Y and Manabe H: Natural heart recovery under left ventricular assist device pumping studied by echocardiography. *Trans Am Soc Artif Intern Organs* (1986) **27**, 461-466.
13. Verani MS, Sekela ME, Mahmarian JJ, Cocanougher B, DeBaKey ME and Noon GP: Left ventricular function in patients with centrifugal left ventricular assist device. *Trans Am Soc Artif Intern Organs* (1989) **35**, 544-547.

Received January 27, 1993; accepted January 10, 1994.