

Acta Medica Okayama

Volume 48, Issue 5

1994

Article 10

OCTOBER 1994

Quantitative measurement of portal blood flow by magnetic resonance phase contrast: comparative study of flow phantom and Doppler ultrasound in vivo.

Masatoshi Tsunoda* Shin Kimoto[†] Keisuke Hamazaki[‡]
Yoshihiro Takeda** Yoshio Hiraki^{††}

*Okayama Rousai Hospital,

[†]Okayama University,

[‡]Okayama University,

**Okayama University,

^{††}Okayama University,

Quantitative measurement of portal blood flow by magnetic resonance phase contrast: comparative study of flow phantom and Doppler ultrasound in vivo.*

Masatoshi Tsunoda, Shin Kimoto, Keisuke Hamazaki, Yoshihiro Takeda, and
Yoshio Hiraki

Abstract

A non-invasive method for measuring portal blood flow by magnetic resonance (MR) phase contrast was evaluated in a flow phantom and 20 healthy volunteers. In a flow phantom study, the flow volumes and mean flow velocities measured by MR phase contrast showed close correlations with those measured by electromagnetic flowmetry. In 20 healthy volunteers, the cross-sectional areas, flow volumes and mean flow velocities measured by MR phase contrast correlated well with those measured by the Doppler ultrasound method. Portal blood flow averaged during the imaging time could be measured under natural breathing conditions by using a large number of acquisitions without the limitations imposed on the Doppler ultrasound method. MR phase contrast is considered to be useful for the non-invasive measurement of portal blood flow.

KEYWORDS: portal blood flow, magnetic resonance imaging, phase contrast

*PMID: 7863800 [PubMed - indexed for MEDLINE]

Copyright (C) OKAYAMA UNIVERSITY MEDICAL SCHOOL

Quantitative Measurement of Portal Blood Flow by Magnetic Resonance Phase Contrast: Comparative Study of Flow Phantom and Doppler Ultrasound *In Vivo*

MASATOSHI TSUNODA*, SHIN KIMOTO^a, KEISUKE HAMAZAKI^b, YOSHIHIRO TAKEDA^a AND YOSHIO HIRAKI^a

Department of Radiology, Okayama Rousai Hospital, Okayama 702, and ^aDepartment of Radiology and ^bFirst Department of Surgery, Okayama University Medical School, Okayama 700, Japan

A non-invasive method for measuring portal blood flow by magnetic resonance (MR) phase contrast was evaluated in a flow phantom and 20 healthy volunteers. In a flow phantom study, the flow volumes and mean flow velocities measured by MR phase contrast showed close correlations with those measured by electromagnetic flowmetry. In 20 healthy volunteers, the cross-sectional areas, flow volumes and mean flow velocities measured by MR phase contrast correlated well with those measured by the Doppler ultrasound method. Portal blood flow averaged during the imaging time could be measured under natural breathing conditions by using a large number of acquisitions without the limitations imposed on the Doppler ultrasound method. MR phase contrast is considered to be useful for the non-invasive measurement of portal blood flow.

Key words: portal blood flow, magnetic resonance imaging, phase contrast

Portal blood flow measurement is considered to be important for the analysis of hemodynamics in various liver diseases (1-4). The Doppler ultrasound method has been used extensively during the past several years for measuring portal blood flow as a non-invasive method. In this study, we measured the blood flow in the main trunk of the portal vein as a novel application of magnetic resonance (MR) phase contrast (5-7) to the abdominal region. A comparative study was also conducted between the MR phase contrast and Doppler ultrasound methods.

Materials and Methods

A flow phantom was used in the basic study. Twenty normal adult volunteers free from liver disorders were used as the subjects in the actual measurement of portal blood flow. A 0.5-T superconducting MR imaging system (Resona: Yokogawa Medical Systems, Tokyo, Japan) was used. Images were obtained using the body coil according to the pulse sequence indicated in Fig. 1 with a repetition time of 80 msec and a echo time of 42 msec. The field of view was 350 mm. Image matrix was 256×192 . The flip angle of the radio frequency pulses was 30 degrees. The number of acquisitions was 16 and the slice thickness was 10 mm. The flow volumes and mean flow velocities were measured using the phase images. A Toshiba SSA-270A (Toshiba Medical, Tokyo, Japan) was used to measure the portal blood flow by the Doppler ultrasound method.

Principle. Gradient echo sequences were used in which a bipolar flow-encoding gradient was applied in the direction of the slice. The polarity of the flow-encoding gradient is inverted for each acquisition of data (5-7). The pulse sequence is indicated in Fig. 1. Fig. 2 indicates the relationship between the flow-encoding gradient and the induced phase shift. The amount of phase shift θ for each pixel is expressed in the manner of equation (Eq.) 1, if the velocity is taken to be constant (5-7):

$$\theta = \gamma AgVT \quad (\text{Eq. 1})$$

where γ is the gyromagnetic ratio, Ag is the area of the positive lobe of the bipolar flow-encoding gradient pulse and T is the time between the center of the lobes of the

* To whom correspondence should be addressed.

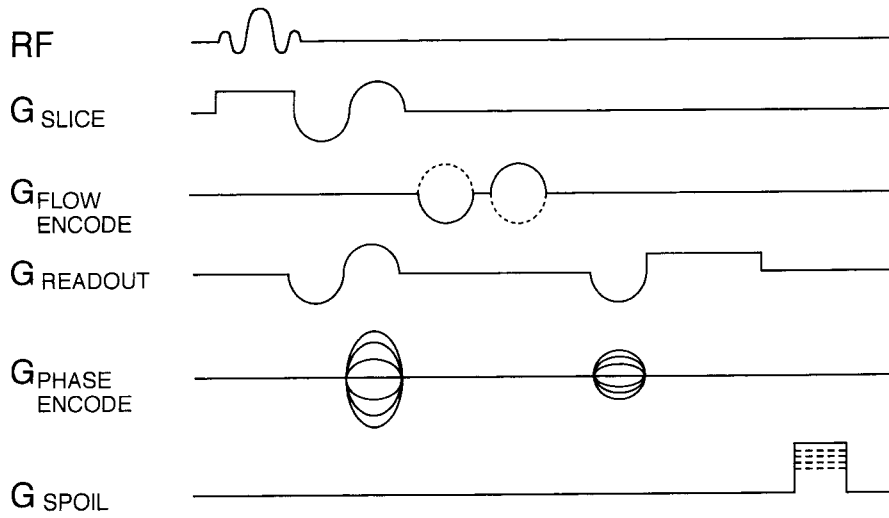
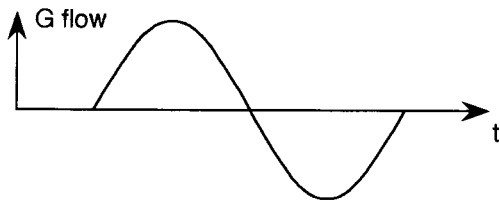
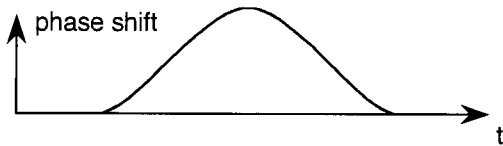


Fig. 1 Pulse sequence used in this study. This pulse sequence was repeated with inverted flow encoding gradients, as shown by the dashed lines. First-order flow compensation was incorporated in all directions. In this study, flow encoding gradients were in the slice direction. RF: radio frequency pulse. G: gradient.

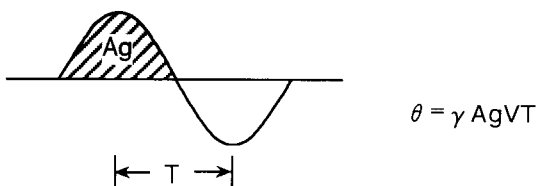
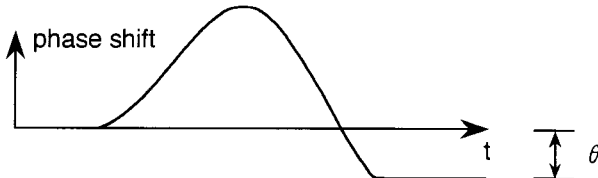
flow-encoding gradient



stational tissue



steady flow



bipolar pulse. V is the steady flow velocity.

The data are acquired for alternating polarities of flow-encoding gradients and subtracted as indicated in Fig. 3. Thus, as expressed in Eq. 2, the measured phase shift ϕ is twice as much as that induced by flow by one scan.

$$\phi = 2\theta = 2\gamma AgVT. \quad (\text{Eq. 2})$$

Actually, since static sites also produce a certain degree of phase shift mainly due to the effects of eddy currents, the amount of phase shift from those static sites is shown to be the mean phase error. As indicated in Eq. 3, the difference between the measured phase shift in the region of interest (ROI) and the mean phase error in the static sites is considered to be the phase shift due to flow. Flow velocity (V) is then determined by Eq. 3:

$$V = \frac{\text{ROI} - \text{MPE}}{\text{MAX}} \cdot \text{ROV}. \quad (\text{Eq. 3})$$

ROI: Measured phase shift in the region of interest (as ROI value)

Fig. 2 Relationship between flow encoding gradient and the phase shift of the spins. θ is the velocity-induced phase shift. γ is the gyromagnetic ratio. Ag is the area of the positive lobe of bipolar gradient pulse and T is the time between the center of the lobes of the bipolar pulse. V is the steady flow velocity.

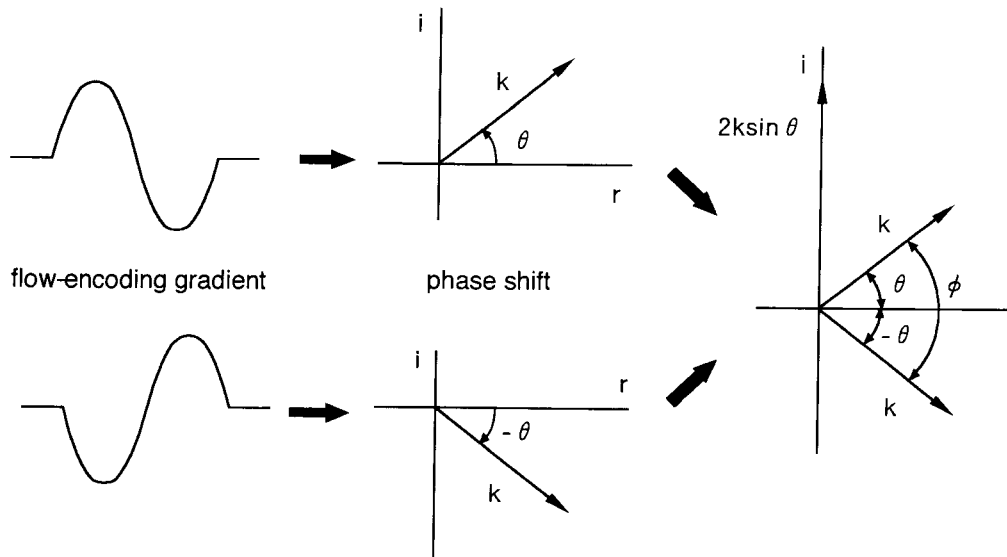


Fig. 3 Relationship between vector subtraction of the acquired data sets with inverted flow-encoding gradient and the measured phase shift ϕ in the phase image. θ is the velocity-induced phase shift. $-\theta$ is the phase shift with inverted flow-encoding gradient. Both vectors have a magnitude of k . Complex subtraction yields the vector whose magnitude is $2k \sin \theta$. $\phi = 2\theta$ is obtained from the phase image.

MPE: Mean phase error (as ROI value)

MAX: Maximum value of the phase image ($= 500\pi$ in this study)

ROV: Range of velocity ($= 40 \text{ cm/sec}$ in this study)

In the phase images used in this study, the ROI value reached the maximum value ($= 500\pi$) when the phase shift was 180 degrees. Range of velocity (ROV) was the velocity when the phase shift was 180 degrees and was calculated from Eq. 2. Considering the velocity of portal blood flow *in vivo*, ROV was set at 40 cm/sec.

Flow phantom study. A polyvinyl chloride tube (inside diameter: 10mm) was passed straight through a water bath filled with degassed water. Physiological saline solution was circulated through the tube with a pump. The flow volume was adjusted while measuring with an electromagnetic flowmeter (MFV3100: Nippon Koden). The flow volumes and mean flow velocities in the tube were measured by MR phase contrast at a cross-sectional slice perpendicular to the tube while changing the flow volume over the range of 4–22 cm³/sec. Those results were compared with the values obtained from the electromagnetic flowmeter.

Measurement of portal blood flow in healthy volunteers. All studies on healthy volunteers were performed under natural breathing conditions.

After the main trunk of the portal vein was represented with a pilot scan using coronal sections, the imaging plane was set perpendicular to the main trunk of the portal vein. Imaging was performed using the rapid scan technique (6) without synchronization to electrocardiogram, pulse wave or respiration. The cross-sectional areas, flow volumes and mean flow velocities were measured nearly at the central level of the main trunk of the portal vein in 20 healthy volunteers. In addition, the cross-sectional areas, flow volumes and mean flow velocities were measured while interrupting breathing using Doppler ultrasound according to the method of Moriyasu *et al.* (1). Those results were compared with the MR measurements.

Results

Flow phantom study. The results of measurements of the flow volumes and mean flow velocities using the electromagnetic flowmeter and MR phase contrast are indicated in Figs. 4 and 5. The flow volumes and mean flow velocities measured by the MR phase contrast showed close correlations with those measured with the electromagnetic flowmeter.

Measurement of portal blood flow in healthy volunteers. Typical images are indicated

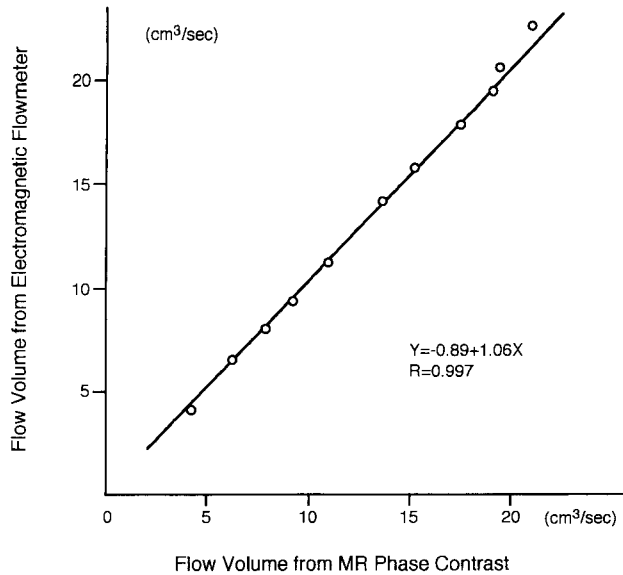


Fig. 4 Correlation between the flow volumes measured by MR phase contrast and electromagnetic flowmeter.

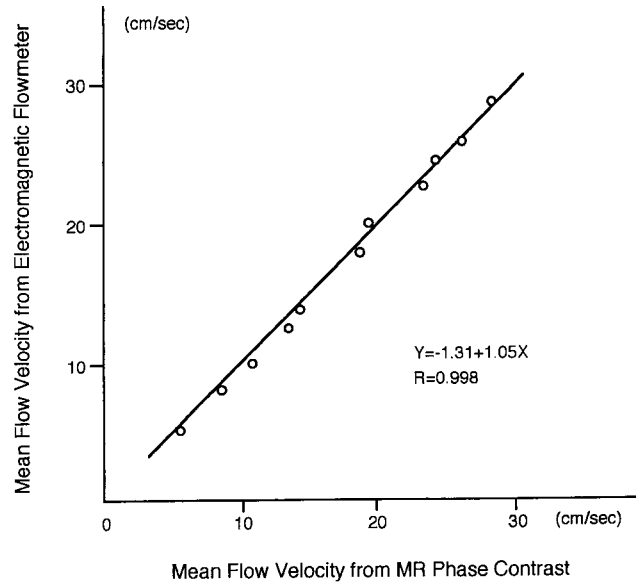


Fig. 5 Correlation between the mean flow velocities measured by MR phase contrast and electromagnetic flowmeter.

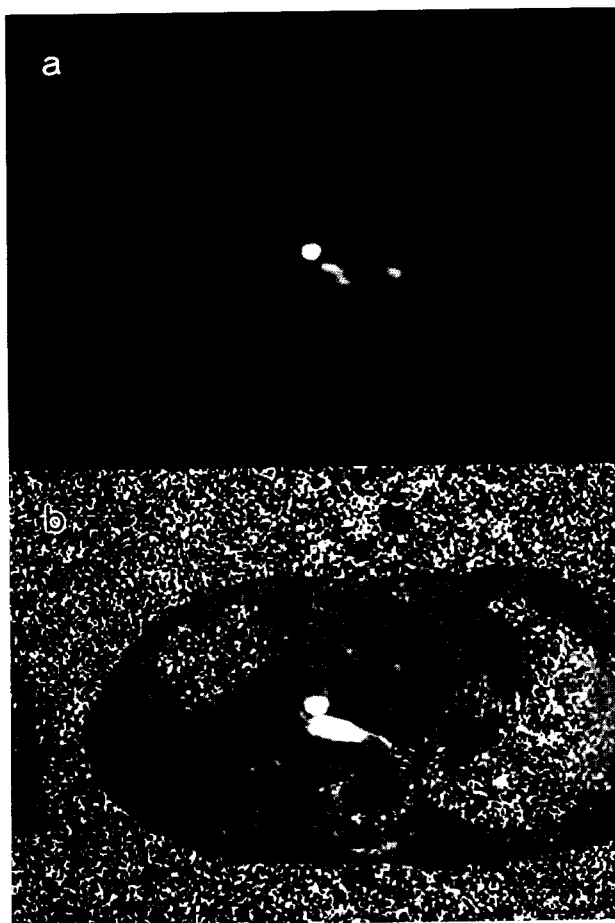


Table 1 Portal blood flow in 20 volunteers measured by MR phase contrast method and Doppler ultrasound method

	MR Phase Contrast Method	Doppler Ultrasound Method
Mean flow velocity(cm/sec)	11.2 ± 1.7	12.2 ± 1.3
Flow volume(cm ³ /sec)	12.0 ± 3.3	12.5 ± 3.2
Cross-sectional area(cm ²)	1.07 ± 0.21	1.05 ± 0.21

in Fig. 6. Figs. 6a and 6b were obtained from the same data set. Fig. 6a is a modulus image which is used for MR angiography, and Fig. 6b is a phase image which is used for flow quantification. The cross-sectional areas, flow volumes and mean flow velocities of the main trunk of the portal vein which were measured by MR phase contrast and Doppler ultrasound method in 20 volunteers (age: 24-55; men: 10; women: 10) are shown in Table 1. Good correlation between the MR phase contrast and Doppler ultrasound methods are indicated in Figs. 7 and 8.

Fig. 6 Portal blood flow images in a healthy volunteer. a: modulus image b: phase image

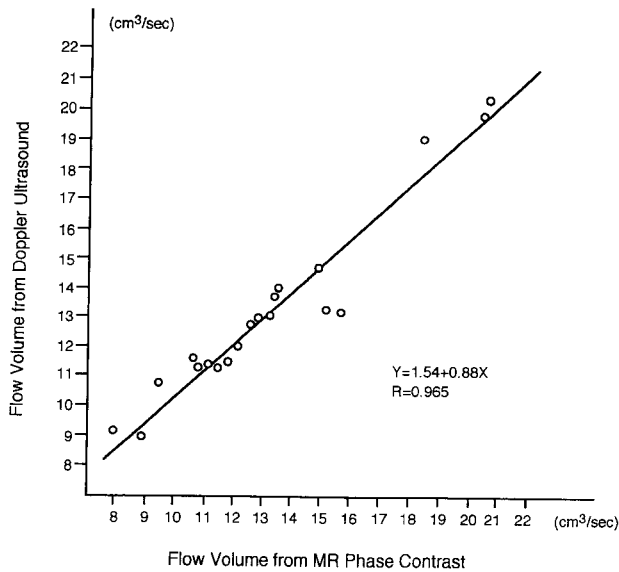


Fig. 7 Correlation between the flow volumes measured by the MR phase contrast and Doppler ultrasound methods in 20 normal volunteers.

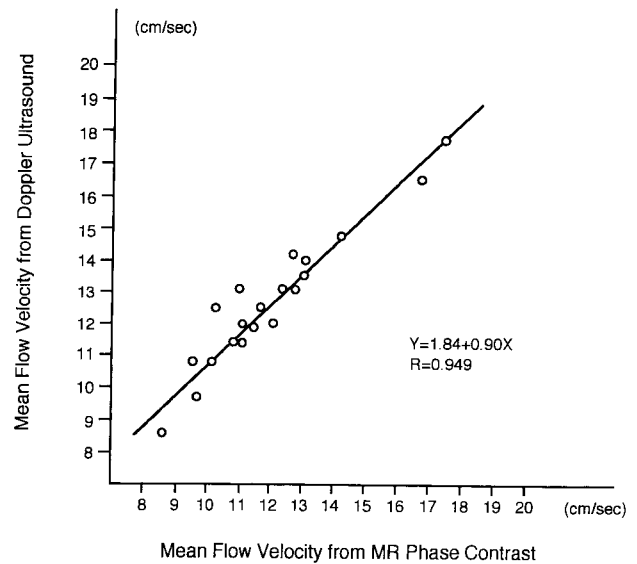


Fig. 8 Correlation between the mean flow velocities measured by the MR phase contrast and Doppler ultrasound methods in 20 normal volunteers.

Discussion

After Dumoulin *et al.* first reported MR angiography using MR phase contrast in 1986 (5), research has been conducted on MR phase contrast with emphasis on the visualization of flow. However, quantitative measurement of blood flow is also possible using phase images. Although studies of flow measurement using flow-induced phase shift have been reported (8-12), this technique is advantageous in that it emphasizes the phase shift induced by flow and minimizes noise components. In addition, compared to methods not based on phase contrast, this technique only requires half the amount of flow-encoding gradient pulses. This is advantageous when measuring slow flow, which requires comparatively large flow-encoding gradient pulses. Although there are scattered reports of the application of the time-of-flight technique to portal blood flow measurement (13, 14), it requires breath holding and it is difficult to measure the mean velocity of blood flow due to its velocity profile.

In our study, portal blood flow could be measured under natural breathing conditions by averaging the data from a large number of acquisitions. The MR phase contrast method has the advantage of being able to

measure portal blood flow in patients who can not hold their breath.

The diameter and flow velocity of the portal vein change due to respiration, and the portal vein trunk moves as the subject breathes. Furthermore, the pulsatility of the portal vein is observed in normal adults (especially young women) and in patients with congestive cardiac insufficiency (15, 16) on Doppler ultrasound examinations. A large number of acquisitions averages these motions and changes of the velocity, and it averages phase shift errors of static portions of the subject. In addition, motion artifacts and flow artifacts are suppressed by averaging.

In the basic study using a flow phantom, measured values obtained from an electromagnetic flowmeter and measured values obtained from MR phase contrast were in close agreement. Although there are differences in the measurement conditions between the MR phase contrast and Doppler ultrasound methods, a favorable correlation was demonstrated in actual measurements.

An imaging time of just under 8 min is required to increase the number of acquisitions. However, averaged blood flow can be measured and the examination itself is simple.

While the Doppler ultrasound method has the advan-

tages of being able to perform examinations comparatively easy and to measure the velocity of blood flow in real time, there are certain problems associated with it. First, the angle of the Doppler ultrasound beam in relation to the main trunk of the portal vein is critical to obtain accurate measurement. Second, much intestinal gas and large amounts of fat (as in cases of obesity) will block the beam. Third, measurement may not be possible in elderly persons who are not able to hold their breath effectively. Fourth, it requires a high degree of technical skill. MR measurements can be performed without these limitations. In addition, the method employed in this study allows measurement of the mean blood flow averaged during the imaging time under natural breathing conditions. This method is considered to be useful for the measurement of portal blood flow.

Acknowledgments. The authors would like to thank all the staff of the Department of Radiology, Kohsei Hospital for their support and valuable discussions.

References

- Moriyasu F, Ban N, Nishida O, Nakamura T, Koizumi S, Sakai M, Kanematsu Y, Miyake T and Uchino H: Quantitative measurement of portal blood flow in patients with chronic liver disease using an ultrasonic duplex system consisting of a pulsed doppler flowmeter and B-mode electroscanner. *Gastroenterol Jpn* (1984) **19**, 529-536.
- Ohnishi K, Saito M, Nakayama T, Iida S, Nomura F, Koen H and Okuda K: Portal venous hemodynamics in chronic liver disease: Effect of posture change and exercise. *Radiology* (1985) **155**, 757-761.
- Zoli M, Marchesini G, Cordiani MR, Pisi P, Brunori A, Trono A and Pisi E: Echo-doppler measurement of splanchnic blood flow in control and cirrhotic subjects. *J Clin Ultrasound* (1986) **14**, 429-435.
- Burns P, Taylor K and Blei AT: Doppler flowmetry and portal hypertension. *Gastroenterology* (1987) **92**, 824-826.
- Dumoulin CL and Hart HR: Magnetic resonance angiography. *Radiology* (1986) **161**, 712-720.
- Dumoulin CL, Souza SP and Hart HR: Rapid scan magnetic resonance angiography. *Magn Reson Med* (1987) **5**, 238-245.
- Dumoulin CL, Souza SP, Walker MF and Yoshitome E: Time-resolved magnetic resonance angiography. *Magn Reson Med* (1988) **6**, 275-286.
- Bryant DJ, Payne JA, Firmin DN and Longmore DB: Measurement of flow with NMR imaging using a gradient pulse and phase difference technique. *J Comput Assist Tomogr* (1984) **8**, 588-593.
- Moran PR, Moran RA and Karstaedt N: Verification and evaluation of internal flow and motion. *Radiology* (1985) **154**, 433-441.
- Wedeen VJ, Rosen BR, Chesler D and Brady TJ: MR velocity imaging by phase display. *J Comput Assist Tomogr* (1985) **9**, 530-536.
- Wedeen VJ, Rosen BR, Buxton R and Brady TJ: Projective MRI angiography and quantitative flow-volume densitometry. *Magn Reson Med* (1986) **3**, 226-241.
- Hennig J, Muri M, Brunner P and Friedburg H: Quantitative flow measurement with the fast fourier flow technique. *Radiology* (1988) **166**, 237-240.
- Edelman RR, Zhao B, Liu C, Wentz KU, Mattle HP, Finn JP and McArdle C: MR angiography and dynamic flow evaluation of the portal venous system. *Am J Roentgenol* (1989) **153**, 755-760.
- Tamada T, Moriyasu F, Ono S, Shimizu K, Kajimura K, Soh Y, Kawasaki T, Kimura T, Yamashita Y, Someda H, Hamato N and Uchino H: Portal blood flow: Measurement with MR imaging. *Radiology* (1989) **173**, 639-644.
- Duerinckx AJ, Grant EG, Perrella RR, Szeto A and Tessler FN: The pulsatile portal vein in cases of congestive heart failure: Correlation of duplex doppler findings with right atrial pressures. *Radiology* (1990) **176**, 655-658.
- Abu-Yousef MM, Milam SG and Farner RM: Pulsatile portal vein flow: A sign of Tricuspid Regurgitation on duplex doppler sonography. *Am J Roentgenol* (1990) **155**, 785-788.

Received July 13, 1994; Accepted August 1, 1994.