

# *Acta Medica Okayama*

---

*Volume 42, Issue 6*

1988

*Article 6*

DECEMBER 1988

---

## Results of surgery for aortic regurgitation due to aortic valve prolapse.

Masaharu Shigenobu\*

Yoshimasa Senoo<sup>†</sup>

Shigeru Teramoto<sup>‡</sup>

\*Okayama University,

<sup>†</sup>Okayama University,

<sup>‡</sup>Okayama University,

# Results of surgery for aortic regurgitation due to aortic valve prolapse.\*

Masaharu Shigenobu, Yoshimasa Senoo, and Shigeru Teramoto

## Abstract

The clinical, hemodynamic and pathological findings of 13 patients with aortic regurgitation due to aortic valve prolapse caused by advanced myxomatous degeneration were evaluated. Eleven patients showed a favorable outcome with no complications resulting from surgery. One patient died from aortic dissection, and another died suddenly from an unknown cause. Five patients had mitral valve prolapse as a complication. Ten patients (77%) had a long-standing history of hypertension. Twelve patients (92%) were male. None of the patients had the stigmata of Marfan's syndrome. All patients had marked myxomatous degeneration of the aortic valves without any inflammatory changes. Two patients showed microcalcification; 7 demonstrated moderate fibrosis. Five patients showed severe fragility of the cusps which appeared redundant, gelatinous and softened by degenerative changes. Myxomatous degeneration of the aortic valve is not rare, and, in fact, it may be one of the most common pathologic and clinical entities associated with pure aortic insufficiency.

**KEYWORDS:** aortic valve prolapse, aortic regurgitation, myxomatous degeneration, surgical outcome

---

\*PMID: 3239439 [PubMed - indexed for MEDLINE]

Copyright (C) OKAYAMA UNIVERSITY MEDICAL SCHOOL

## Results of Surgery for Aortic Regurgitation Due to Aortic Valve Prolapse

Masaharu Shigenobu\*, Yoshimasa Senoo and Shigeru Teramoto

*Second Department of Surgery, Okayama University Medical School, Okayama 700, Japan*

The clinical, hemodynamic and pathological findings of 13 patients with aortic regurgitation due to aortic valve prolapse caused by advanced myxomatous degeneration were evaluated. Eleven patients showed a favorable outcome with no complications resulting from surgery. One patient died from aortic dissection, and another died suddenly from an unknown cause. Five patients had mitral valve prolapse as a complication. Ten patients (77%) had a long-standing history of hypertension. Twelve patients (92%) were male. None of the patients had the stigmata of Marfan's syndrome. All patients had marked myxomatous degeneration of the aortic valves without any inflammatory changes. Two patients showed microcalcification; 7 demonstrated moderate fibrosis. Five patients showed severe fragility of the cusps which appeared redundant, gelatinous and softened by degenerative changes. Myxomatous degeneration of the aortic valve is not rare, and, in fact, it may be one of the most common pathologic and clinical entities associated with pure aortic insufficiency.

*Key words* : aortic valve prolapse, aortic regurgitation, myxomatous degeneration, surgical outcome

Myxomatous degeneration has been recognized as underlying pathologic state in aortic valve prolapse. Pure aortic valve insufficiency with no history of rheumatic fever may be caused by aortic valve prolapse. Aortic regurgitation without apparent cause and its possible relation to aortic valve prolapse has assumed increasing clinical importance and aroused considerable interest. This study presents the clinical, hemodynamic and pathological findings of 13 patients with aortic regurgitation due to aortic valve prolapse.

### Patients and Methods

From January 1976 to December 1987, we evaluated 13 patients with aortic regurgitation due to severe myxomatous degeneration of the aortic valves. Of the 13 patients, 12 were male and only one was female; the mean age was 45.5 years. According to the New York Heart Association (NYHA) classification, 9 patients were in Class II, 3 in Class III and 1 in Class IV. Ten had a history of congestive heart failure. The mean cardiothoracic ratio was 54.7% (Table 1).

Complicating lesions included essential hypertension (10 cases), mitral valve prolapse (5 cases), coronary artery fistula (1 case) and bicuspid aortic valve (2 cases). Hypertension was

\* To whom correspondence should be addressed.

Table 1 Clinical characteristics of 13 patients with aortic regurgitation due to aortic valve prolapse

Patient	Age (yr) & Sex	NYHA Class	History of CHF	CTR (%)	Systemic hypertension	Secondary lesion	Bicuspid aortic valve	Aortic root diameter (mm)	AR (0-4+)	Valve prosthesis & Size	Outcome
1	23M	II	+	61	+	—	—	35	3+	Starr-Edwards (#9)	Good
2	40M	II	+	52	+	—	—	36	4+	Björk-Shiley (#23)	Good
3	22M	II	—	50	+	MVP	Bicuspid	40	4+	Lillehei-Kaster (#18)	Good
4	31M	II	—	50	+	MVP	—	39	3+	Omniscience (#25)	Good
5	57M	II	+	55	+	—	—	30	4+	Omniscience (#25)	Died from aortic dissection 2 years after operation
6	47M	IV	+	50	—	—	—	32	4+	Omniscience (#25)	Died suddenly 3 years after operation
7	38M	III	+	50	—	Coronary fistula	—	34	3+	Omniscience (#25)	Good
8	46M	II	+	57	—	MVP (Mild MR)	—	37	3+	Omniscience (#25)	Good
9	58M	II	+	62	+	MVP (Mild MR)	Bicuspid	30	3+	Omniscience (#23)	Good
10	64F	II	—	58	+	—	—	35	2+	Omniscience (#21)	Good
11	63M	II	+	57	+	—	—	39	4+	Omniscience (#25)	Good
12	60M	III	+	55	+	—	—	39	4+	St. Jude Medical (#23)	Good
13	63M	III	+	58	+	MVP	—	36	4+	St. Jude Medical (#23)	Good

Abbreviations: NYHA, New York Heart Association; CHF, congestive heart failure; CTR, cardio-thoracic ratio; AR, aortic regurgitation; MR, mitral regurgitation; MVP, mitral valve prolapse.

defined as a condition in which the maximum systemic pressure was more than 165 mmHg. The mean aortic root diameter measured by echocardiogram was 35.2 mm. According to Seller's classification, the grade of aortic regurgitation was 4/4 in 7 cases, 3/4 in 5 cases and 2/4 in 1 case. Cardiac function was within normal limits in 9 patients. The remaining 4 patients showed poor left ventricular function.

Aortic valve replacement was performed in all patients. The prosthetic valves used were Starr-Edwards valve (1 case), Björk-Shiley valve (1 case), Lillehei-Kaster valve (1 case), Omniscience valve (6 cases), Omnicarbon valve (2 cases) and St. Jude Medical valve (2 cases) (Table 1). Gross and microscopic examinations of all excised valves were performed, and correlations between the clinical, hemodynamic and pathologic findings were evaluated.

Gross findings of interest were the number and thickness of valve cusps and the presence and degree (graded mild, moderate or severe) of the fragility of the cusps. Severe fragility indicates that thin, translucent regions are present in each leaflet.

Histologic sections of formalin-fixed valves were reviewed retrospectively. Sections were stained with hematoxylin-eosin and alcian blue/PAS. Histologic findings were graded from 0 to +3, to indicate no, mild, moderate or severe abnormalities. The abnormalities so graded included the presence of increased amounts of acid mucopolysaccharides, disruption of the pars fibrosa, cystic degeneration of the spongiosa layer, valvular calcification and fibrosis. The histologic material was also evaluated for the presence or absence of inflammatory changes. The diagnosis of myxomatous degeneration was strictly limited to valves that had +2 or greater acid mucopolysaccharide deposition and a +2 or greater disruption of the pars fibrosa.

## Results

Follow-up studies of 11 patients for periods ranging from 4 to 144 months showed a generally favorable outcome, but one patient died from aortic dissection and one died

**Table 2** Summary of gross and microscopic changes of 13 aortic valves in aortic valve prolapse

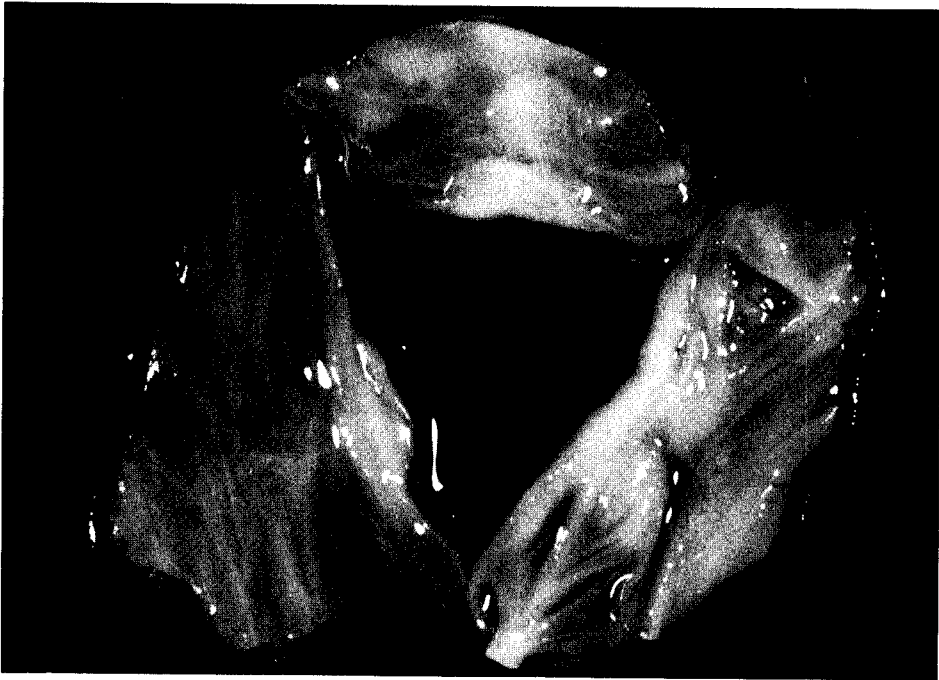
Grade	Fragility	Fibrosis	Calcification	Myxomatous degeneration
Mild	3	4	2	0
Moderate	5	9	0	0
Severe	5	0	0	13

suddenly from an unknown cause, 2 and 3 years after surgery, respectively (Table 1). These two patients had severely compromised ventricular function before surgery.

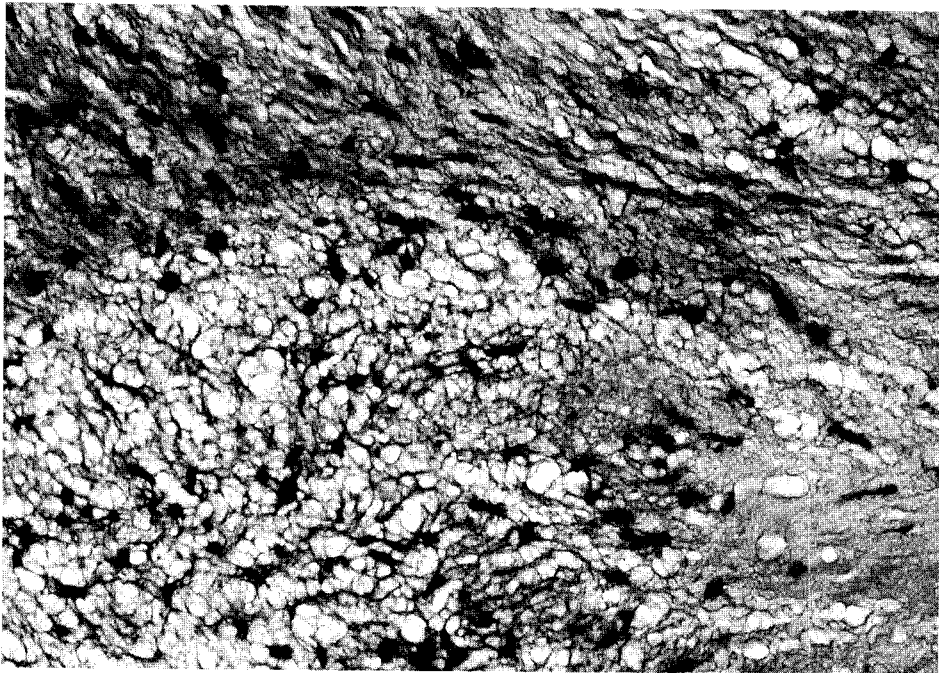
Pathological findings (Table 2) were as follows. The surgically excised aortic cusps appeared redundant, fragile and thin (Fig. 1). The commissures were not fused, but the edges were partly thickened. Microscopic examination in all cases revealed advanced myxomatous degeneration of the pars fibrosa without any inflammatory changes (Fig. 2). Two cases showed microcalcification, and 9 cases showed moderate fibrosis, especially on the surface of both the ventricular and aortic aspects of the cusps. Five cases showed severe fragility of the cusps which appeared gelatinous, softened and swollen by degenerative changes. Diffuse abnormalities characteristic of rheumatic valvular disease were not present. Despite these gross differences, the histologic features of the 13 aortic valves were similar and consisted of increased and disorganized elastic and collagen fibers with variable quantities of acid mucopolysaccharide.

## Discussion

In 1959, Weaver (1) first described myxomatous degeneration of the aortic valve. Read (2) reported nine cases of valvular myxomatous degeneration, proved either at surgery or autopsy, and called the condition the "floppy valve syndrome". Since then,



**Fig. 1** Gross appearance of the aortic valve. Three aortic cusps appear redundant, fragile and thin.



**Fig. 2** Microscopic findings (hematoxylin-eosin stain,  $\times 200$ ) showing advanced myxomatous degeneration of the aortic cusp without any inflammatory changes.

there has been much discussion, especially about mitral valve prolapse. However, the natural course and surgical outcome of the degenerative process involving the aortic valve are uncertain.

In patients who have annulo-aortic ectasia, the pathological findings include various grades of cystic medial necrosis of the aortic wall, as well as a disruption of the fibrous lamina of the cusps by myxomatous degeneration. In these patients, aortic annular and aortic root dilatation contributes to aortic regurgitation. The present patients, however, showed an approximately normal-sized aortic ring associated with marked degeneration of the aortic cusps which caused significant aortic regurgitation, suggesting that aortic root dilatation was not a major cause of the regurgitation.

In this study, the most remarkable change was downward prolapse of one or two aortic cusps. These prolapsed cusps showed +2 or greater fragility in gross appearance. Histologic observation revealed marked myxomatous degeneration of the fragile cusps. It is suspected that aortic regurgitation in this clinical entity is caused by the fragility of the cusps due to advanced myxomatous degeneration. Therefore, our clinical, surgical and morphological findings indicate that myxomatous changes in the aortic cusps are in themselves responsible for aortic regurgitation.

Pathological observation disclosed marked myxomatous degeneration of the aortic cusps in all cases, but the process was quite variable in individual patients. Eleven patients showed very thin, fragile and gelatinous valves, while 2 cases showed microcalcification with thick, fibrous edges of the cusps. Repetitious hemodynamic stresses, such as those imposed by hypertension over many years, could predispose the valve to further degenerative changes, with the end result being a thickened, distorted and often

grossly insufficient valve. Microscopically, increased myxomatous tissue may appear at an early stage in the degenerative process, while later the calcific process could be more prominent (3).

Echocardiography is one of the most useful tools for evaluating valve prolapse, and it plays an important diagnostic role, especially in the diagnosis of mitral or tricuspid valve prolapse, because of the rather large diameter of the annulus. However, echocardiography may be somewhat more difficult in aortic valves, because the aortic annulus is smaller and the aortic cusps are less voluminous and less echoreflexive. Therefore, it seems reasonable to perform echocardiographic examinations of all cardiac valves in patients with known or suspected valve prolapse and in patients with pure valvular insufficiency in whom valve replacement is intended. In contrast, we could not identify aortic valve prolapse by aortography. From our experience, echocardiography appears to be more useful than angiography in diagnosis.

The incidence of floppy aortic valve varies widely. This variability may be in part the result of problems of definition and the lack of a standard for clinical diagnosis. Davies (4) reported only a 2% prevalence of floppy aortic valve in patients with aortic regurgitation. Allen (5) described marked myxomatous changes in 20 out of 55 patients (36%). Floppy aortic and mitral valves are recognized as common morphological expressions of multivalvular degenerative disease. Thus, myxomatous degeneration may involve the tricuspid and pulmonary valves. We have seen 5 patients with floppy aortic and mitral valves. Of these, two patients had mild mitral regurgitation as well as aortic regurgitation. Rippe (6) reported that 3% of patients with mitral valve prolapse also had aortic valve prolapse. On the other hand, Ogawa (7) reported 16%, and Marde-

Ili (8) reported 20%. Lakier (3) reported that more than half of the patients who underwent aortic valve replacement for pure aortic insufficiency revealed severe myxomatous changes of the cusps, and he emphasized that aortic valve prolapse was the most important cause of pure aortic regurgitation. In 13 out of 68 patients (19%) operated upon at our institute during the same period, the cause was considered to be myxomatous changes. The prevalence of isolated aortic valve prolapse may be shown to be more common than was originally suspected, because of the availability of sensitive noninvasive techniques such as two-dimensional echocardiography.

A small degree of myxomatous degeneration is generally present in most cardiac valves, and this may represent a non-specific change related to aging or a response to normal hemodynamic stress. As reported in the present study, however, all valves surgically excised revealed diffuse myxomatous degeneration in almost all areas of the aortic cusps.

The pathogenesis of myxomatous degeneration of the aortic valve remains largely unknown. Allen (5) reported that patients with myxomatous degeneration had a fairly uniform clinical profile; namely, 85% were male and 77% had a long-standing history of systemic hypertension. The statistics of our study (92% male, 77% history of hypertension) are coincident with those of Allen (5). From these results, hypertension appears to be associated with valve degeneration and may be causally related.

The severity of the degeneration in our 13 patients indicates a pathologic process that may carry over into the postoperative period. A fatal dissecting aortic aneurysm occurred in one patient 2 years after aortic valve replacement.

Stewart (9) reported that aortic valve prolapse occurred often in patients with

non-calcified bicuspid valves. Shapiro (10) showed that the most common lesion was prolapse of the larger cusp in bicuspid valves, so that bicuspid aortic valves might well be important in producing such regurgitation.

Four patients (31%) in the present study showed characteristic clinical findings that occurred suddenly and accompanied by rapid deterioration necessitating an emergency operation once symptoms appeared. Two of the patients had more complications during the operation. These observations indicate that surgical intervention should be instituted in such patients, even though they are asymptomatic, once significant aortic regurgitation is detected by Doppler echocardiography.

Concerning the selection of surgical methods, valve replacement rather than repair should be performed because of the progressive nature of the disease. Clinical findings did not reveal any evidence of perivalvular leakage in our series. We have always implanted a prosthesis of slightly larger size than the measured aortic annulus. We have supported the sutures with pledgets, since there is a tendency for disruption of suture lines and dehiscence of valve prostheses, related to fragility of the valve annulus, the aorta or both.

## References

1. Weaver WF, Edwards JE and Brandenburg RO: Idiopathic dilatation of aorta with aortic valvular insufficiency. *Proc Mayo Clin* (1959) **34**, 518-522.
2. Read RC, Thal AP and Wendt VE: Symptomatic valvular myxomatous transformation (the floppy valve syndrome). *Circulation* (1965) **32**, 897-910.
3. Lakier JB, Copans H, Rosman HS, Lam R, Fine G, Khaja F and Goldstein S: Idiopathic degeneration of the aortic valve: a common cause of isolated aortic regurgitation. *J Am Coll Cardiol* (1985) **5**, 347-351.
4. Davies MJ, Moore BP and Braimbridge MV: The floppy mitral valve: study of incidence, pathology



- and complications in surgical, necropsy and forensic material. *Br Heart J* (1978) **40**, 468-481.
5. Allen WM, Matloff JM and Fishbein MC: Myxoid degeneration of the aortic valve and isolated severe aortic regurgitation. *Am J Cardiol* (1985) **55**, 439-444.
  6. Rippe J, Fishbein MC, Carabello B, Angoff G, Sloss L, Lollins JJ and Alpert J: Primary myxomatous degeneration of cardiac valves: clinical, pathological, hemodynamic, and echocardiographic profile. *Br Heart J* (1980) **44**, 621-629.
  7. Ogawa S, Hayashi J, Sasaki H, Tani M, Akaishi M, Mitamura H, Sano M, Hoshino T, Handa S and Nakamura Y: Evaluation of combined valvular prolapse syndrome by two-dimensional echocardiography. *Circulation* (1982) **65**, 174-180.
  8. Mardelli TJ, Morganroth J, Naito M and Chen CC: Cross-sectional echocardiographic detection of aortic valve prolapse. *Am Heart J* (1980) **100**, 295-301.
  9. Stewart WJ, King ME, Gillam LD, Guyer DE and Weyman AE: Prevalence of aortic valve prolapse with bicuspid aortic valve and its relation to aortic regurgitation: a cross-sectional echocardiographic study. *Am J Cardiol* (1984) **54**, 1277-1282.
  10. Shapiro LM, Thwaites B, Westgate C and Donaldson R: Prevalence and clinical significance of aortic valve prolapse. *Br Heart J* (1985) **54**, 179-183.

Received May 24, 1988 ; accepted October 11, 1988