

Acta Medica Okayama

Volume 62, Issue 2

2008

Article 9

APRIL 2008

A case of gastrocolocutaneous fistula as a complication of percutaneous endoscopic gastrostomy

Daisuke Okutani*

Kazutoshi Kotani[†]

Shigeki Makihara[‡]

*Department of Surgery, National Hospital Organization Minami-Okayama Medical Center,

[†]Department of Surgery, National Hospital Organization Minami-Okayama Medical Center,

[‡]Department of Surgery, National Hospital Organization Minami-Okayama Medical Center,

A case of gastrocolocutaneous fistula as a complication of percutaneous endoscopic gastrostomy*

Daisuke Okutani, Kazutoshi Kotani, and Shigeki Makihara

Abstract

A rare complication of percutaneous endoscopic gastrostomy (PEG) is gastrocolocutaneous fistula which usually occurs after replacement of the PEG tube. As tube feeding is directly delivered to the transverse colon, patients typically present with a sudden onset of transient diarrhea within minutes after PEG tube feeding. A radiographic study using water-soluble contrast material via the PEG tube shows the tip of the tube in the transverse colon. We present here a patient who had this complication after PEG insertion. A PEG tube for enteral feeding was placed in a 27-year-old man with cerebral palsy and a severe scoliosis. After replacement of the PEG tube, he developed diarrhea after each PEG tube feeding. The diagnosis of gastrocolocutaneous fistula was made after injection of gastrografin from the PEG tube. Another gastrostomy tube was placed surgically and the fistula was then also excised. In conclusion, gastrocolocutaneous fistula must be considered as a complication of PEG tube placement when patients with a PEG tube develop a sudden onset of transient diarrhea immediately after PEG tube feeding.

KEYWORDS: gastrocolocutaneous fistula, percutaneous endoscopic gastrostomy

Case Report

A Case of Gastrocolocutaneous Fistula as a Complication of Percutaneous Endoscopic Gastrostomy

Daisuke Okutani*, Kazutoshi Kotani, and Shigeki Makihara

Department of Surgery, National Hospital Organization Minami-Okayama Medical Center, Hayashima-cho, Okayama 701-0304, Japan

A rare complication of percutaneous endoscopic gastrostomy (PEG) is gastrocolocutaneous fistula which usually occurs after replacement of the PEG tube. As tube feeding is directly delivered to the transverse colon, patients typically present with a sudden onset of transient diarrhea within minutes after PEG tube feeding. A radiographic study using water-soluble contrast material via the PEG tube shows the tip of the tube in the transverse colon. We present here a patient who had this complication after PEG insertion. A PEG tube for enteral feeding was placed in a 27-year-old man with cerebral palsy and a severe scoliosis. After replacement of the PEG tube, he developed diarrhea after each PEG tube feeding. The diagnosis of gastrocolocutaneous fistula was made after injection of gastrografin from the PEG tube. Another gastrostomy tube was placed surgically and the fistula was then also excised. In conclusion, gastrocolocutaneous fistula must be considered as a complication of PEG tube placement when patients with a PEG tube develop a sudden onset of transient diarrhea immediately after PEG tube feeding.

Key words: gastrocolocutaneous fistula, percutaneous endoscopic gastrostomy

Percutaneous endoscopic gastrostomy (PEG) has become a safe and effective technique for enteral feeding. However, gastrocolocutaneous fistula is a rare major complication of PEG. In the clinical setting, it usually manifests only after replacement of the PEG tube. As tube feeding is directly delivered to the transverse colon, the diagnosis can be confirmed by injection of barium or gastrografin through the PEG tube. Here, we report a case of this complication.

Case Report

A PEG tube for enteral feeding was placed in a 27-year-old man with cerebral severe scoliosis (Fig. 1). The tube was inserted in the stomach uneventfully. The patient had no difficulty with enteral tube feeding for the next few months until replacement of the PEG tube. A sudden onset of transient diarrhea then developed invariably occurring within minutes after each PEG tube feeding. Radiographic images with injection of gastrografin from the PEG tube showed the tip of the tube in the transverse colon with colonic filling of gastrografin (Fig. 2). No contrast material entered the peritoneal cavity. Laparotomy was performed to close the fistula and to replace the gastrostomy. The postoperative course was uneventful, and he had no

Received July 4, 2007; accepted November 19, 2007.

*Corresponding author. Phone:+81-86-482-1121; Fax:+81-86-482-3883
E-mail: oktn2002@yahoo.co.jp (D. Okutani)

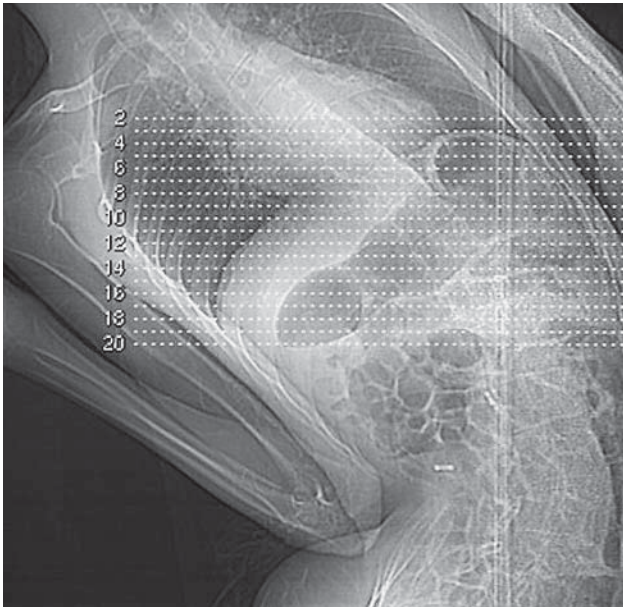


Fig. 1 Chest X-ray shows a severe spinal deformity due to scoliosis.

further difficulty with enteral feeding via the new gastrostomy tube.

Discussion

PEG was introduced in 1980 as an alternative to laparotomy for placement of a gastrostomy. It can be performed less invasively in 15 to 30 min, requires minimal, if any, sedation rather than general anesthesia, and is successful in over 95% of patients [1]. However, a recent literature review of PEG has mentioned an overall complication rate of 17% including gastrocolocutaneous fistula which usually manifests only after replacement of the PEG tube [2]. Khatak *et al.* reported a 2% to 3% incidence of gastrocolocutaneous fistula after a PEG insertion [3]. In our hospital, over a 7-year period (1999/1–2007/8), this complication rate was 0.76 % (1 of 131 procedures).

The most common indications for PEG are neurologic conditions associated with impaired swallowing.

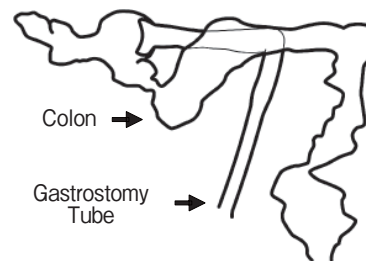
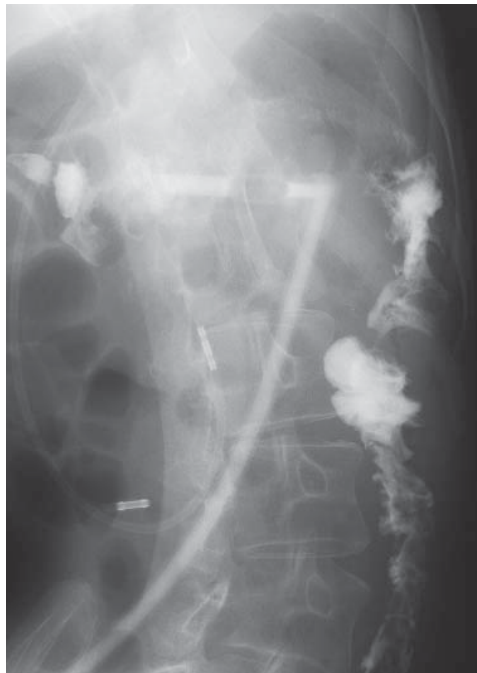

Fig. 2 Radiographic study with gastrografin shows the tip of the tube in lumen of transverse colon with colonic filling to descending colon.

These patients tend to have the abnormal posture and spinal deformity that undoubtedly contribute to abnormal position of the stomach, which may be responsible for the increased incidence of gastrocolocutaneous fistula. According to Patwardhan *et al.*, among 12 cases of gastrocolocutaneous fistula after PEG insertion, 10 patients suffered neurologic impairment [4]. Our patient had a severe spinal deformity due to scoliosis, which might account for this complication. So like patients with previous abdominal surgery, those who have a severe spinal deformity should be considered as a high risk group, and thorough preoperative examinations must be required. In our hospital, the decisive modality for the assessment of patients before PEG would be a CT examination in which the stomach is moderately inflated with air, which allows the inside of the stomach during the PEG procedure to be easily imagined [5].

In order to prevent this complication, another important factor should be considered during the PEG procedure. Croaker and Najmaldin have reported that too much inflation of the stomach before PEG insertion can cause anterior rotation of the greater curvature of the stomach, carrying the gastrocolic omentum and the transverse colon anterior to the stomach (Fig. 3) [6]. In this situation, the PEG could be placed in the stomach, passing through the transverse colon before entering the posterior wall of the stomach. As already mentioned above, in all 12 cases of gastrocolocutaneous fistula presented by Patwardhan, the posterior wall of the stomach was PEG's point of

entry [4].

Although a gastrocolocutaneous fistula may form at the time of PEG tube placement, patients usually remain asymptomatic until replacement of the new tube. Once the tube lodges in the transverse colon, patients typically present with a sudden onset of transient diarrhea within minutes after PEG tube feeding. If migration of a PEG tube into the transverse colon is suspected clinically, a radiographic study should be performed with water-soluble contrast material via the PEG tube. Since, in most cases, both tracts, *i.e.*, the gastro-colic and colo-cutaneous tract are mature at the time of this diagnosis, no associated peritonitis would occur. Therefore, the tube can be removed without any surgical treatment. If a new tube is required, another gastrostomy tube can be placed surgically, and, if necessary, a residual gastrocolocutaneous fistula can be excised at the time of surgery [7].

In conclusion, gastrocolocutaneous fistula must be considered as a complication of PEG tube placement when patients with PEG tube develop a sudden onset of transient diarrhea immediately after PEG tube feeding. To avoid this complication, patients in a high risk group have to undergo careful assessment before PEG. It would be better to exclude as PEG candidates those who have severe spinal deformity even when PEG insertion seems possible based on preoperative CT examination.

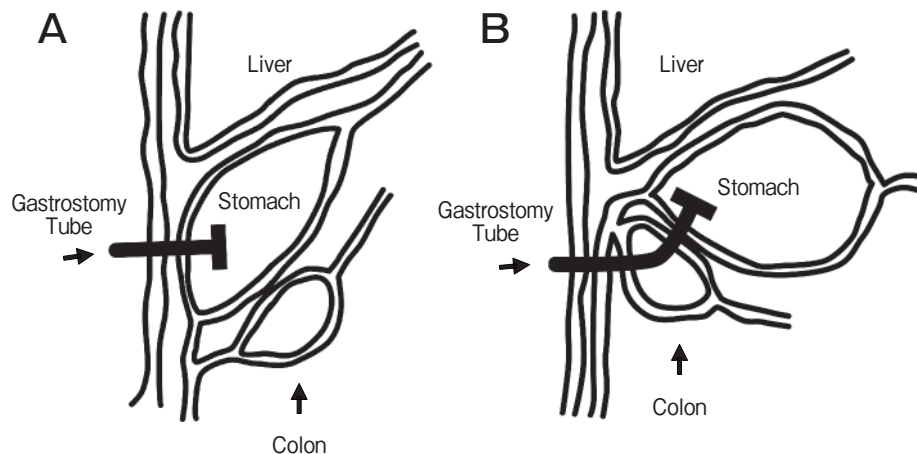


Fig. 3 A, A normal image of PEG insertion; B, A formation of gastrocolocutaneous fistula.

References

1. Huang SY, Levine US and Raper SE: Gastrocolic fistula with migration of feeding tube into transverse colon as a complication of percutaneous endoscopic gastrostomy. *AJR Am J Roentgenol* (2005) 184: S65-66.
2. Smyth GP, McGreal GT and McDeromott EWM: Delayed presentation of a great colcutaneous endoscopic gastrostomy. *Nutrition* (2003) 19: 905-906.
3. Khattak IU, Kimber C, Kiely EM and Spitz L: Percutaneous endoscopic gastrostomy in paediatric practice: complications and outcome. *J Pediatr Surg* (1998) 33: 67-72.
4. Patwardhan N, McHugh K, Drake D and Spitz L: Gastroenteric fistula complicating percutaneous endoscopic gastrostomy. *J Pediatr Surg* (2004) 39: 561-564.
5. Brown S, McHugh K, Ledermann S and Pierro A: CT findings in gastrocolic fistula following percutaneous endoscopic gastrostomy. *Pediatr Radiol* (2007) 37: 229-231.
6. Croaker GDH and Najmaldin AS: Laparoscopically assisted percutaneous endoscopic gastrostomy. *Pediatr Surg Int* (1997) 12: 130-131.
7. Nicholson FB, Korman MG and Richardson MA: Percutaneous endoscopic gastrostomy: a review of indications, complications and outcome. *J Gastroenterol Hepatol* (2000) 15: 21-25.