

# *Acta Medica Okayama*

---

*Volume 51, Issue 1*

1997

*Article 7*

FEBRUARY 1997

---

## Deformity of the proximal end of the femur following open reduction for developmental dislocation of the hip

Koichi Ikegami\*

Yoichi Nakatsuka†

Hirofumi Akazawa‡

Shigeru Mitani\*\*

Hajime Inoue††

\*Okayama University,

†Okayama University,

‡Okayama University,

\*\*Okayama University,

††Okayama University,

# Deformity of the proximal end of the femur following open reduction for developmental dislocation of the hip\*

Koichi Ikegami, Yoichi Nakatsuka, Hirofumi Akazawa, Shigeru Mitani, and Hajime Inoue

## Abstract

We studied deformity of the proximal end of the femur following open reduction using the wide exposure method for developmental dislocation of the hip. We reviewed radiographs of 22 children with unilateral dislocation of the hip who had undergone open reduction between one and three years of age. Ages at final examination ranged from 14 to 21 years. None of the patients in this study had undergone any additional surgery. Avascular necrosis of the femoral head was not observed in any patients. Radiographic measurements were observed when the children were 3, 6, 9, and 12 years old, and at the final examination. Coxa magna and valga were the factors associated with poor results. Coxa valga had occurred at 6 to 12 years of age, but rapidly improved thereafter. Throughout the course of treatment the epiphysis-femoral neck angle was within the normal range. The fusion of the epiphyseal growth plates on both sides occurred simultaneously. The coxa valga was due to valgus of the femoral neck, and not to valgus head tilt. These results suggest that, provided the mechanics of the joint have been properly corrected as in our operation, the biomechanics of the hip will improve until growth ceases, but that it may take more than ten years to attain normality.

**KEYWORDS:** developmental dislocation of the hip, open reduction, coxa valga

---

\*PMID: 9057934 [PubMed - indexed for MEDLINE]

Copyright (C) OKAYAMA UNIVERSITY MEDICAL SCHOOL

## Deformity of the Proximal End of the Femur Following Open Reduction for Developmental Dislocation of the Hip

Koichi IKEGAMI\*, Yoichi NAKATSUKA, Hirofumi AKAZAWA, Shigeru MITANI and Hajime INOUE

Department of Orthopaedic Surgery, Okayama University Medical School, Okayama 700, Japan

We studied deformity of the proximal end of the femur following open reduction using the wide exposure method for developmental dislocation of the hip. We reviewed radiographs of 22 children with unilateral dislocation of the hip who had undergone open reduction between one and three years of age. Ages at final examination ranged from 14 to 21 years. None of the patients in this study had undergone any additional surgery. Avascular necrosis of the femoral head was not observed in any patients. Radiographic measurements were observed when the children were 3, 6, 9, and 12 years old, and at the final examination. Coxa magna and valga were the factors associated with poor results. Coxa valga had occurred at 6 to 12 years of age, but rapidly improved thereafter. Throughout the course of treatment the epiphysis-femoral neck angle was within the normal range. The fusion of the epiphyseal growth plates on both sides occurred simultaneously. The coxa valga was due to valgus of the femoral neck, and not to valgus head tilt. These results suggest that, provided the mechanics of the joint have been properly corrected as in our operation, the biomechanics of the hip will improve until growth ceases, but that it may take more than ten years to attain normality.

**Key words:** developmental dislocation of the hip, open reduction, coxa valga

An extensive anterolateral approach for developmental dislocation of the hip joint (DDH), as reported by Akazawa *et al.* (1), has been adopted in Japan because of its excellent results. This approach to open reduction was developed in our department in 1973 by Tanabe. We have successfully induced sufficient con-

centric reduction of the femoral head in the acetabulum, by removing all obstacles preventing complete reduction. This open reduction provides excellent results compared to other approaches (2-5), with a lower incidence of avascular necrosis and without additional surgery. However, it was found that there were many cases of coxa magna and coxa valga after open reduction. Coxa magna and valga have been cited among the factors producing poor results, but there are few reports regarding the long-term results until closure of the proximal femoral physis.

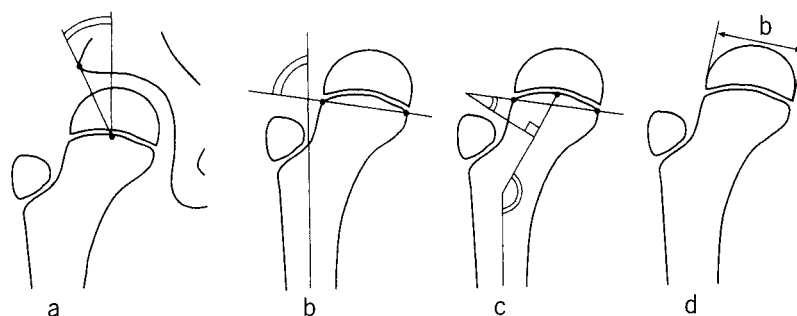
The results after open reduction for DDH are often evaluated using the center-edge (CE) angle, which is a measure of the relationship between the center of the femoral head and the edge of the acetabular roof. The development of the femoral head and neck strongly influences that of the acetabulum, and increasing deformity of the former will lead to delayed development of the latter. In the present study we examined the development of the femoral head and neck with age, and the influence of coxa magna and valga after open reduction.

### Subjects and Methods

Between 1974 and 1981, 39 operations were performed for unilateral DDH. Patients with DDH were selected so that the dislocated side could be compared with the contralateral side, the more normal side. All of the 39 patients revealed unilateral complete dislocation, as demonstrated on radiographs and arthrographs. There were no subluxations. Patients whose preoperative radiographs of the hip showed avascular necrosis were excluded. Twenty-three patients could be monitored until closure of the proximal femoral physis (follow-up rate, 59%). One of the patients, who underwent additional sur-

---

\* To whom correspondence should be addressed.



**Fig. 1** Radiographic measurements. (a) The CE angle of Wiberg. (b) The epiphysis-shaft angle of Jones. This angle describes the position of the epiphysis in space. (c) The epiphysis-femoral neck angle of Jäger and the neck-shaft angle. (d) The ratio of enlargement of the femoral head developed by Matsuo. The ratio of enlargement of the femoral head =  $b$  on the treated side  $\div$   $b$  on the normal side  $\times$  100.

gery with Salter's innominate osteotomy, was excluded. The records for the remaining 22 children (20 girls and 2 boys) with unilateral DDH were reviewed. The left hip was affected in 16 and the right in six. Preoperative conservative treatments had failed in 13 patients, and were not attempted in the others. All patients were surgically treated by an extensive anterolateral approach. The average age at the time of open reduction was 18 months (range: 12–32 months). The average age at the final examination was 17 years (range: 14–21 years).

Radiographic measurements were taken when the patients were 3, 6, 9, and 12 years old, and at the final examination. Anteroposterior radiographs were taken in a standard manner with the patellae facing forward. The CE angle of Wiberg (6) was measured as the intersection of the line parallel to the longitudinal body axis and the line connecting the center of the femoral head with the edge of the acetabular roof (Fig. 1a). The epiphyseal line of Jäger and Refier (7) was drawn by connecting the two points on the proximal metaphysis that are closest to the lowest and most lateral point and the most medial point of the capital femoral epiphysis. The epiphysis-shaft angle of Jones (8) was drawn between the axis of the femoral shaft and the epiphyseal line (Fig. 1b). The epiphysis-femoral neck angle of Jäger (7) was drawn between the epiphyseal line and the line perpendicular to the femoral neck axis. The neck-shaft angle was drawn between the femoral shaft axis and neck axis (Fig. 1c). This angle was a projected angle, because it was measured from only the radiograph in frontal view. The ratio of enlargement of the femoral head developed by Matsuo (9) was calculated by dividing the breadth of the head on the dislocated side by that on the normal side (Fig. 1d). Data analyses were performed using the Student's *t*-test or Welch's *t*-test.

**Surgical technique.** By Luck's anterior approach, the fascia lata and the tensor fasciae lata were transversely dissected, the gluteus medius and minimus were temporarily detached from the greater trochanter, and the fibrous adhesion was dissected allowing for thorough exposure of the joint capsule. Next the joint capsule was incised circumferentially near its insertion on the acetabular rim, and some tendons of short external rotators were detached from their insertions for dissection of the posterior adhesions. The psoas tendon was also detached from the lesser trochanter and later transferred to the anterolateral surface of the proximal femur, which was distal to the greater trochanter. The hypertrophied ligamentum capitis femoris and the fibro-fatty tissues in the acetabulum were removed. The transverse acetabular ligament was transected. The limbus was excised, if it posed a threat to successful concentric reduction. Adequate concentric reduction of the femoral head in the acetabulum was attained by means of removing all obstacles preventing complete reduction, including resection of redundant capsule. After surgery, a hip spica cast was applied to hold the hip joint in slight flexion, 30 degrees abduction, and full internal rotation. This was changed after two weeks, if removal of stitches was needed. The plaster was removed eight weeks after surgery.

## Results

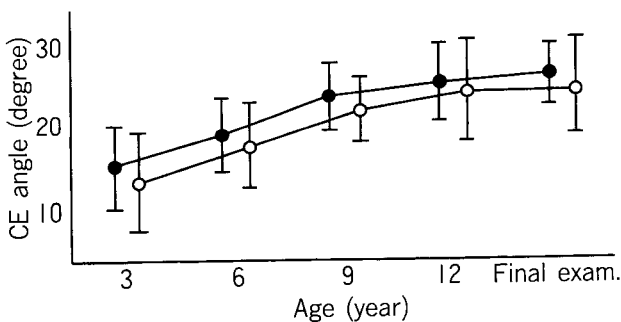
**The CE angle.** The CE angle evaluates the degree of lateral coverage of the femoral head and the concentricity of the hip joint. Normally, the angle increases gradually with growth of the hip joint. CE angles (in degrees) on the treated side were  $12.2 \pm 7.7$  at 3 years of age,  $18.0 \pm 4.4$  at 6 years,  $20.3 \pm 4.6$  at 9 years,

22.4 ± 6.8 at 12 years, and 24.0 ± 6.6 at the final examination. Angles on the normal side were 14.9 ± 5.8, 19.0 ± 5.7, 22.8 ± 4.7, 25.0 ± 4.9 and 26.0 ± 3.8, respectively. Severin (10) noted that angles under 20 degrees are associated with pathology after 14 years of age. Only four (18%) in 22 hips showed CE angles under 20 degrees at the final examination. The average CE angle on the treated side increased gradually after the open reduction. There was no significant difference between the CE angles on the two sides at any age. However, the average on the surgically treated side was consistently lower than that on the normal side (Fig. 2).

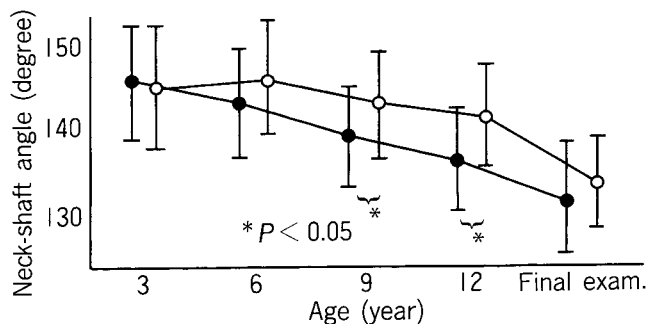
**The neck-shaft angle.** The neck-shaft angles on the treated side were 145 ± 9.1, 146 ± 6.9, 143 ± 7.1, 141 ± 6.9 and 133 ± 6.9 degrees, respectively, at 3, 6, 9, and 12 years of age and at the final examination, while angles on the normal side were 146 ± 7.5, 143 ± 8.0, 138 ± 6.2, 136 ± 6.6 and 132 ± 3.8 degrees, respectively. At 3 years of age, there was no significant difference between the angles on the two sides. The neck-shaft angle on the normal side gradually decreased to adulthood with growth of the hip joint, but the angle on the treated side decreased later, compared with that on the normal side. At 9 and 12 years, the difference between the angles of the two sides was significant. However, the angle on the treated side was rapidly improved after 12 years of age, and the angles on the two sides were not significantly different at the final examination (Fig. 3). There was a significant negative correlation between the neck-shaft angle and the final CE angle on the

treated side (Fig. 4).

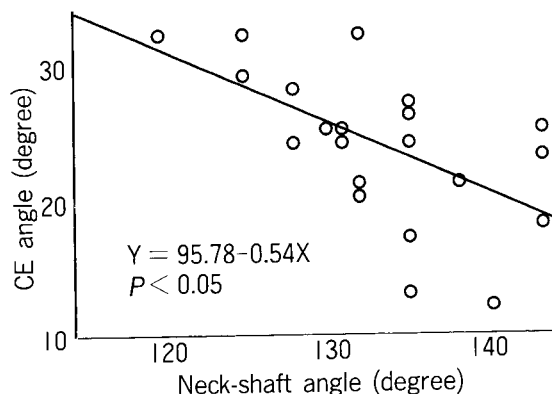
**The epiphysis-shaft angle.** The development of the femoral neck was investigated by Ogden *et al.* (11). He reported that the femoral neck begins to form by differential rapid growth of the central (medial) segment of the growth plate in normal development of the hip. This may cause the epiphysis-shaft angle to decrease progressively. We observed that the epiphysis-shaft angles on the treated side were 74.8 ± 5.0, 76.8 ± 7.4, 73.4 ± 9.2, 73.2 ± 9.3 degrees, respectively, at 3, 6, 9, and 12 years, while angles on the normal side were 75.9 ± 5.8, 72.6 ± 7.4, 68.0 ± 6.5 and 66.5 ± 7.0 degrees, respec-



**Fig. 2** Changes in the center-edge (CE) angle. The average CE angle on the treated side increased gradually after surgery. There was no significant difference between the CE angles on the two sides at each age. However, the average on the surgically treated side was consistently lower than that on the normal side. Only four (18%) of 22 hips at the final examination showed CE angle under 20 degrees. ●: Normal side, ○: Treated side.



**Fig. 3** Changes in the neck-shaft angle. The angle on the surgically treated side decreased later, compared with that on the normal side. At 9 and 12 years of age, the differences were significant. However, the angle on the treated side rapidly improved after 12 years. The angles on the two sides were not significantly different at the final examination. ●: Normal side, ○: Treated side.



**Fig. 4** Correlation between the neck-shaft angle and the CE angle. There was a significant negative correlation between the neck-shaft angle and the CE angle at the final examination ( $Y = 95.78 - 0.54X$ ,  $P < 0.05$ ). Coxa valga was one of the factors adversely affecting the long-term results. CE: See Fig. 1.

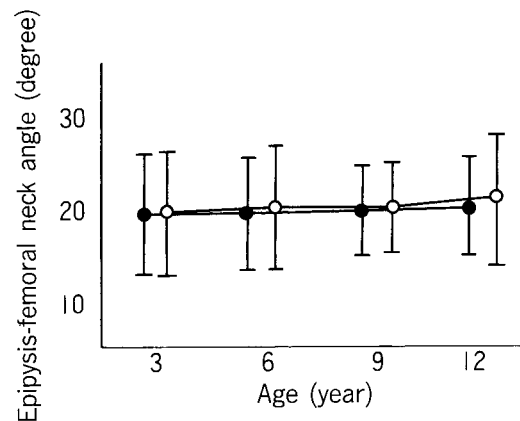
tively. The angle on the treated side was almost the same as that on the normal side at all ages. At 9 and 12 years of age, the differences between the angles on the two sides were significant (Fig. 5). At the final examination, this angle could not be measured because the epiphyseal line was closed.

**The epiphysis-femoral neck angle.** The epiphysis-femoral neck angle serves to characterize the degree of valgus head tilt, and normal values of the angle are approximately 20-30 degrees (7). The angles on the treated side were  $19.8 \pm 6.5$ ,  $20.8 \pm 7.2$ ,  $20.4 \pm 7.0$ ,  $22.2 \pm 7.1$  degrees, respectively, at 3, 6, 9, and 12 years, while angles on the normal side were  $19.9 \pm 6.0$ ,  $19.6 \pm 5.5$ ,  $20.0 \pm 4.3$  and  $20.5 \pm 5.4$  degrees, respectively. The angle on the treated side was almost constant and there was no significant difference between the angles on the two sides at each age (Fig. 6). Closure of the epiphyseal growth plate on the both sides had occurred simultaneously. For this reason, the growth plate itself was thought to have developed normally. The cause of coxa valga was valgus of the femoral neck, and not valgus head tilt.

**The ratio of enlargement.** At the final examination, the average of the ratio of enlargement was 107% (range: 100-121%). There was a significant negative correlation between the ratio of enlargement and the CE angle at the final examination (Fig. 7).

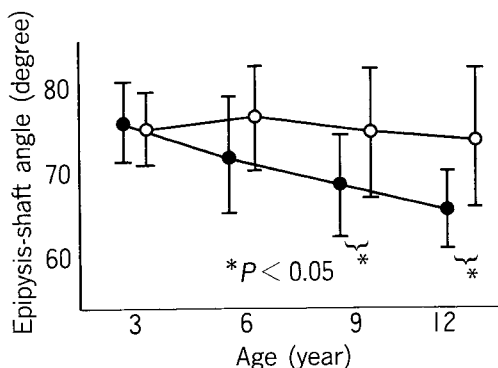
**Avascular necrosis and temporary irregular ossification.** Avascular necrosis as determined by Salter's criteria (12) was not observed postoperatively in any of the patients. Temporary irregular ossification

(which did not meet Salter's criteria for avascular necrosis) was found in five patients (23%) in this study. It became evident within a few years after open reduction. The average CE angles for these five hips and for the other 17 hips were  $20.2 \pm 5.9$  and  $24.5 \pm 6.7$  degrees, respectively, at the final examination, the neck-shaft angles at the final examination were  $133 \pm 8.3$  and  $133 \pm 6.2$  degrees, respectively, the epiphysis-shaft angles at 12 years of age were  $76.2 \pm 13.5$  and  $72.1 \pm 7.5$  degrees, respectively, and the epiphysis-femoral neck angles at 12



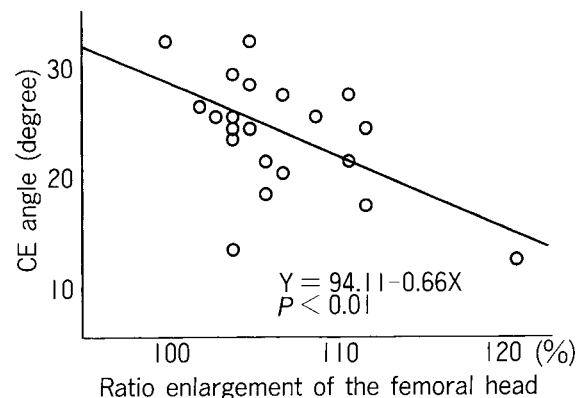
**Fig. 6** Changes in the epiphysis-femoral neck angle. The normal value of the angle was approximately 20-30 degrees. The angle on the treated side was almost the same as that on the normal side at each age. There was no significant difference between the angles on the two sides at each age. The cause of coxa valga was valgus of the neck, and not valgus head tilt.

●: Normal side, ○: Treated side.



**Fig. 5** Changes in the epiphysis-shaft angle. The angle on the treated side remained relatively constant, while that on the normal side decreased progressively. At 9 and 12 years of age, the differences were significant.

●: Normal side, ○: Treated side.



**Fig. 7** Ratio of enlargement of the femoral head and the CE angle. There was a significant negative correlation between the ratio of enlargement and the CE angle at the final examination ( $Y = 94.11 - 0.66X$ ,  $P < 0.01$ ). Coxa magna was one of the factors adversely affecting the long-term results. CE: See Fig. 1.

years of age were  $76.2 \pm 13.5$  and  $72.1 \pm 7.5$  degrees, respectively. There was no significant difference between any of these angles of the two groups. Temporary irregular ossification did not seem to be a factor seriously affecting the results.

## Discussion

In the patients in this study, coxa valga had developed at 3 to 12 years of age. However, the growth plate itself was thought to have developed normally, because the epiphysis-femoral neck angle was within the normal range and closure of the epiphyseal growth plate on both sides had occurred simultaneously. We think that coxa valga development during this period was caused by the periosteal deposition of the femoral neck (13), and not by the valgus head tilt (8).

Biomechanically, the growth and shape of the proximal femur are critically influenced by the static and muscular forces acting on the hip joint. Haike (14) reported that transposition of iliopsoas muscle did not influence the valgus deformity. In the patients we studied, the average neck-shaft angles on the two sides did not differ at the final examination, although in all patients transposition of the psoas tendon was performed on the treated side. Brandes (15) reported the occurrence of coxa valga following surgical resection of the greater trochanter. In our approach, temporarily diminished muscle power resulting from the surgical intervention of the gluteus maximus and minimus might have influenced the coxa valga.

It is especially noteworthy that coxa valga had occurred at 6 to 12 years of age, but rapidly improved in the comparison with the normal side after 12 years of age. Some reports indicate that when anteverted and valgus hips occurred, varus or derotation osteotomy was necessary to correct the faulty mechanics (2, 16). We think that the reason for the deterioration may be the lack of adequate concentric reduction at the initial operation. Tönnis (17) noted that the proximal femur responded to increased mechanical loads (usually bending stress) by a change in the angular relationship. And the change was achieved in the manner that was effective biomechanically. We are convinced that the hip will improve biomechanically into a normal hip joint, if it was provided that the mechanics of the joint have been properly corrected, as in our operation. But it may take more than ten years to attain this normality.

Gamble *et al.* (5) asserted that coxa magna definitely occurs after avascular necrosis, but most frequently in the absence of roentgenographic signs of avascular necrosis. O'Brien and Salter (18) suggested that coxa magna represents increased vascularity in response to synovitis of the hip joint induced by open reduction, whereas Imatani *et al.* (19) argued that it was due to overwidening of the acetabular capacity by excising the limbs. We suspect that the instability of the hip joint is another factor in coxa magna. Regardless of how widely exposed was the hip, our approach cannot be regarded as disadvantageous, for the reason that the rate of coxa magna is no higher compared with other approaches (5, 18).

Salter *et al.* (12) held that temporary irregular ossification of the femoral head represented accelerated ossification in response to the stimulus of reduction. Temporary irregular ossification was noted in five hips in our study. As these five hips showed no particular distinction as compared with the other 17 hips, abnormality of vascularity cannot be denied in any patients among the 17 patients studied. We think that there is a spectrum of changes which depend on the severity of ischemia of the femoral head and neck, the abnormality of vascularity representing one end of this spectrum and avascular necrosis the other.

## References

1. Akazawa H, Tanabe G and Miyake Y: A new open reduction treatment for congenital hip dislocation: Long-term follow-up of the extensive anterolateral approach. *Acta Med Okayama* (1990) **44**, 223-231.
2. Mau H, Dörr WM, Henkel L and Jutsche J: Open reduction of congenital dislocation of the hip by Ludloff's method. *J Bone Joint Surg* (1971) **53 A**, 1281-1288.
3. Sosna A and Rejhošec M: Ludloff's open reduction of the hip: Long-term results. *J Pediatr Orthop* (1992) **12**, 603-606.
4. Szepesi K, Biró B, Fazekas K and Szücs G: Preliminary results of early open reduction by an anterior approach for congenital dislocation of the hip. *J Pediatr Orthop* (1995) **B4**, 171-178.
5. Gamble JG, Mochizuki C, Bleck EE and Rinsky LA: Coxa magna following surgical treatment of congenital hip dislocation. *J Pediatr Orthop* (1985) **5**, 528-533.
6. Wiberg G: Studies on dysplastic acetabulum and congenital subluxation of the hip joint with special reference to the complication of osteoarthritis. *Acta Chir Scand* (1939) **83**, 28-38.
7. Jäger M and Refior HJ: Der Kopfepiphysenwinkel. *Orthop Prax* (1974) **10**, 32-36.
8. Jones DA: Subcapital coxa valga after varus osteotomy for congenital dislocation of the hip. *J Bone Joint Surg* (1977) **59-B**, 152-158.
9. Matsuo Y: The follow-up study of open reduction for congenital dislocation of the hip. *Cent Jpn J Orthop Traumat* (1976) **19**, 831-845 (in Japanese).
10. Severin E: Contribution to the knowledge of congenital dislocation of

- the hip joint. *Acta Chir Scand* (1941) **84**, 32-36.
11. Ogden JA: Changing patterns of proximal femoral vascularity. *J Bone Joint Surg* (1974) **56**-A, 941-950.
  12. Salter RB, Kostuik J and Dallas S: Avascular necrosis of the femoral head as a complication of treatment for congenital dislocation of the hip in young children. *Can J Surg* (1969) **12**, 4461.
  13. Papadopoulos JS and Hofmann A: Das periostale Wachstum, Hauptmittel zur funktionellen Anpassung des Schenkelhals-Schaft-Winkels. *Arch Orthop Unfall-Chir* (1972) **73**, 33-46.
  14. Haike HJ: Tierexperimentelle Untersuchungen zur Frage der Entstehung der Osteochondrose des Schenkelkopfes, der Coxa vara und valga, sowie der pathologischen Antetorsion des koxalen Femurendes. *Z Orthop* (1965) **100**, 416-439.
  15. Brandes M: Vorschlag zu einer physiologischen Behandlung der Coxa vara. *Arch Orthop Unfall-Chir* (1924) **22**, 409-417.
  16. Somerville EW: Results of treatment of 100 congenitally dislocated hips. *J Bone Joint Surg* (1967) **49**-B, 258-268.
  17. Tönnis D: *Congenital Dysplasia and Dislocation of the Hip in Children and Adults*, Springer-Verlag, Berlin, Heidelberg, New York, London Paris, Tokyo (1984) pp18-19.
  18. O'Brien T and Salter RB: Femoral head size in congenital dislocation of the hip. *J Pediatr Orthop* (1985) **5**, 299-301.
  19. Imatani J, Miyake Y, Nakatsuka Y, Akazawa H and Mitani S: Coxa magna after open reduction for developmental dislocation of the hip. *J Pediatr Orthop* (1995) **15**, 337-341.
- 

Received July 8, 1996; accepted October 8, 1996.