

Acta Medica Okayama

Volume 51, Issue 2

1997

Article 8

APRIL 1997

Endoscopic carpal tunnel pressure measurement: a reliable technique for complete release

Hiroyuki Hashizume*

Yoshifumi Nanba†

Yukio Shigeyama‡

Takahiko Hirooka**

Tadashi Yokoi††

Hajime Inoue‡‡

*Okayama University,

†Okayama University,

‡Okayama University,

**Okayama University,

††Okayama University,

‡‡Okayama University,

Endoscopic carpal tunnel pressure measurement: a reliable technique for complete release*

Hiroyuki Hashizume, Yoshifumi Nanba, Yukio Shigeyama, Takahiko Hirooka, Tadashi Yokoi, and Hajime Inoue

Abstract

Carpal tunnel syndrome is diagnosed by clinical symptoms, Tinel's sign, Phalen's test and electromyography. Carpal tunnel pressure measurement can also aid in the precise identification of excessive pressure sites that indicate locations for release. In this study, pressure measurements made during endoscopic carpal tunnel release at 5 points were significantly higher anywhere in the carpal tunnel than outside the tunnel and decreased markedly after release. We concluded that our measurement technique can improve the reliability of endoscopic carpal tunnel release by decreasing the likelihood of missing any nerve entrapment sites.

KEYWORDS: carpal tunnel syndrome, endoscopic carpal tunnel release, carpal tunnel pressure

*PMID: 9142348 [PubMed - indexed for MEDLINE]

Copyright (C) OKAYAMA UNIVERSITY MEDICAL SCHOOL

Endoscopic Carpal Tunnel Pressure Measurement: A Reliable Technique for Complete Release

Hiroyuki HASHIZUME*, Yoshifumi NANBA, Yukio SHIGEYAMA, Takahiko HIROOKA, Tadashi YOKOI and Hajime INOUE

Department of Orthopaedic Surgery, Okayama University Medical School Okayama 700, Japan

Carpal tunnel syndrome is diagnosed by clinical symptoms, Tinel's sign, Phalen's test and electromyography. Carpal tunnel pressure measurement can also aid in the precise identification of excessive pressure sites that indicate locations for release. In this study, pressure measurements made during endoscopic carpal tunnel release at 5 points were significantly higher anywhere in the carpal tunnel than outside the tunnel and decreased markedly after release. We concluded that our measurement technique can improve the reliability of endoscopic carpal tunnel release by decreasing the likelihood of missing any nerve entrapment sites.

Key words: carpal tunnel syndrome, endoscopic carpal tunnel release, carpal tunnel pressure

Carpal tunnel syndrome (CTS) has become a common disease, particularly among middle-aged women and in a growing number of men. The treatment for idiopathic CTS is mainly conservative in the early stages and surgical for advanced cases. Endoscopic carpal tunnel release (ECTR), which is much less invasive, has begun to replace open carpal tunnel release as the preferred therapeutic technique (1-4).

From September 1993, we started using Okutsu's ECTR method (1) with generally good results. However, after 2 incomplete releases early in our series of 20 cases, we included endoscopic carpal tunnel pressure measurements in the procedure. The purpose of this pressure measurement system is to more precisely identify sites of excessive pressure where release may be required. In this study, we compared the reliability of the carpal tunnel pressure measurements of our new method with Okutsu's original continuous infusion technique (5) used before and

after surgery.

Subjects and Methods

The diagnosis of CTS was based on the accepted symptoms and electromyographic results. All patients had a distal motor latency of more than 5.2 msec. Clinical results were evaluated 3 months after ECTR according to Kelly's criteria (6).

Forty-six patients (52 hands) with idiopathic CTS underwent ECTR between October 1993 and December 1995. The 5 men (5 hands) and 41 women (47 hands) were aged from 19 years to 78 years (average 57.7 years). These patients were divided into two groups:

Group 1. Carpal tunnel pressure measurement was performed only by Okutsu's method (20 cases, 24 hands). Group 2. Measurement was carried out both by Okutsu's method and by our endoscopically guided carpal tunnel pressure measurement method (26 cases, 28 hands) (Fig. 1).

ECTR was conducted in all cases according to Okutsu's method without a tourniquet, under local anesthesia. The pressure was measured in the carpal tunnel before and after ECTR by the continuous infusion technique after the injection of 10 ml of 1% lidocaine (5, 7).

Pressure was measured with an A-line blood pressure measurement system (HP Component Monitoring System, Hewlett-Packard GmbH; and Blood Pressure Monitoring Kit, Model DT-4812, Ohmeda Device Products, Madison WI, USA). An 18-gauge, 7 cm long catheter with a smooth tip was used (Fig. 2). Measurements were made 30 sec after insertion to allow the tunnel pressure to stabilize. To exclude the influence of the injected lidocaine, the measurement was made 5 min after local

* To whom correspondence should be addressed.

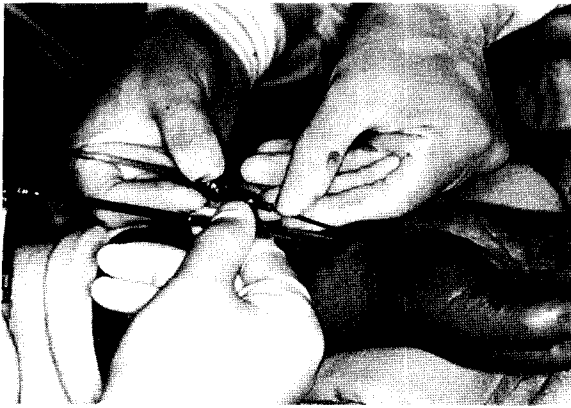


Fig. 1 Endoscopically guided probe insertion.

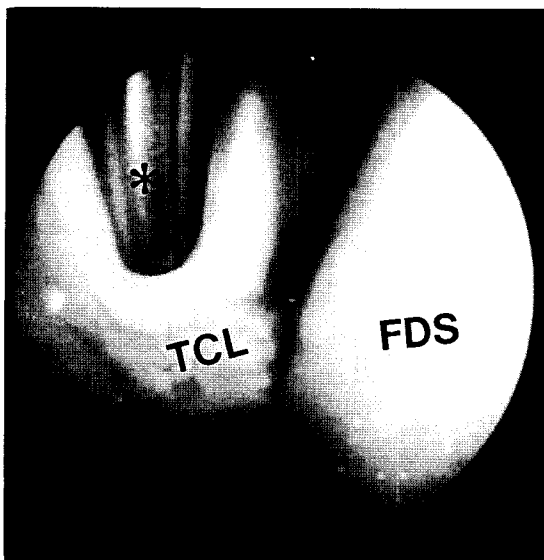


Fig. 2 Endoscopic view of non-contact pressure measurement by the continuous infusing technique. The tip of the probe inserted under the transverse carpal ligament (TCL) is shown. *: Probe making non-contact pressure measurement; FDS: Flexor digitorum superficialis.

injection. In our method, a continuous infusion of saline solution flows through the tip of the 18-gauge catheter which is inserted in to the carpal tunnel to measure and record the pressure. After release, the pressure is measured again.

Group 1. Non-contact pressure was measured at 4 different positions of the wrist and hand (resting position, active grip, maximum passive wrist flexion,

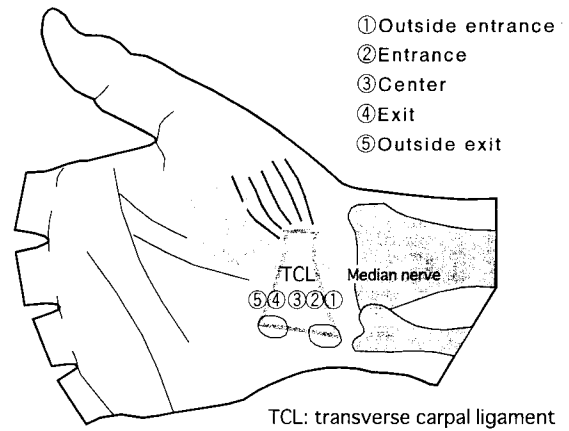


Fig. 3 Endoscopically guided non-contact pressure measurement points in the carpal tunnel.

maximum passive wrist extension). After release, we confirmed complete release according to Okutsu's 5 criteria (5, 8): 1. endoscopic visual confirmation of the cut surface of the ligament; 2. descent of fatty tissue into the tunnel visually confirmed with an endoscope; 3. light from the tip of the endoscope uniformly visible under the skin from the palm to the point of insertion; 4. the blunt probe is palpable just under the skin from the palm to the point of insertion; and 5. marked decrease of abnormally high pressure after ECTR.

Group 2. The tip of the catheter (Fig. 2) was endoscopically guided to 5 different points of the carpal tunnel for non-contact pressure measurements: outside entrance, entrance, center, exit and outside exit (Fig. 3). Pressure was also measured in Okutsu's 4 positions as in Group 1. After release, contact pressure measurements were made at all areas of residual high pressure.

The pressure measurements were statistically analyzed with the paired *t*-test.

Results

The clinical results of all 52 patients were evaluated 3 months after ECTR and were excellent in 40 cases, good in eight, fair in two, and poor in two. In two of the fair cases, we had used Okutsu's method only, and the completeness of the transverse carpal ligament release was doubtful. The chief complaint was not completely resolved, and a second ECTR confirmed incomplete release. In one of the poor cases, the patient had marked

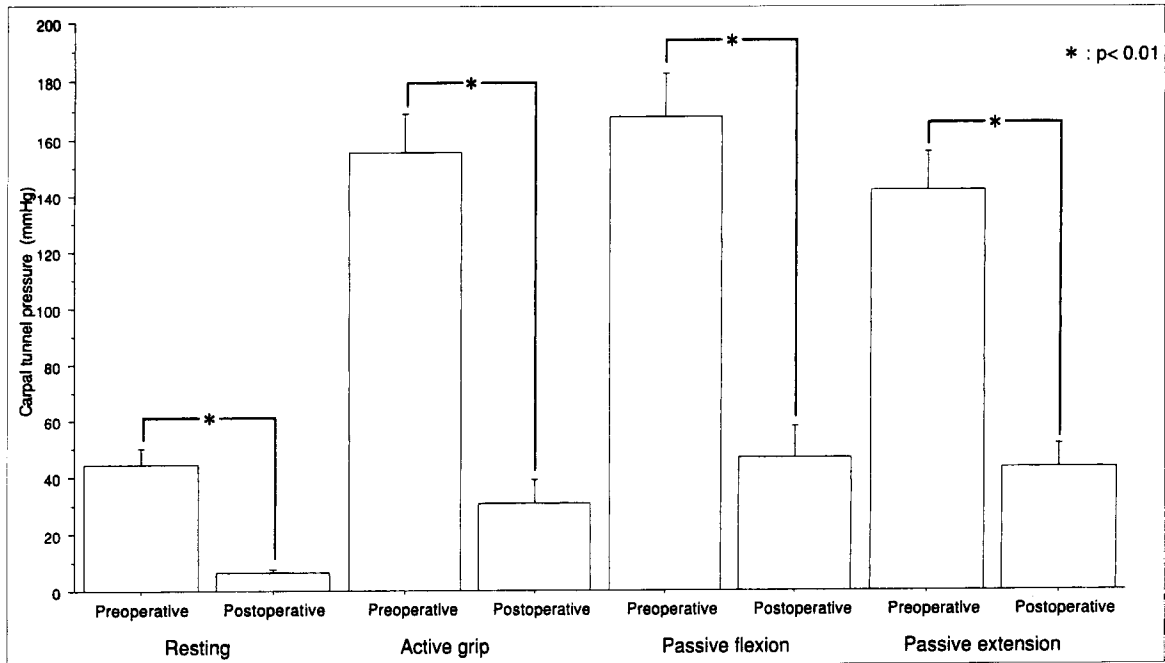


Fig. 4 Carpal tunnel pressure measurements in 4 wrist and hand positions. Columns indicate mean and bars indicate + 1 SD.

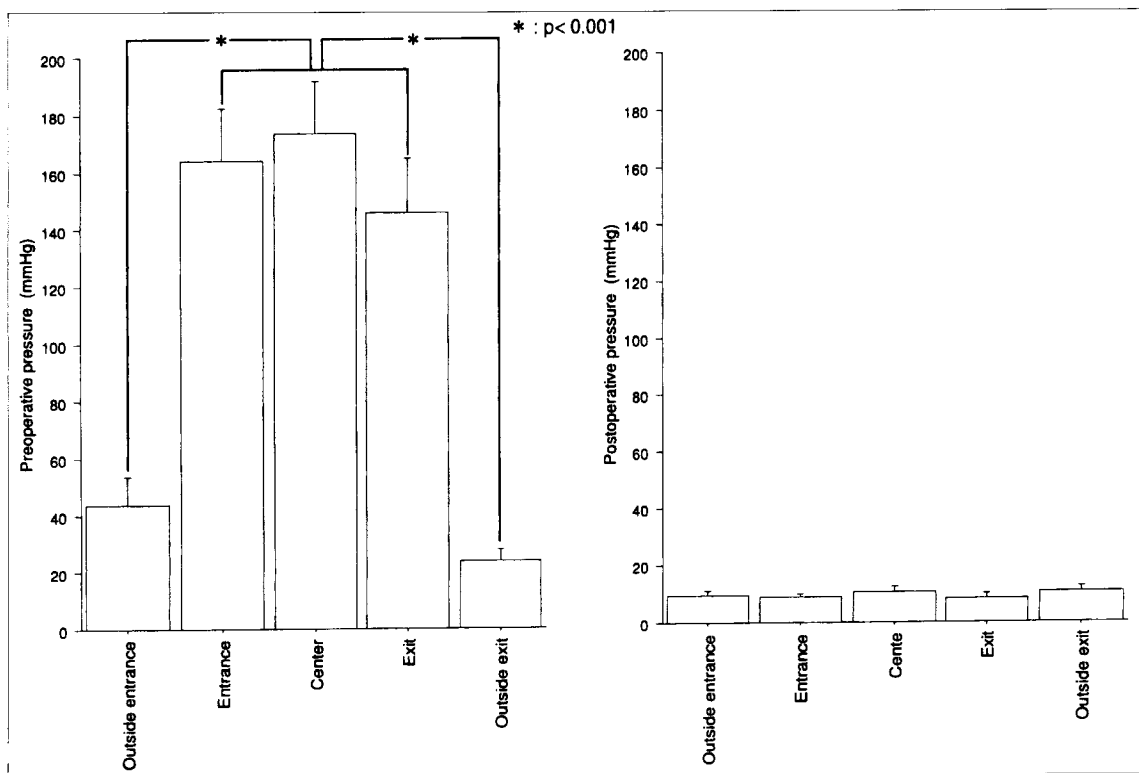


Fig. 5 Endoscopic carpal tunnel pressure measurement at 5 points. Columns indicate mean and bars indicate + 1 SD.

thenar muscle atrophy and, in the other, the patient had double crush syndrome with neck problems. All of these fair and poor cases in Group 1 were among our early cases.

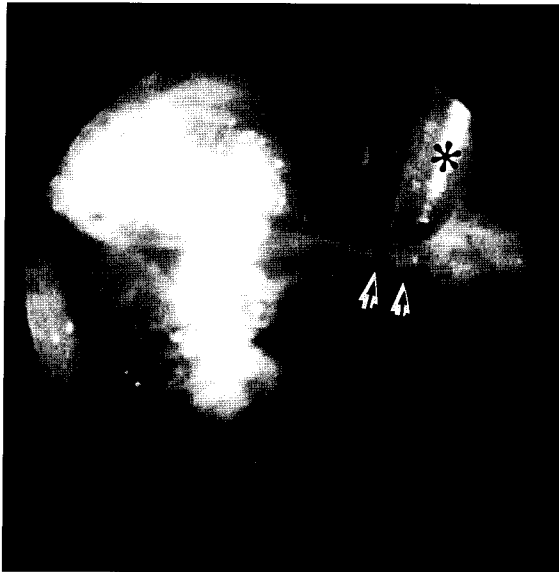

Fig. 6 Endoscopic view of Case 1. Remaining fibrous band creating high pressure is indicated by black and white arrows. *: Pressure probe making non-contact pressure measurement under the fibrous band.

The results of our pressure measurement using a continuous infusion technique are shown in Fig. 4. In both groups, the mean of the pressures measured in the 4 positions was lower after surgery. The preoperative and postoperative pressures in Group 2 at 5 points are shown in Fig. 5. Carpal tunnel pressure rose steeply at the entrance, reached a maximum at the center, and decreased after the exit.

The measurements before ECTR in 4 different positions (resting position, active grip, maximum passive wrist flexion, maximum passive wrist extension), and at 5 points (outside entrance, entrance, center, exit, outside exit) were significantly lower after ECTR ($P < 0.01$). The pressures in the carpal tunnel (entrance, center, exit) were significantly higher than outside the tunnel (outside entrance, outside exit) ($P < 0.001$). In our study, it would appear that the threshold pressure indicating complete release is 10.3 ± 6.3 mmHg.

Typical cases in our series are presented below:

Case 1. A 78-year-old woman. We released the transverse ligament endoscopically using Okutsu's method, and confirmed complete release using Okutsu's criteria. The pressure in the carpal tunnel without endoscope decreased markedly after ECTR in 4 different positions; however, the pressure in the tunnel was still high at the entrance (47 mmHg), and at the center (90 mmHg). We

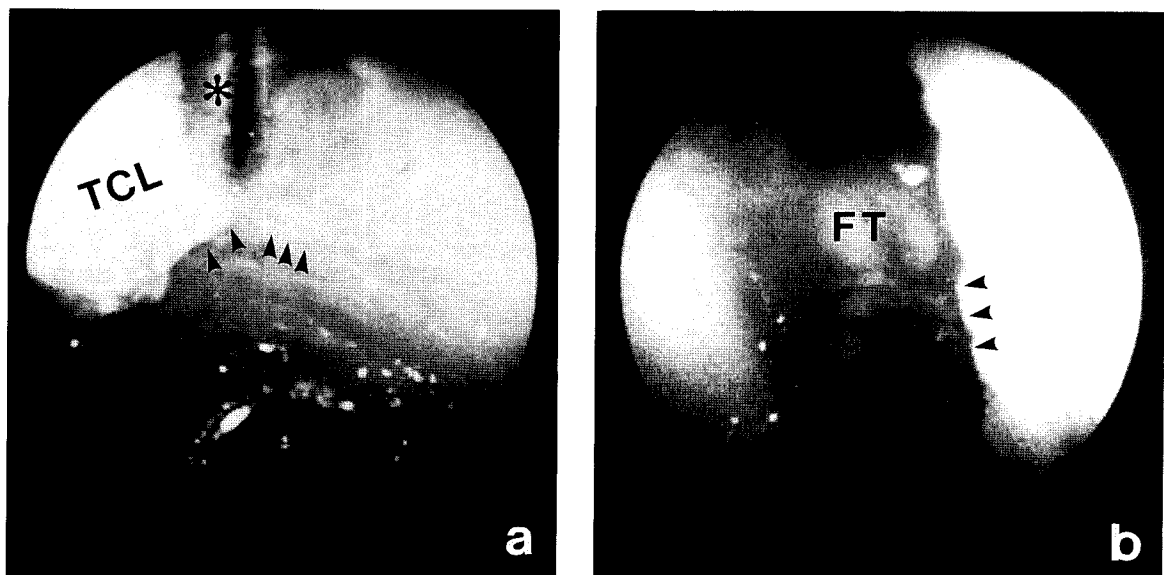


Fig. 7 Endoscopic view of Case 2. a) Partially intact distal edge of the transverse carpal ligament (TCL) is indicated by black arrows. *: Pressure probe making non-contact pressure measurement under the intact edge. b) After complete release, fatty tissue (FT) becomes visible beside the sharp cut edge of the ligament (black arrows).

carefully re-examined these areas with the probe and found that some of the fibrous bands remained at the exit (185 mmHg) (Fig. 6). We cut the bands completely, and the pressures at the entrance, center and exit fell to 9, 19 and 12 mmHg, respectively. The clinical results were excellent.

Case 2. A 47-year-old woman. We released the transverse ligament endoscopically and confirmed complete release according to Okutsu's criteria. Because the pressure in the tunnel was still high at the exit (76 mmHg), we carefully re-examined the area with the probe and found that the distal edge was incompletely released (Fig. 7a). After severing the edge completely, descent of the subcutaneous fatty tissue was observed (Fig. 7b), and the pressure at the area decreased to 12 mmHg. The clinical results were also excellent in this case.

Discussion

Pressure measurement in the carpal tunnel was first reported by Tanzer (9), who measured the pressure with a #14 Foley catheter after the carpal ligament was exposed (6 abnormal cases and 6 normal cases). Gelberman *et al.* (10) examined the pressure in the carpal tunnel with a Wick catheter (15 CTS cases and 12 normal control cases) and reported that the pressure in control subjects with the wrist in a neutral position was 2.5 mmHg. We modeled our procedure on some reports which used a continuous infusion technique for measuring the pressure (5, 11). Except for Tanzer (9), all investigators measured the pressure without visual control.

While there are several complications of ECTR (12-14), incomplete release of the transverse ligament is one of the most common surgical complications (11, 15, 16). We found Okutsu's 5 criteria for complete endoscopic release to be useful. However, we desired more precise visual control of the placement of the catheter and the points for measurement.

The fifth of Okutsu's 5 indicators for complete release became unreliable under the following condition: when some areas had not been completely released and the top of the catheter was under the released area, the decreased pressure was measured and the adjacent high pressure was apt to be missed. Under this condition, we could have mistakenly surmised that the release was complete. Cases 1 and 2 were examples. Small fibrous bands, or the distal edge of the transverse carpal ligament, are apt to be incompletely released when visibility is poor, espe-

cially when there is marked proliferation of the synovium and bleeding occurs after partial resection of the ligament. Carpal tunnel pressure measured by Okutsu's method significantly decreased after ECTR, but two incompletely released cases remained. This indicates that Okutsu's method is still not ideal under some circumstances.

Continuous infusion endoscopic pressure measurement can be used to accurately locate the locus of high pressure. If the pressure is extremely high under the fibrous bands of the distal edge (which is perhaps the palmar fascia or the fascia of the forearm muscle), we think that the release of these tissues is necessary. We conclude that the area at which pressure is excessively high indicates the release area. We found that pressure measurement with the endoscope is a much more objective and reliable indicator for complete release during ECTR.

Acknowledgements. We sincerely appreciate Dr. Shouhei Kira's (Department of Public Health, Okayama University Medical School) statistical analysis of this study.

References

1. Okutsu I, Ninomiya S, Natsuyama M, Takatori Y, Inanami H, Kuroshima N and Hiraki S: Subcutaneous operation and examination under universal endoscope. *J Jpn Orthop Assoc* (1987) **61**, 491-498 (in Japanese with English abstract).
2. Futami T, Otomo M, Wakabayashi N, Kobayashi A and Kubodera O: Operative treatment with arthroscope for carpal tunnel syndrome. *J Jpn Soc Surg Hand* (1988) **5**, 121-124 (in Japanese with English abstract).
3. Chow JLY: Endoscopic release of the carpal tunnel syndrome. *Arthroscopy* (1989) **5**, 19-24.
4. Agee JM, McCarroll JHR, Tortosa RD, Berry DA, Szabo RM and Peimer CA: Endoscopic release of the carpal tunnel: A randomized prospective multicenter study. *J Hand Surg* (1992) **17A**, 987-995.
5. Okutsu I, Ninomiya S, Hamanaka I, Kuroshima N and Inanami H: Measurement of pressure in the carpal canal and endoscopic management of carpal tunnel syndrome. *J Bone Jt Surg Am Vol* (1989) **71**, 679-683.
6. Kelly CP, Pulisteti D and Jamieson AM: Early experience with endoscopic carpal tunnel release. *J Hand Surg* (1994) **19B**, 18-21.
7. Werner CO, Elmqvist D and Ohlin P: Pressure and nerve lesion in the carpal tunnel. *Acta Orthop Scand* (1983) **54**, 312-316.
8. Okutsu I, Ninomiya S, Takatori Y, Hamanaka I, Genba K, Ugawa Y, Schonholtz GJ and Okumura Y: Results of endoscopic management of carpal tunnel syndrome. *Orthop Rev* (1993) **22**, 81-87.
9. Tanzer RC: The carpal tunnel syndrome: A Clinical and anatomical study. *J Bone Jt Surg Am Vol* (1959) **41**, 626-634.
10. Gelberman RH, Hergenroeder PT, Hargens AR, Lundborg GN and Akeson WH: The carpal tunnel syndrome: A study of carpal canal pressures. *J Bone Jt Surg Am Vol* (1981) **63**, 380-383.
11. Sakamoto T, Yanase Y, Ishii M, Ishida F and Kurihara Y: Experience of Okutsu-type endoscopic management of carpal tunnel syndrome. *Cent Jpn J Orthop Surg & Traumatol* (1993) **36**, 1473-1474 (in Japanese).

12. MacDonald RI, Lichtman DM, Hanlon JJ and Wilson JN: Complications of surgical release for carpal tunnel syndrome. *J Hand Surg* (1978) **3**, 70-76.
13. Brown RA, Gelberman RH, Seiler JG, Abrahamsson SO, Weiland AJ, Urbaniak JR, Schoenfeld DA and Furcolo D: Carpal tunnel release: A prospective, randomized assessment of open and endoscopic methods. *J Bone Jt Surg Am Vol* (1993) **75**, 1265-1275.
14. Shinya K, Lanzetta M and Conolly WB: Risk and complications in endoscopic carpal tunnel release. *J Hand Surg* (1995) **20B**, 222-227.
15. Murphy RX, Jennings JF and Wukich DK: Major neurovascular complications of endoscopic carpal tunnel release. *J Hand Surg* (1994) **19A**, 114-118.
16. Cobb TK and Cooney WP: Significance of incomplete release of the distal portion of the flexor retinaculum: Implications for endoscopic carpal tunnel surgery. *J Hand Surg* (1994) **19B**, 283-285.

Received November 12, 1996; accepted February 13, 1997.