

# *Acta Medica Okayama*

---

*Volume 36, Issue 2*

1982

*Article 8*

APRIL 1982

---

## Percutaneous transhepatic portal catheterization-modification of Chiba method and portal vein pressure in liver diseases.

Toshio Ito, *Okayama University*  
Tatsuya Itoshima, *Okayama University*  
Shuzo Kiyotoshi, *Okayama University*  
Kenji Kawaguchi, *Okayama University*  
Hiromichi Ogawa, *Okayama University*  
Masahiro Kitadai, *Okayama University*  
Shuzo Hattori, *Okayama University*  
Toshihiro Maruyama, *Okayama University*  
Jun Tomoda, *Okayama University*  
Shigeru Morichika, *Okayama University*  
Fumio Munetomo, *Mihara Red Cross Hospital*  
Hideo Nagashima, *Okayama University*

# Percutaneous transhepatic portal catheterization-modification of Chiba method and portal vein pressure in liver diseases.\*

Toshio Ito, Tatsuya Itoshima, Shuzo Kiyotoshi, Kenji Kawaguchi, Hiromichi Ogawa, Masahiro Kitadai, Shuzo Hattori, Toshihiro Maruyama, Jun Tomoda, Shigeru Morichika, Fumio Munetomo, and Hideo Nagashima

## Abstract

Percutaneous transhepatic portal catheterization was performed in 68 cases of liver diseases in the 2 year period from 1978 to 1980. The Chiba University method was modified. Portal vein catheterization was successful in 61 cases (90%). Selective splenic vein catheterization was successful in 55 of the 61 cases (90%) and selective superior mesenteric vein catheterization in 59 cases (97%). The liver was punctured an average of 4.6 times in order to successfully insert the catheter into the main portal vein, and the number of punctures was less than 10 in 57 of the 61 cases (93%). The portal vein pressure was 310 $\pm$ 67 mm H<sub>2</sub>O in idiopathic portal hypertension (8 cases), 290 $\pm$ 83 in liver cirrhosis (33 cases), 193 $\pm$ 71 in chronic hepatitis (7 cases) and 166 $\pm$ 50 in fatty liver (4 cases). Portal vein pressure rose from 205 $\pm$ 75 to 380 $\pm$ 55 mm H<sub>2</sub>O in 11 cases after forced Valsalva maneuver. No major complications were encountered.

**KEYWORDS:** percutaneous transhepatic portal catheterization(PTP), portal vein pressure, portal hypertension, forced Valsalva maneuver

---

\*PMID: 7136852 [PubMed - indexed for MEDLINE]

Copyright (C) OKAYAMA UNIVERSITY MEDICAL SCHOOL

Acta Med. Okayama 36, (2), 147—156 (1982)

## PERCUTANEOUS TRANSHEPATIC PORTAL CATHETERIZATION-MODIFICATION OF CHIBA METHOD AND PORTAL VEIN PRESSURE IN LIVER DISEASES

Toshio ITO, Tatsuya ITOSHIMA, Shozo KIYOTOSHI, Kenji KAWAGUCHI  
Hiromichi OGAWA, Masahiro KITADAI, Shuzo HATTORI  
Toshihiro MARUYAMA, Jun TOMODA, Shigeru MORICHIKA  
\*Fumio MUNETOMO and Hideo NAGASHIMA

*First Department of Internal Medicine, Okayama University Medical School,  
Okayama 700, Japan; and \*Mihara Red Cross Hospital, Mihara 723, Japan*

*Received October 20, 1981*

*Abstract.* Percutaneous transhepatic portal catheterization was performed in 68 cases of liver diseases in the 2 year period from 1978 to 1980. The Chiba University method was modified. Portal vein catheterization was successful in 61 cases (90 %). Selective splenic vein catheterization was successful in 55 of the 61 cases (90 %) and selective superior mesenteric vein catheterization in 59 cases (97 %). The liver was punctured an average of 4.6 times in order to successfully insert the catheter into the main portal vein, and the number of punctures was less than 10 in 57 of the 61 cases (93 %). The portal vein pressure was  $310 \pm 67$  mm H<sub>2</sub>O in idiopathic portal hypertension (8 cases),  $290 \pm 83$  in liver cirrhosis (33 cases),  $193 \pm 71$  in chronic hepatitis (7 cases) and  $166 \pm 50$  in fatty liver (4 cases). Portal vein pressure rose from  $205 \pm 75$  to  $380 \pm 55$  mm H<sub>2</sub>O in 11 cases after forced Valsalva maneuver. No major complications were encountered.

*Key words :* percutaneous transhepatic portal catheterization (PTP), portal vein pressure, portal hypertension, forced Valsalva maneuver.

Percutaneous transhepatic portal vein puncture was first reported by Bierman (1) in 1955. Reynolds *et al* (2) showed in 1970 that the portal vein pressure measured transhepatically was almost equivalent to the wedge hepatic vein pressure. Clinical use of percutaneous transhepatic portal catheterization (PTP) was first described by Lunderquist and Vang (3, 4) in 1970. Since then, this technique has proved to be a simple and safe method with few complication (5-8) and is used widely to localize gastrointestinal hormone-producing tumors (9-17) and to control gastroesophageal variceal bleeding (18-43). The present study describes our experience with PTP in 68 cases, modification of the PTP technique, and demonstration of marked elevation of the portal pressure after the Valsalva maneuver.

### MATERIALS AND METHODS

*Subjects.* Sixty-eight patients with liver diseases were submitted to PTP in the 2 year

period from December 1978 to November 1980. Their diagnoses are shown in Table 1. Sixty-six patients were diagnosed histologically by liver biopsy under the peritoneoscope or at laparotomy, and 2 patients were diagnosed clinically.

*Methods.* A PTC needle (0.7 mm in diameter, 15 cm in length; the so-called Chiba needle, Top Co., Tokyo) was introduced into the liver through an intercostal space between the 6th and 9th space in the right midaxillary line with the patients in the supine position and under local anesthesia. With breath-holding in shallow aspiration, the needle was advanced toward the liver hilum, which was identified 1/3 distance from the gas shadow in the duodenal bulb to the convex of the right diaphragm and 3 cm from the right side of the vertebra (Fig. 1-1). The needle was stopped at the liver hilum. Then, a 10 ml syringe filled with contrast medium (60.2 % to 82.3 % metrizoic acid, Isopaque, Torii & Co., Tokyo) was connected to the needle. The needle was withdrawn slowly until blood was easily aspirated

TABLE 1. PATIENTS SUBMITTED TO PTP AND/OR PTO

Diseases	No. of patients
Liver cirrhosis (LC)	37 (3)
Idiopathic portal hypertension (IPH)	8 (3)
Idiopathic portal hypertension (IPH) (Post splenectomy)	2 (2)
Chronic hepatitis (CH)	7
Fatty liver (FL)	5
Other liver diseases (OLD)	7
Hematological diseases (HD)	2
Total	68 (8)

PTP; percutaneous transhepatic portal catheterization, PTO; percutaneous transhepatic obliteration of the vein, ( ) ; patients submitted to PTO.

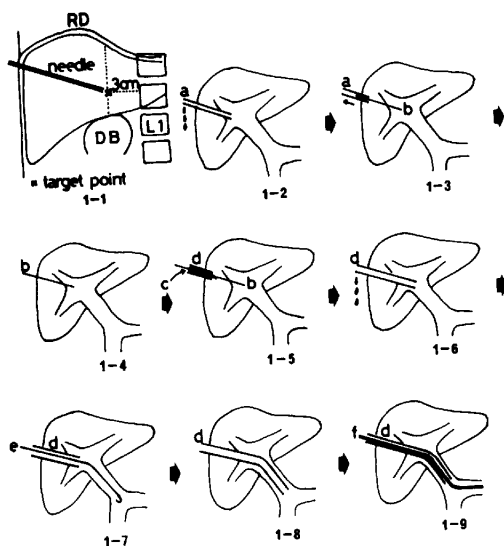


Fig. 1. Procedures of PTP (see text). RD; right diaphragm, DB; duodenal bulb, a; PTC needle, b; stylet, c; PTP needle, d; teflon catheter, e; guide wire, f; polyethylene catheter.

(Fig. 1-2). If blood was not easily aspirated during withdrawal of the needle, the needle was removed completely from the liver, and repuncture was attempted from the same puncture site in another direction near the liver hilum. If blood was easily aspirated, a little amount of contrast medium was injected to ascertain if the needle tip was located in a portal branch suitable for insertion of a catheter. Then, a metallic stylet (0.4 mm in diameter, 50 cm in length) was inserted through the PTC needle and the needle was withdrawn (Figs. 1-3, 1-4). A PTP teflon catheter (outer catheter, 2.0 to 2.6 mm in diameter) with an inner needle (1.3 to 1.8 mm in diameter, 30 cm in length, Hakko Shoji Co., Tokyo) was introduced using the inserted stylet as a guide (Fig. 1-5). The PTP needle and the stylet were withdrawn leaving the catheter (Fig. 1-6), through which a flexible J-shaped guide wire (0.70 to 0.87 mm in diameter; Cook Inc., Bloomington, Indiana) was inserted into the main portal vein (Fig. 1-7). Then, the catheter was advanced to the portal vein with the guide wire (Fig. 1-8). After withdrawal of the guide wire, a polyethylene catheter (inner catheter; 1.0 to 1.7 mm in diameter, 50 to 60 cm in length, Cook Inc.) was inserted into the teflon catheter (Fig. 1-9). Selective catheterization of the splenic vein, superior mesenteric vein, gastric coronary vein or short gastric vein was performed by the aid of the guide wire.

The portal vein pressure was measured at the main portal vein (PV), splenic vein (SPV) and superior mesenteric vein (SMV) with a water manometer setting the zero point 10 cm above the table top. The catheter was placed within the main portal vein, and the tip was kept free. Portal vein pressure elevation was recorded when the patient was ordered to say his name, age and address, to have 10 coughs, and to perform a forced Valsalva maneuver. Portography was performed 2 times keeping the catheter in the SPV and SMV. After the catheter tip was confirmed as not being wedged, 40 ml of the contrast medium was injected at the rate of 10 ml per second. Twelve films were exposed per second and 3 films were taken one every other second.

After portography, the catheter was withdrawn to a liver parenchymal portion, 2-3 cm from the liver capsule. There, small pieces of absorbable gelatin foam (Spongel, Yamano-uchi Pharm. Co., Tokyo) soaked in contrast medium were inserted into the punctured canal through the catheter. The catheter was withdrawn after confirmation of hemostasis.

## RESULTS

Main portal vein catheterization was successful in 61 of 68 cases (90 %) and unsuccessful in 7 cases (Table 2). Five cases of failure were due to poor technique in the early period of this study, 2 cases of failure were due to portal vein thrombosis confirmed by celiac arteriography and intraoperative portography. Both SPV and SMV catheterization were successful in 53 of 61 cases (87 %). SPV catheterization was unsuccessful in 6 cases; 2 cases of splenic vein thrombosis, 2 cases of post splenectomy, and 2 early cases. SMV catheterization was unsuccessful in 2 early cases. Selective catheterization of the gastric coronary vein or the short gastric vein was attempted in a few cases, and the catheterization was easily performed. Main portal vein catheterization was successful after an average of 4.6 liver punctures in 61 cases and after only one puncture in 12 cases (20 %). The number of puncture attempts was less than 10 in 57 of 61 cases (93 %). In 4 of 7 unsuccessful cases, the average was 16.4 punctures.

TABLE 2. SUCCESS RATES OF PTP, SPV AND SMV CATHETERIZATION

Success of PTP 61/68 (90%)		Failure of PTP 7/68 (10%)	
<i>SPV and SMV catheterization</i>			
Success 53/61 (87%)		Failure 8/61 (13%)	
	<i>SPV Failure</i> 6	<i>SMV Failure</i> 2	Portal vein thrombosis 2
	Splenic vein thrombosis 2		Poor technique 5
	Post splenectomy 2	Poor technique 2	
	Poor technique 2		

PTP; percutaneous transhepatic portal catheterization, SPV; splenic vein, SMV; superior mesenteric vein.

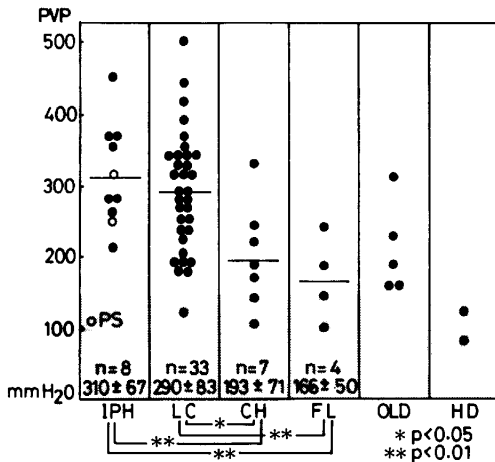


Fig. 2. Portal vein pressure in liver diseases. PVP; portal vein pressure, IPH; idiopathic portal hypertension, LC; liver cirrhosis, CH; chronic hepatitis, FL; fatty liver, OLD; other liver diseases, HD; hematological diseases, PS; post splenectomy.

Catheterization was abandoned when the number of punctures reached 20 times.

The main portal vein pressure was  $310 \pm 67$  mm H<sub>2</sub>O in idiopathic portal hypertension (IPH),  $290 \pm 83$  in liver cirrhosis (LC),  $193 \pm 71$  in chronic hepatitis (CH) and  $166 \pm 50$  in fatty liver (FL) (Fig. 2). PVP was more elevated in IPH and LC than in CH and FL ( $P < 0.01$ ). PVP was over 150 mm H<sub>2</sub>O in 2 of 4 cases of fatty liver (190, 235 mm H<sub>2</sub>O). In one case of fatty liver, hepatofugal collateral flow toward the hemiazygos vein was demonstrated by splenic venography (Fig. 3). In this case, peritoneoscopy revealed a yellowish smooth liver surface, and histology demonstrated marked fatty deposition without fibrosis or lobular distortion.

Portal vein pressure change in response to exercise was measured in 11 cases.

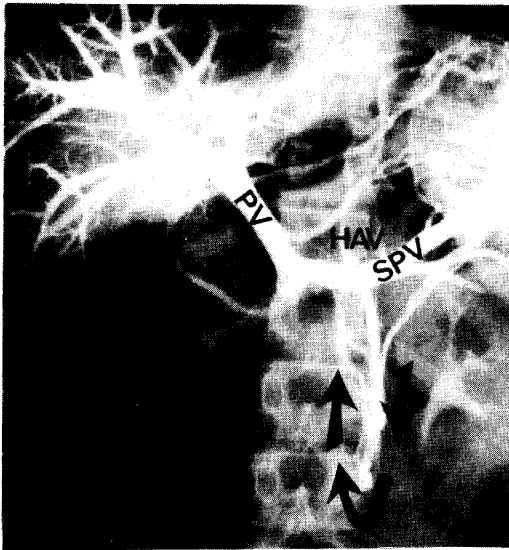


Fig. 3. Selective splenic venography in a case of fatty liver. Hepatofugal collateral blood flow toward hemiazygos vein is demonstrated (arrows). Portal vein pressure was 190 mm H<sub>2</sub>O. PV; portal vein, SPV; splenic vein, HAV; hemiazygos vein.

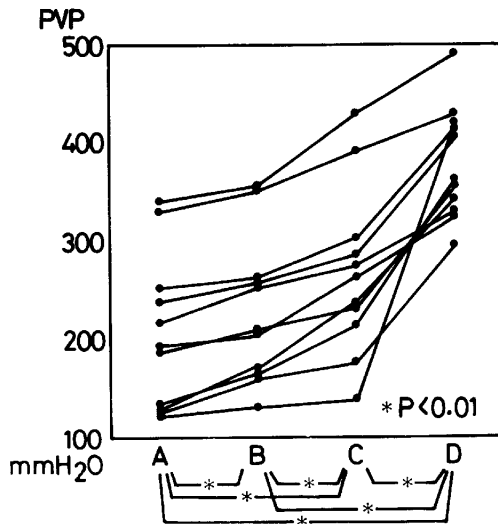


Fig. 4. Portal vein pressure changes due to exercise. PVP; portal vein pressure, A; before exercise, B; after saying several words, C; after 10 coughs, D; after a forced Valsalva maneuver.

PVP rose from  $205 \pm 75$  to  $229 \pm 70$  mm H<sub>2</sub>O after the patient said his name, age and address, to  $267 \pm 81$  after 10 coughs, and to  $380 \pm 55$  after a forced Valsalva maneuver (Fig. 4). PVP rose by 175 mm H<sub>2</sub>O on the average compared to the pre-exercise value after forced the Valsalva maneuver ( $P < 0.01$ ).

DISCUSSION

PTP has been performed in many institutions since 1974 (3-66). The pro-

cedure has become an important method for the diagnosis and treatment of portal hypertension. Our success rate (90 %) of PTP under fluoroscopic control was as high as those which has been reported (6, 61, 62). The success rate under fluoroscopic and ultrasonic control has been reported as 100 % (63) and 96 % (5). Ultrasonic guided liver puncture in conjunction with fluoroscopic control is desirable in cases of variceal bleeding or in patients with a bleeding tendency since portal vein catheterization can be achieved with fewer punctures.

In the present series, the PTP Chiba method was modified. The original Chiba method (7) is safer than other methods which do not use a probing thin needle. The Chiba method uses a thin PTC needle (0.7 mm in diameter) which is introduced into a right portal branch, and then a thicker PTP needle (0.8 mm in diameter, 30 cm in length) covered with a soft polyethylene catheter (1.45 mm in diameter) is introduced under guidance of the thin needle. The thin PTC needle allowed many liver punctures without complication. However, the soft polyethylene catheter sometimes could not be advanced into the main portal vein after removal of the stylet needle and tended to bend between the abdominal wall and the liver capsule in cases of liver cirrhosis. Therefore, in the present study, a thicker PTP needle (1.3 to 1.8 mm in diameter, 30 cm in length) sheathed with a firmer teflon catheter (2.0 to 2.6 mm in diameter) was used to improve the control of the catheter. However, the teflon catheter was sometimes difficult to advance into small portal branches. In these cases, a soft thin polyethylene catheter (1.0 to 1.7 mm in diameter, 50 to 60 cm in length) was inserted through the teflon catheter. Selective catheterization of the gastric coronary vein or short gastric veins was easily performed by our method.

So-called intrahepatic parasinusoidal portal hypertension (67) has been claimed to occur in fatty liver due to narrowed sinusoids compressed by fatty deposition. However, it has not been proven clinically. In the present series, PVP over 150 mm H<sub>2</sub>O was demonstrated in 2 of 4 cases of fatty liver and a hepatofugal collateral to the hemiazygos vein was observed in one case that showed no lobular distortion.

Increase in portal pressure is a critical problem for patients with gastroesophageal varices. Matsushita *et al.* (68) measured the portal pressure at a mesenteric vein for several days after abdominal operation and noticed PVP elevation in physiological states. Marked elevation of PVP was reconfirmed after coughing and forced Valsalva maneuvers in the present study. Avoidance of maneuvers that cause marked elevation of PVP in cases of portal hypertension with severe gastroesophageal varices is recommended.

#### REFERENCES

1. Bierman, H.R., Kelly, K.H., White, L.P., Coblenz, A. and Fisher, A.: Transhepatic venous catheterization and venography. *J. Am. Med. Assoc. (JAMA)* **158**, 1331-1334, 1955.
2. Reynolds, T.B., Ito, S. and Iwatsuki, S.: Measurement of portal pressure and its clinical appli-



- cation. *Am. J. Med.* **49**, 649-657, 1970.
3. Lunderquist, A. and Vang, J.: Sclerosing injection of esophageal varices through transhepatic selective catheterization of the gastric coronary vein. A preliminary report. *Acta Radiol. (Diagn)*. **15**, 546-550, 1974.
  4. Lunderquist, A. and Vang, J.: Transhepatic catheterization and obliteration of the coronary vein in patients with portal hypertension and esophageal varices. *N. Engl. J. Med.* **291**, 646-649, 1974.
  5. Burcharth, F.: Percutaneous transhepatic portography. I. Technique and application. *Am. J. Roentgenol.* **132**, 177-182, 1979.
  6. Kimura, K., Ido, K., Horiguchi, M., Nogami, W., Kosugi, J., Tanaka, M., Yoshida, I., Seki, S., Yamanaka, T. and Sakai, H.: Clinical significance of percutaneous transhepatic portal catheterization. *Jpn. J. Gastroenterol.* **77**, 206-213, 1980 (in Japanese).
  7. Suzuki, K., Nakajima, Y., Musha, H., Ohkubo, H., Kohen, H., Takayasu, K., Kotohda, K. and Okuda, K.: Percutaneous transhepatic portography. I. Method and clinical significance. *Acta Hepatol. Jpn.* **17**, 609-617, 1976 (in Japanese).
  8. Viamonte, M. Jr., LePage, J., Lunderquist, A., Pereiras, R., Russell, E., Viamonte, M. and Camacho, M.: Selective catheterization of the portal vein and its tributaries. Preliminary report. *Radiology* **114**, 457-460, 1975.
  9. Ingemansson, S., Lunderquist, A., Lundquist, I., Lovdahl, R. and Tibblin, S.: Portal and pancreatic vein catheterization with radioimmunologic determination of insulin. *Surg. Gynecol. Obstet.* **141**, 705-711, 1975.
  10. Ingemansson, S., Lunderquist, A. and Holst, J.: Selective catheterization of the pancreatic vein for radioimmunoassay in glucagon-secreting carcinoma of the pancreas. *Radiology* **119**, 555-556, 1976.
  11. Ingemansson, S., Larsson, Lars-Inge, Lunderquist, A. and Stadil, F.: Pancreatic vein catheterization with gastrin assay in normal patients and in patients with the Zollinger-Ellison syndrome. *Am. J. Surg.* **134**, 558-563, 1977.
  12. Ingemansson, S., Kuhl, C., Larsson, Lars-Inge, Lunderquist, A. and Lundquist, I.: Localization of insulinomas and islet cell hyperplasias by pancreatic vein catheterization and insulin assay. *Surg. Gynecol. Obstet.* **146**, 724-734, 1978.
  13. Millan, V.G., Molitch, M.E., Miller, H. and Jackson, I.M.D.: Localization of occult insulinoma by superselective pancreatic venous sampling for insulin assay through percutaneous transhepatic catheterization. *Diabetes* **28**, 249-251, 1979.
  14. Passaro, E. Jr.: Localization of pancreatic endocrine tumors by selective portal vein catheterization and radioimmunoassay. *Gastroenterology* **77**, 806-807, 1979.
  15. Burcharth, F., Stage, J.G., Stadil, F., Jensen, L.I. and Fischermann, K.: Localization of gastrinomas by transhepatic portal catheterization and gastrin assay. *Gastroenterology* **77**, 444-450, 1979.
  16. Reichardt, W., and Ingemansson, S.: Selective vein catheterization for hormone assay in endocrine tumors of the pancreas. *Acta Radiol. (Diagn)*. **21**, 177-187, 1980
  17. Kurihara, Y., Nakayama, H., Sasaki, T., Aoki, S., Oda, K., Sato, M., Kadoto, S., Nakagawa, S., Akiyama, S., Okuyama, S., Kato, H., Isomatsu, T. and Kobayashi, S.: Insulinoma identified from insulin and c-peptide determinations by pancreatic vein catheterization. *Tonyobyō* **22**, 1057-1066, 1979 (in Japanese).
  18. Scott, J., Long, R.G., Dick, R. and Sherlock, S.: Percutaneous transhepatic obliteration of gastroesophageal varices. *Lancet* **II**, 53-55, 1976.
  19. Goldman, M.L., Land, W.C. Jr., Bradley, E.L. III. and Andersen, J.: Transcatheter therapeutic embolization in the management of massive upper gastrointestinal bleeding. *Radiology* **120**, 513-

- 521, 1976.
20. Cooperman, A.M. and Alfydi, R.J.: Transhepatic variceal sclerotherapy. *Arch. Surg.* **111**, 609, 1976.
  21. Lunderquist, A., Simert, G., Tylen, U. and Vang, J.: Follow-up of patients with portal hypertension and esophageal varices treated with percutaneous obliteration of gastric coronary vein. *Radiology* **122**, 59-63, 1977.
  22. Pereiras, R., Viamonte, M. Jr., Russell, E., LePage, J., White, P. and Huston, D.: New techniques for interruption of gastroesophageal venous blood flow. *Radiology* **124**, 313-323, 1977.
  23. Viamonte, M. Jr., Pereiras, R., Russell, E., LePage, J. and Huston, D.: Transhepatic obliteration of gastroesophageal varices: Results in acute and nonacute bleeders. *Am. J. Roentgenol.* **129**, 237-241, 1977.
  24. Nakao, N., Okada, K., Inamoto, K., Miura, T., Kyo, A., Okamoto, E. and Uchida, H.: Percutaneous transhepatic obliteration of gastroesophageal varices in liver cirrhosis. *Acta Med. Hyogo* **2**, 147-153, 1977 (in Japanese).
  25. Lunderquist, A., Borjesson, B., Owman, T. and Bengmark, S.: Isobutyl 2-cyanoacrylate (Bucrylate) in obliteration of gastric coronary vein and esophageal varices. *Am. J. Roentgenol.* **130**, 1-6, 1978.
  26. Kyo, A., Okamoto, E., Kuwada, K., Sugawara, I., Shu, A., Ren, T. and Nakao, N.: Nonoperative treatment with percutaneous transhepatic obliteration of coronary and short gastric vein. *Jpn. J. Gastroenterol.* **75**, 973-979, 1978 (in Japanese).
  27. Hoevels, J. and Joelsson, B.: A comparative study of esophageal varices by endoscopy and percutaneous transhepatic esophageal phlebography. *Gastrointest. Radiol.* **4**, 323-329, 1979.
  28. Roche, A., Kunstlinger, F., Curet, P. and Doyon, D.: Balloon catheter to control transhepatic obliteration of gastroesophageal varices. *Am. J. Roentgenol.* **132**, 647-649, 1979.
  29. Freeny, P.C. and Kidd, R.: Transhepatic portal venography and selective obliteration of gastroesophageal varices using isobutyl 2-cyanoacrylate (Bucrylate). *Am. J. Dig. Dis.* **24**, 321-330, 1979.
  30. Henderson, J.M., Buist, T.A.S. and Macpherson, A.I.S.: Percutaneous transhepatic occlusion of bleeding esophageal varices. *Br. J. Surg.* **66**, 569-571, 1979.
  31. Katzen, B.T., Passariello, R., Rossi, P., Simonetti, G. and Chang, J.: Percutaneous transhepatic portal venography in the diagnosis and management of gastroesophageal varices. *South. Med. J.* **72**, 942-945, 1979.
  32. Funaro, A.H., Ring, E.J., Freiman, D.B., Oleaga, J.A. and Gordon, R.L.: Transhepatic obliteration of esophageal varices using the stainless steel coil. *Am. J. Roentgenol.* **133**, 1123-1125, 1979.
  33. Bengmark, S., Borjesson, B., Hoevels, J., Joelsson, B., Lunderquist, A. and Owman, T.: Obliteration of esophageal varices by PTP. A follow-up of 43 patients. *Ann. Surg.* **190**, 549-554, 1979.
  34. Takayasu, K., Takashi, M., Musha, H., Okuda, K., Kobayashi, C., Kato, J. and Takase, J.: Evaluation of the three different methods of percutaneous transhepatic obliteration. Especially the use of balloon catheter and stainless steel coil. *Jpn. J. Gastroenterol.* **77**, 805, 1980 (in Japanese).
  35. Shu, A., Okamoto, E., Kyo, A., Nakao, N. and Sugiki, K.: Obliteration of esophageal varices. *Geka Chiryō* **42**, 297-308, 1980 (in Japanese).
  36. Sugiki, K., Nakao, N., Takayasu, Y., Miura, K., Miura, T., Kyo, A., Shu, A. and Ishikawa, Y.: Percutaneous transhepatic obliteration of gastroesophageal varices in liver cirrhosis. *Rinsho Hoshasen* **24**, 1479-1485, 1979 (in Japanese).

37. Ishikawa, Y., Ito, N., Morigaki, T., Ashida, H., Miyai, M., Okamoto, E., Kyo, A., Shu, A., Nakao, N. and Sugiki, K.: Evaluation, complications and limitations of percutaneous transhepatic obliteration of bleeding gastroesophageal varices. *Jpn. J. Gastroenterol. Surg.* **12**, 823-831, 1979 (in Japanese).
38. Kusano, S., Kobayashi, T., Horichi, S., Madama, S. and Akima, R.: Cyanoacrylate in transhepatic obliteration of gastroesophageal varices. Comparison with continuous basopressin infusion. *Nichi Doku Iho* **24**, 546-555, 1979 (in Japanese).
39. Nakao, N., Sugiki, K., Chin, K., Miura, T., Kyo, A., Okamoto, E., Ishikawa, Y. and Uchida, H.: Transhepatic embolization of gastroesophageal varices in liver cirrhosis. *Nippon Igaku Hoshasen Gakkai Zasshi* **38**, 852-861, 1978 (in Japanese).
40. Nakao, N., Sugiki, K., Takayasu, Y., Kyo, A., Shu, A., Okamoto, E., Miyai, M. and Ishikawa, Y.: Percutaneous transhepatic obliteration of gastroesophageal varices. *J. Clin. Surg.* **35**, 303-309, 1980 (in Japanese).
41. Uchida, H., Nakamura, H., Yoshioka, H., Kuroda, T., Sato, M., Tokunaga, A., Hori, S., Ohi, H., Kitatani, T., Nakao, R., Seki, K., Higashi, H., Kobayashi, Y. and Fujino, M.: Transcatheter embolization therapy for massive gastrointestinal bleeding. *Nichi Doku Iho* **24**, 519-528, 1979 (in Japanese).
42. Toda, K., Yamasaki, T., Tagami, H., Muto, H., Takasaki, K., Yamada, A. and Kobayashi, S.: Percutaneous transhepatic obliteration of gastroesophageal varices. Application for poor risk patients. *Nichi Doku Iho* **24**, 536-545, 1979 (in Japanese).
43. Umeda, K., Asano, T., Sato, Y., Karatani, S., Mizuno, T., Tominaga, N. and Morita, K.: Experience with percutaneous transhepatic coronary vein occlusion (PTCVO). *Nippon Univ. Med. J.* **39**, 503-507, 1980 (in Japanese).
44. Russell, E., LePage, J.R., Viamonte, M.Jr., Levi, J.U. and Meier, W.L.: An angiographic approach to hepatobiliary diseases. *Surg. Gynecol. Obstet.* **143**, 414-424, 1976.
45. Viamonte, M.Jr., Pereiras, R., Russell, E., LePage, J. and Meier, W.L.: Pitfalls in transhepatic portography. *Radiology* **124**, 325-329, 1977.
46. Musha, H., Nakajima, Y., Suzuki, K., Takayasu, K., Ohkubo, H., Kohen, H., Suzuki, N., Kotohda, K. and Okuda, K.: Percutaneous transhepatic portography. II. Measurement of intra- and extra- hepatic shunts using the procedure for PTP and MAA labelled with <sup>131</sup>I and <sup>99m</sup>Tc. *Acta Hepatol. Jpn.* **18**, 353-363, 1977 (in Japanese).
47. Boyer, T.D., Triger, D.R., Horisawa, M., Redeker, A.G. and Reynolds, T.B.: Direct transhepatic measurement of portal vein pressure using a thin needle. Comparison with wedged hepatic vein pressure. *Gastroenterology* **72**, 584-589, 1977.
48. Adamsons, R.J., Butt, K., Dennis, C.R., Kinkhabwala, M., Moskowitz, H., Gordon, D., and Babich, A.: Prognostic significance of portal pressure in patients with bleeding esophageal varices. *Surg. Gynecol. Obstet.* **145**, 353-356, 1977.
49. Musha, H., Takayasu, K., Nakajima, Y., Kohen, H., Ohkubo, H., Kohno, K., Suzuki, N., Suzuki, N., Kotohda, K. and Okuda, K.: Percutaneous transhepatic portography. III. Clinical significance of intrahepatic shunt index measured by this technique. *Acta Hepatol. Jpn.* **19**, 871-879, 1978 (in Japanese).
50. Nunez, D.Jr., Russell, E., Yrizarry, J., Pereiras, R. and Viamonte, M.Jr.: Portosystemic communications studies by transhepatic portography. *Radiology* **127**, 75-79, 1978.
51. Burcharth, F., Nielbo, N. and Andersen B.: Percutaneous transhepatic portography. II. Comparison with splenoportography in portal hypertension. *Am. J. Roentgenol.* **132**, 183-185, 1979.
52. Burcharth, F., Sorensen, T.A. and Andersen, B.: Percutaneous transhepatic portography. III. Relationships between portosystemic collaterals and portal pressure in cirrhosis. *Am. J. Roent-*

- genol.* **133**, 1119-1122, 1979.
53. Takayasu, K., Takashi, M., Musha, H., Okuda, K., Kohen, H. and Arimizu, N.: Percutaneous transhepatic portography. IV. Clinical significance of extrahepatic shunt index measured by this technique. *Acta Hepatol. Jpn.* **20**, 1048-1055, 1979 (in Japanese).
  54. Wales, L.R., Morishima, M.S. and Alan, T.N.K.: Portal vein thrombosis: Diagnosis via percutaneous transhepatic needle. *Am. J. Roentgenol.* **134**, 842-844, 1980.
  55. Smith-Laing, G., Camilo, M.E., Dick, R. and Sherlock, S.: Percutaneous transhepatic portography in the assessment of portal hypertension. Clinical correlations and comparison of radiographic techniques. *Gastroenterology* **78**, 197-205, 1980.
  56. Takashi, M., Takayasu, K., Kohen, H., Musha, H., Kotohda, K. and Okuda, K.: Percutaneous transhepatic portography. VI. Extrahepatic porta-systemic shunt and its clinical significance in portal hypertension. *Acta Hepatol. Jpn.* **21**, 857-865, 1980 (in Japanese).
  57. Moehrl, M., Wannagat, L. and Gehring, D.: Portal hypertension in chronic hepatitis. Comparative manometric and clinico-chemical examinations. *Klin. Wochenschr.* **58**, 207-208, 1980.
  58. Nakao, N. and Sugiki, K.: Obliteration of esophageal varices. *Nichi Doku Iho* **24**, 529-535, 1979 (in Japanese).
  59. Ido, K., Sakai, H., Horiguchi, M., Furusugi, Y., Nogami, W., Tanaka, M., Yoshida, Y., Seki, H., Yamanaka, T. and Kimura, K.: A comparative study of portal vein pressure and endoscopic findings of esophageal varices in 50 cases of liver cirrhosis. *Jpn. J. Gastroenterol.* **77**, 871-877, 1980 (in Japanese).
  60. Okui, K. and Hoevels, J.: Percutaneous transhepatic portography. *Chiba Igaku* **55**, 351-356, 1979 (in Japanese).
  61. Takayasu, K., Takashi, M., Musha, H., Okuda, K. and Kobayashi, C.: Percutaneous transhepatic portography (PTP). V. Improvement of the technique, results in 133 cases, and radiological findings. *Acta Hepatol. Jpn.* **21**, 846-856, 1980 (in Japanese).
  62. Okuda, K., Suzuki, K., Musha, H. and Arimizu, N.: Percutaneous transhepatic catheterization of the portal vein for the study of portal hemodynamics and shunts. A preliminary report. *Gastroenterology* **73**, 279-284, 1977.
  63. Kimura, K., Ohto, M., Tuchiya, Y., Ebara, M., Kimura, M., Takahashi, N., Saotome, N., Suzuki, Y., Saisho, H., Ohno, T., Karasawa, E., Morita, M., Miki, M., Ueno, T., Ito, F., Nagase, T. and Yogi, Y.: Ultrasonically guided percutaneous transhepatic portal vein catheterization with linear electronic scanner and puncture transducer, and its clinical utilization. *Igaku No Ayumi* **107**, 916-923, 1978 (in Japanese).
  64. Burcharth, F. and Rasmussen, S.N.: Localization of the porta hepatis by ultrasonic scanning prior to percutaneous transhepatic portography. *Br. J. Radiol.* **47**, 598-600, 1974.
  65. Hoevels, J., Lunderquist, A. and Tylen, U.: Percutaneous transhepatic portography. *Acta Radiol. (Diagn).* **19**, 643-655, 1978.
  66. Hoevels, J. and Lunderquist, J.: Technique of percutaneous transhepatic portography. *Chiba Med. J.* **56**, 151-155, 1980.
  67. Leevy, C.M., Popper, H. and Sherlock, S.: Portal hypertension, In *Diseases of the liver and biliary tract. Standardization of nomenclature, diagnostic criteria, and diagnostic methodology.* DHEW Publication, Washington, pp. 49-50, 1976.
  68. Matsushita, R., Ito, T., Arichi, M., Kubo, T., Nagai, M. and Sugimura, K.: Clinical study on portal pathophysiology. Method of portal catheterization and its clinical application. *Saishin Igaku* **12**, 1393-1402, 1957 (in Japanese).