

Acta Medica Okayama

Volume 36, Issue 2

1982

Article 7

APRIL 1982

Bone marrow examination for detection of metastasis in patients with bronchogenic carcinoma: an evaluation of 107 patients.

Taisuke Ohnoshi, *Okayama University*
Shunkichi Hiraki, *Okayama University*
Yasunari Nakata, *Okayama University*
Yasunori Nakata, *Okayama University*
Ken-ichi Miyake, *Okayama University*
Jun-ichi Harada, *Okayama University*
Siro Ozawa, *Okayama University*
Tetsuo Tamura, *Okayama University*
Takumi Seto, *Okayama University*
Masahiro Miyai, *Okayama University*
Toshio Tanaka, *Okayama University*
Ikuro Kimura, *Okayama University*

Bone marrow examination for detection of metastasis in patients with bronchogenic carcinoma: an evaluation of 107 patients.*

Taisuke Ohnoshi, Shunkichi Hiraki, Yasunari Nakata, Yasunori Nakata, Ken-ichi Miyake, Jun-ichi Harada, Siro Ozawa, Tetsuo Tamura, Takumi Seto, Masahiro Miyai, Toshio Tanaka, and Ikuro Kimura

Abstract

As a staging procedure before treatment, examination of bone marrow from the posterior iliac crest was performed on a total of 107 patients with bronchogenic carcinoma. Among them, 11 patients (10.3%) had metastasis in the bone marrow: five of 39 adenocarcinomas, five of 33 small cell carcinomas, one of four large cell carcinomas, and none of 31 epidermoid carcinomas. Leukoerythroblastosis was found exclusively in the patients with metastasis, although the presence of tumor cells in the bone marrow did not correlate well with peripheral blood cell counts. Survival following an intensive chemotherapy in patients with bone marrow metastasis was substantially longer for those with small cell carcinoma than for those with other histologic types of bronchogenic carcinoma.

KEYWORDS: bronchogenic carcinoma, bone marrow metastasis

*PMID: 7136851 [PubMed - indexed for MEDLINE]

Copyright (C) OKAYAMA UNIVERSITY MEDICAL SCHOOL

BONE MARROW EXAMINATION FOR DETECTION OF METASTASIS IN PATIENTS WITH BRONCHOGENIC CARCINOMA : AN EVALUATION OF 107 PATIENTS

Taisuke OHNOSHI, Shunkichi HIRAKI, Yasunari NAKATA, Yasunori NAKATA
Ken-ichi MIYAKE, Jun-ichi HARADA, Siro OZAWA, Tetsuo TAMURA
Takumi SETO, Masahiro MIYAI, Toshio TANAKA*
and Ikuro KIMURA

*Second Department of Medicine ; and * Pathology Section, Central Laboratories,
Okayama University Medical School, Okayama 700, Japan*

Received October 20, 1981

Abstract. As a staging procedure before treatment, examination of bone marrow from the posterior iliac crest was performed on a total of 107 patients with bronchogenic carcinoma. Among them, 11 patients (10.3 %) had metastasis in the bone marrow : five of 39 adenocarcinomas, five of 33 small cell carcinomas, one of four large cell carcinomas, and none of 31 epidermoid carcinomas. Leukoerythroblastosis was found exclusively in the patients with metastasis, although the presence of tumor cells in the bone marrow did not correlate well with peripheral blood cell counts. Survival following an intensive chemotherapy in patients with bone marrow metastasis was substantially longer for those with small cell carcinoma than for those with other histologic types of bronchogenic carcinoma.

Key words : bronchogenic carcinoma, bone marrow metastasis.

In patients with bronchogenic carcinoma, the extent of disease at the time of diagnosis is a reliable indicator for optimal treatment and for prognosis. A number of papers has been published in the United States and in Europe, indicating that bone marrow examination is an important procedure in the initial staging of patients with bronchogenic carcinoma (1-5).

This study provides the frequency and clinical correlation of bone marrow metastasis in a series of Japanese patients with bronchogenic carcinoma.

MATERIALS AND METHODS

Since April 1977, a total of 107 patients with histologically verified bronchogenic carcinoma have been evaluated consecutively for the presence of bone marrow metastasis.

Prior to chemotherapy, all patients routinely underwent the following staging procedures : clinical history, physical examination, chest X-ray, fiberoptic bronchoscopy, skeletal X-ray, and examination of bone marrow from the posterior iliac crest of one side. Laboratory examination included complete blood cell counts, serum GOT and GPT, serum alkaline phosphatase, serum lactate dehydrogenase and serum electrolytes. Scanning of the bone

with ^{99m}Tc -pyrophosphate and of the brain and upper abdomen with computerized axial tomography was performed in almost all patients.

Bone marrow biopsy was performed from the posterior iliac crest using a Jamshidi needle (6), and was followed by aspiration from the same side of the iliac crest. A smear made from the aspirate was stained with May-Grünwald-Giemsa. The remainder was allowed to clot, fixed, sectioned and stained with hematoxylin and eosin; several other special stains were employed, when necessary.

RESULTS

Bone marrow metastasis related to histologic type is shown in Table 1. Tumor cells in the bone marrow were identified in 11 of 107 patients (10.3%). The

TABLE 1. BONE MARROW EXAMINATION BY CELL TYPE AND EXTENT OF DISEASE IN 107 PATIENTS WITH BRONCHOGENIC CARCINOMA

Histologic type	Limited disease ^a		Extensive disease		Limited + Extensive		
	No. of patients examined	Positive	No. of patients examined	Positive	No. of patients examined	Positive	Per cent positive
Adenocarcinoma	10	0	29	5	39	5 ^b	12.8
Small cell carcinoma	16	1	17	4	33	5 ^c	15.2
Epidermoid carcinoma	22	0	9	0	31	0	0
Large cell carcinoma	2	0	2	1	4	1	25
Total	50	1	57	10	107	11	10.3

^a Disease confined to one hemithorax including ipsilateral supraclavicular lymph nodes before bone marrow examination. ^b In 2 patients, aspirate was unobtainable (dry tap).

^c In 2 patients, bone marrow sections were negative despite of positive findings on smears of aspirate.

frequency of the bone marrow metastasis was related to the histological type; 12.8% (5/39) in adenocarcinoma, 15.2% (5/33) in small cell carcinoma, 25% (1/4) in large cell carcinoma, and none of 31 patients with epidermoid carcinoma. Bone marrow metastasis was more frequent in patients with extensive disease than in those with limited disease ($p < 0.01$). "Limited disease" here is defined as the disease confined to a hemithorax including ipsilateral supraclavicular lymph nodes prior to bone marrow examination. In other words, 10 out of 57 patients (17.5%) had bone marrow metastasis; these 57 patients already had an extensive disease according to staging procedures other than bone marrow examination. On the other hand, only one of 50 patients (2%) showed bone marrow metastasis; these 50 patients were negative, likewise, in staging procedures other than bone marrow examination.

Metastasis to the bone marrow correlated to some extent with that to bone itself; bone examination with skeletal X-ray and/or scan was positive in seven of 11 patients (63.6%) with positive bone marrow biopsy, while that with both X-ray and scan was positive in 20 of 75 patients (26.6%) with negative bone

marrow biopsy.

Tumor cells were identified in both biopsy and aspirate in seven of the 11 patients, and in either the biopsy or in the aspirate of the remaining four. In two patients with adenocarcinoma, aspirate was not obtained ("dry tap") although tumor was detected in the biopsied specimen. In two patients with small cell carcinoma, tumor cells were found in aspirate despite negative biopsy specimens.

Metastatic adenocarcinoma and small cell carcinoma in the bone marrow are represented in Figs. 1 and 2, respectively. Histologically, the tumor obtained by bone marrow biopsy was identical to the primary carcinoma of the lung. Tumor was associated with fibrosis and/or osteosclerosis in biopsied specimens from patients who had adenocarcinoma and a dry tap of the marrow. It was sometimes difficult to differentiate adenocarcinoma from large cell carcinoma on smeared aspirates. On the other hand, small cell carcinoma was easily identified because of morphological characteristics as described by Hansen *et al.* (7).

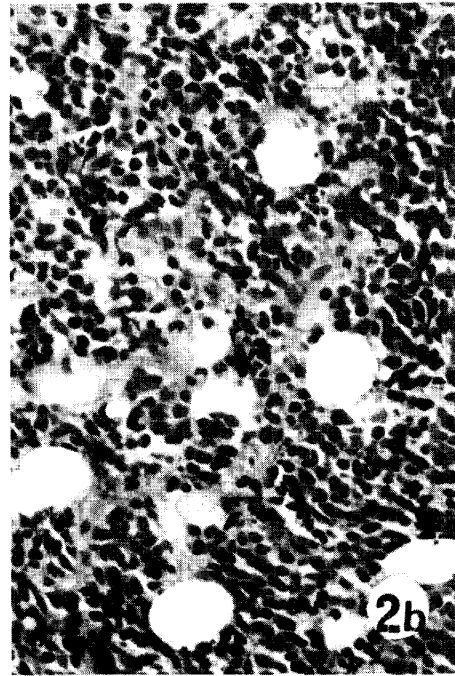
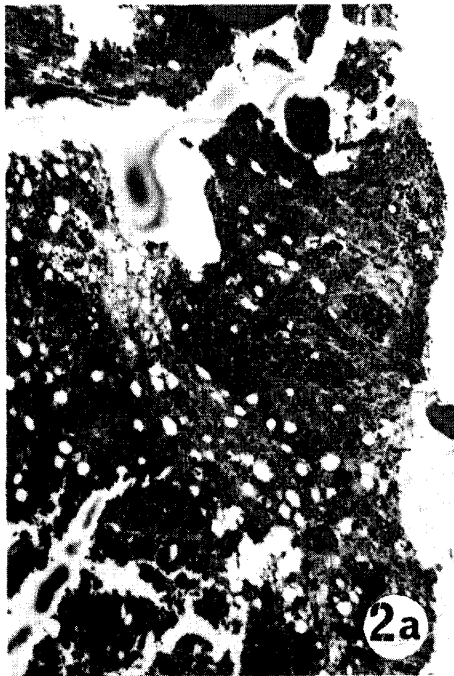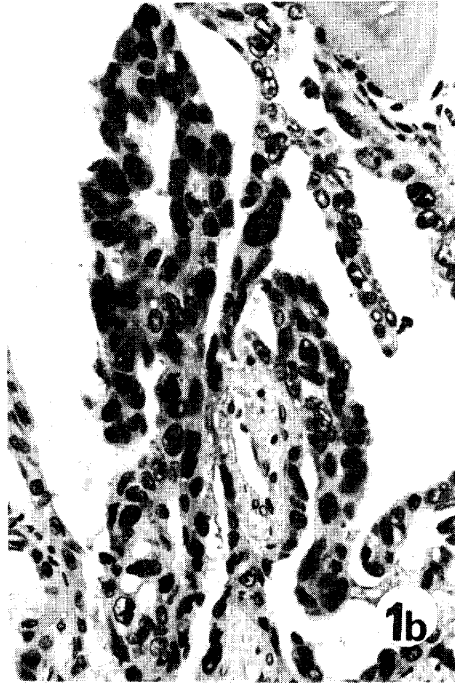
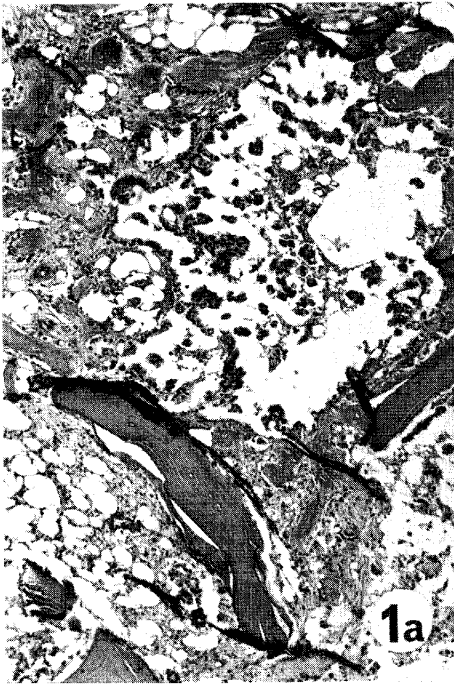
Hematologic findings at the time of diagnosis are shown in Table 2. There were no differences in the counts of white blood cells, red blood cells and platelets between patients with positive and negative marrow biopsies. The frequency of cytopenia was somewhat higher in patients with positive marrow biopsy ($p < 0.1$), and leukoerythroblastosis on peripheral blood smear was found only in patients with a positive marrow biopsy ($p < 0.001$).

All 11 patients with bone marrow metastasis, except one, received combination chemotherapy consisting of cyclophosphamide, vincristine, methotrexate and procarbazine(8). Three of five patients with small cell carcinoma responded to

TABLE 2. HEMATOLOGIC FINDINGS AT DIAGNOSIS IN 107 PATIENTS WITH BRONCHOGENIC CARCINOMA

	Marrow positive (11 patients)	Marrow negative (96 patients)
WBC count (cell/mm ³)		
Median	8,200	6,800
Range	3,700-11,800	3,000-17,700
RBC count (cell × 10 ⁶ /mm ³)		
Median	4.09	4.01
Range	2.23-5.54	2.29-5.02
Platelet count (cell × 10 ³ /mm ³)		
Median	286	321
Range	98-437	157-701
No. of patients with leukoerythroblastosis ^a	4	0
No. of patients with severe anemia and/or other cytopenia ^b	2	5

^a 2% or more nucleated RBCs and/or 2% or more immature WBCs (myelocyte or younger) on differential count. ^b WBC < 4,000, RBC < 3.0 × 10⁶, or platelet < 150 × 10³.



the treatment; two completely and one partially. The median survival of the five was eight months, which did not differ largely from that of patients with extensive disease and given the same regimen (8). However, none of the remaining five patients with other histologic types responded to the treatment, the median survival being only four months.

DISCUSSION

The results obtained in this study revealed that bone marrow metastasis was demonstrable in a considerable proportion of patients with bronchogenic carcinoma. The frequency of bone marrow metastasis in our series was higher in small cell carcinoma (15.2 %) than in adenocarcinoma (12.8 %); large cell carcinoma was excluded owing to the small number of patients examined and epidermoid carcinoma had none. Of 150 patients reported by Hansen *et al.* (1), 46.6 % with small cell carcinoma, 18.5 % with adenocarcinoma, 12.5 % with large cell carcinoma and 3.6 % with epidermoid carcinoma had bone marrow metastasis at the time of diagnosis. Others (3, 4, 7) have also reported the high frequency of bone marrow metastasis in small cell carcinoma in contrast to epidermoid carcinoma.

As for small cell carcinoma, earlier studies (1, 7, 9, 10) reported a high frequency of bone marrow metastasis ranging from 32 to 46 %, indicating that bone marrow examination was often found to be positive in patients who otherwise had been classified as having limited disease. Our results confirm more recent reports (2, 3, 5) of a low frequency of bone marrow metastasis (17-21 %) and a limited yield by bone marrow examination when all other staging procedures are negative. The use of staging procedures more often than before for early detection of tumor in patients with less advanced stages of disease probably explains the differences in the above figures.

Most of the patients with bone marrow metastasis in this series had normal peripheral blood counts, except for a moderate degree of anemia. Only the patients with bone marrow metastasis showed leukoerythroblastosis in peripheral blood; the leukoerythroblastosis, therefore, strongly suggests bone marrow metastasis in patients with bronchogenic carcinoma (3).

There have been studies indicating the superiority of bone marrow biopsy over aspirate in the diagnosis of bone marrow metastasis (5, 10). Bone marrow biopsy, however, did not detect two cases of metastasis in small cell carcinoma, even though tumor cells were demonstrated in the smeared aspirate. Hirsch *et al.*

Fig. 1. a: Focus of adenocarcinoma surrounded by normal-appearing bone marrow. H.E., $\times 40$.
b: A close-up view of adenocarcinoma showing well differentiated papillotubular pattern. H.E., $\times 400$.

Fig. 2. a: Massively infiltrating small cell carcinoma in the bone marrow. H.E., $\times 40$. b: A close-up view of small cell carcinoma, showing nearly the same nuclear size of the tumor cells as intermingled red cells. H.E., $\times 400$.

(3) reported that aspirate was more sensitive than biopsy for detecting metastasis, in particular, in small cell carcinoma. Therefore, the combined use of biopsy and aspirate of the bone marrow is recommended in order to improve the detection of the metastasis.

The median survival of the five patients with small cell carcinoma was eight months with a complete response rate of 40 %, although inferior therapeutic results might be expected in patients with bone marrow metastasis not only because of large tumor burdens involving various vital organs but also because of an impaired bone marrow reserve. Ihde *et al.* (5) found almost identical response rates and survivals to our study in their marrow-positive and -negative patients with small cell carcinoma. Hence, intensive chemotherapy should be instituted in the patients with small cell carcinoma, even when the bone marrow is massively involved at the time of diagnosis.

REFERENCES

1. Hansen, H.H. and Muggia, F.M.: Staging of inoperable patients with bronchogenic carcinoma with special reference to bone marrow examination and peritoneoscopy. *Cancer* **30**, 1395-1401, 1972.
2. Anner, R.M. and Drewinko, B.: Frequency and significance of bone marrow involvement by metastatic solid tumors. *Cancer* **39**, 1337-1344, 1977.
3. Hirsch, F., Hansen, H.H., Donbernowsky, P., and Hainau, B.: Bone marrow examination in the staging of small-cell anaplastic carcinoma of the lung with special reference to subtyping. An evaluation of 203 consecutive patients. *Cancer* **39**, 2563-2567, 1977.
4. Ihde, D.C., Simms, E.B., Matthews, M.J., Cohen, M.H., Bunn, P.A., and Minna, J.D.: Bone marrow metastasis in small cell carcinoma of the lung: Frequency, description, and influence on chemotherapeutic toxicity and prognosis. *Blood* **53**, 677-686, 1979.
6. Jamshidi, K., and Swaim, W.R.: Bone marrow biopsy with unaltered architecture - a new biopsy device. *J. Lab. Clin. Med.* **77**, 335-342, 1971.
7. Hansen, H.H., Muggia, F.M., and Selawry, O.S.: Bone marrow examination in 100 consecutive patients with bronchogenic carcinoma. *Lancet* **1**, 443-445, 1971.
8. Kimura, I., Moritani, Y., Ohnoshi, T., Nakata, Y., Oka, A., Toyota, K., Takasugi, K., Fujii, M., Machida, K., Murakami, N., Nakata, Y., Hayashi, K., Kanagawa, O., and Miyata, A.: Combination chemotherapy with cyclophosphamide, vincristine, methotrexate and procarbazine (COMP) in nonresectable lung cancer. *Lung Cancer* **18**, 149-155, 1978 (in Japanese).
9. Präuer, H.W., Rastetter, J., Sauer, E., and Ultsch, B.: Ergebnisse der ungezielten Beckenkamm-Biopsie bei Patienten mit Bronchus-Karzinom. *Munch. Med. Wochenschr.* **117**, 1821-1824, 1975.
10. Singh, G., Krause, J.R., and Breifeld, V.: Bone marrow examination for metastatic tumor. Aspirate and biopsy. *Cancer* **40**, 2317-2321, 1977.
11. Eagan, R.T., Mauer, L.H., Forcier, R.J., and Tulloh, M.: Combination chemotherapy and radiation therapy in small cell carcinoma of the lung. *Cancer* **32**, 371-375, 1973.