

Acta Medica Okayama

Volume 36, Issue 6

1982

Article 5

DECEMBER 1982

A Case of Monostotic Fibrous Dysplasia of the Temporal Bone Asso-ciated with Epileptic Seizure

Keiko Nishioka*

Yu Masuda†

Ikuo Inokuchi‡

Kuniaki Iyoda**

Toshio Tanaka††

*Okayama University,

†Okayama University,

‡Okayama University,

**Okayama University,

††Okayama University,

A Case of Monostotic Fibrous Dysplasia of the Temporal Bone Associated with Epileptic Seizure*

Keiko Nishioka, Yu Masuda, Ikuo Inokuchi, Kuniaki Iyoda, and Toshio Tanaka

Abstract

An 11-year-old male with monostotic fibrous dysplasia of the left temporal bone was reported. At the age of seven years, the patient began having epileptic attacks, and a bony swelling of the left temporal region was noticed by his mother. Roentgenologically, there were almost thorough osseous obstruction and osseous proliferation of the external auditory canal and pars petrosa, respectively. Audiologic examinations indicated gradual functional disturbance based on the affected internal ear. A total of 20 cases with monostotic fibrous dysplasia of the temporal bone reported between 1946 and 1980 was analyzed, and the association of fibrous dysplasia and epilepsy was discussed.

KEYWORDS: fibrous dysplasia, temporal bone, epilepsy

*PMID: 7158427 [PubMed - indexed for MEDLINE]

Copyright (C) OKAYAMA UNIVERSITY MEDICAL SCHOOL

**A CASE OF MONOSTOTIC FIBROUS DYSPLASIA OF
THE TEMPORAL BONE ASSOCIATED WITH
EPILEPTIC SEIZURE**

Keiko NISHIOKA, Yu MASUDA, Ikuo INOKUCHI,
Kuniaki IYODA* and Toshio TANAKA**

*Department of Otorhinolaryngology; *Department of Pediatrics; **Pathology Section,
Central Laboratories, Okayama University Medical School, Okayama 700, Japan*

Received April 10, 1982

Abstract. An 11-year-old male with monostotic fibrous dysplasia of the left temporal bone was reported. At the age of seven years, the patient began having epileptic attacks, and a bony swelling of the left temporal region was noticed by his mother. Roentgenologically, there were almost thorough osseous obstruction and osseous proliferation of the external auditory canal and pars petrosa, respectively. Audiologic examinations indicated gradual functional disturbance based on the affected internal ear. A total of 20 cases with monostotic fibrous dysplasia of the temporal bone reported between 1946 and 1980 was analyzed, and the association of fibrous dysplasia and epilepsy was discussed.

Key words : fibrous dysplasia, temporal bone, epilepsy.

A case of monostotic fibrous dysplasia involving almost entire left temporal bone is reported. The patient had developed epileptic attacks by the time a bony swelling of the left temporal region was noted. Otologically, in addition, he manifested unique signs, including roentgenologic and neurologic findings of the eighth cranial nerve. A total of 20 cases with monostotic fibrous dysplasia in the temporal bone during the period from 1946 by Schlumberger to 1980 by Barrionuevo *et al.* is analyzed (1-16) and compared with our case.

CASE PRESENTATION

An 11-year-old boy consulted the Department of Otorhinolaryngology, Okayama University Hospital, complaining of a painless, bony swelling of the left temporal area complicated by deafness which was caused by obstruction of the left external auditory canal. At the age of seven years, when his mother noticed a bony swelling of the left temporal region, the patient started, in awakening, epileptic attack with loss of consciousness lasting about 30 sec. The attack was mainly a tonic seizure: both the eyes and head deviated towards the left, and the left upper extremity was lifted to the same direction. There was no cyanosis during the attack, or sleep-in after. Electroencephalographic examination confirmed epilepsy, and appropriate therapy was commenced. The

epileptic attacks reduced to once every one to two months. In March 1981, he hit the left side of his face against the floor by falling down from steps. Thereafter, he once again developed attacks more often than before treatment, and the swelling of the left temporal area increased. Family, prenatal, perinatal and postnatal, up to the age of seven, histories were not unusual; the patient was born smoothly at 40 weeks of gestation with a body weight of 3,150 g and mild jaundice.

At the time of presentation at our Department, the general stature, nutritional state, and development and motility of fore extremities were normal. No skin pigmentation or endocrinological abnormalities, as seen in Albright's syndrome, were present. Around the left auricle, there was a prominent, hard, painless swelling of the temporal bone, especially of the squama, mastoid process and zygoma (Fig. 1). Local examination revealed almost complete osseous obstruction of the left external auditory meatus, preventing exploration of the tympanic membrane.

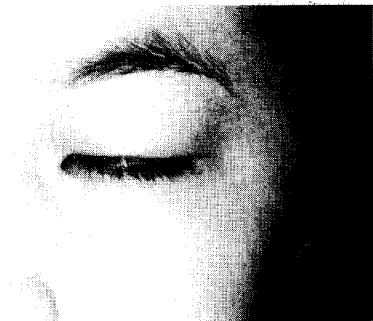

Fig. 1. Patient's outlook showing the left auricle with a prominent swelling of the temporal bone.

Laboratory examinations, including Ca, P, alkaline and acid phosphatases, ophthalmologic examination and cerebrospinal fluid were all within normal limits. Neurologically, facial expression, sense of taste, corneal and pharyngeal reflexes, and motility of the larynx and vocal cords were not unusual.

As to audiological examinations, with audiogram, the left ear showed a high degree of conductive deafness, and a low degree of perceptive deafness especially in the low tone threshold (Fig. 2). Equilibrical function test disclosed no deviation of the four extremities or development of nystagmus, although constant, fine nystagmus-like waves were detected by electronystagmograph. The optokinetic pattern was poor for nystagmus in the central area; rotatory test was different in responded nystagmus between the left and right; and the caloric test of the right ear was normal for responded nystagmus whereas that of the left ear did not respond entirely. The basic pattern of the electroencephalogram was diffusely dysrhythmic because of increased 4-7 cycles per second theta waves. The left temporal area showed a focal low voltage, possibly due

Audiogram

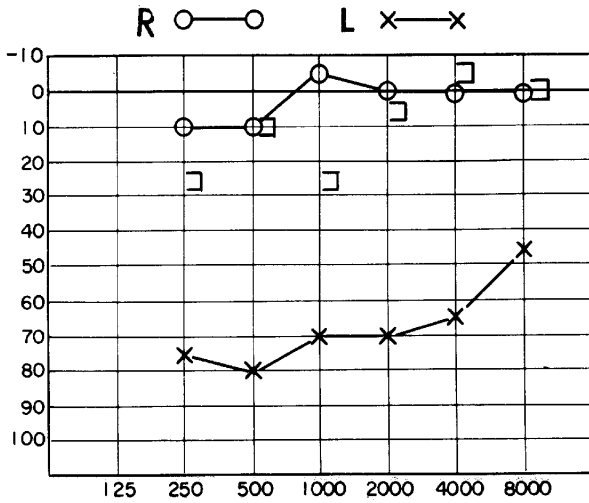


Fig. 2. Audiogram showing a high degree of conductive deafness in the left side of the ear.

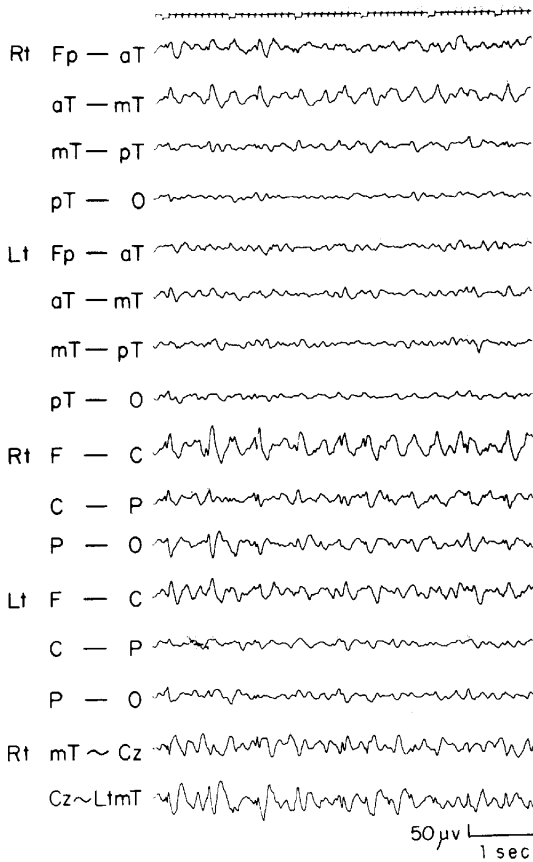


Fig. 3. Electroencephalogram showing a focal low voltage in the left temporal, and focal spikes at the right frontal to central areas.

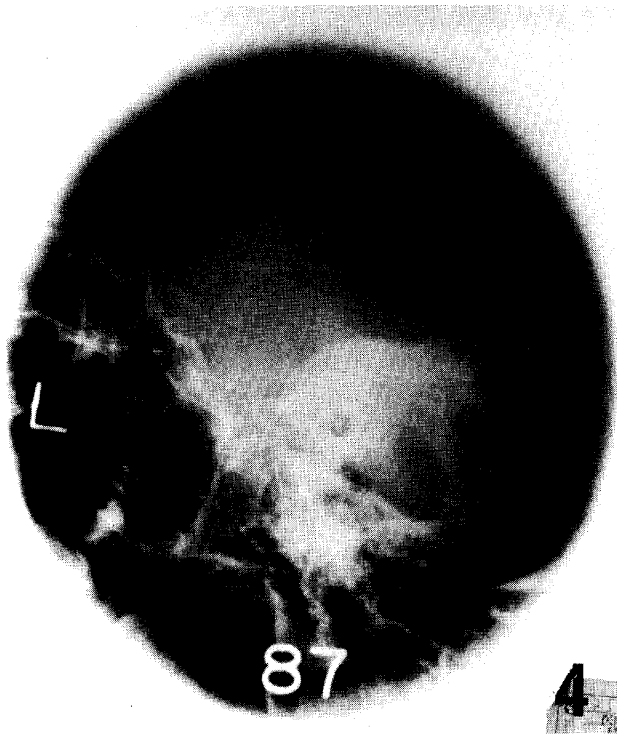


Fig. 4. Schüller's view showing a conspicuous upward swelling of the pyramidal crest.

Fig. 5. Tomography showing almost thorough osseous obstruction of the left external auditory canal and osseous proliferation of the pars petrosa.



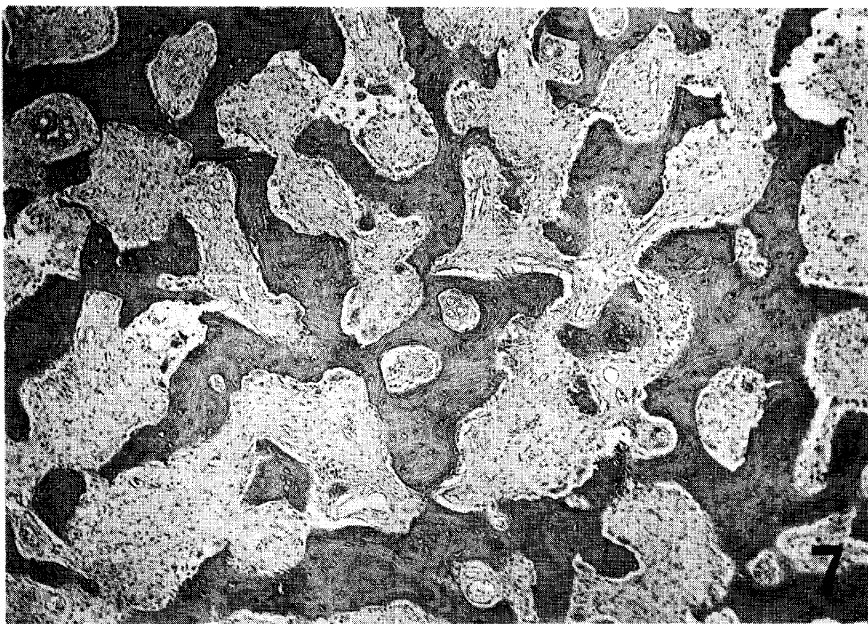
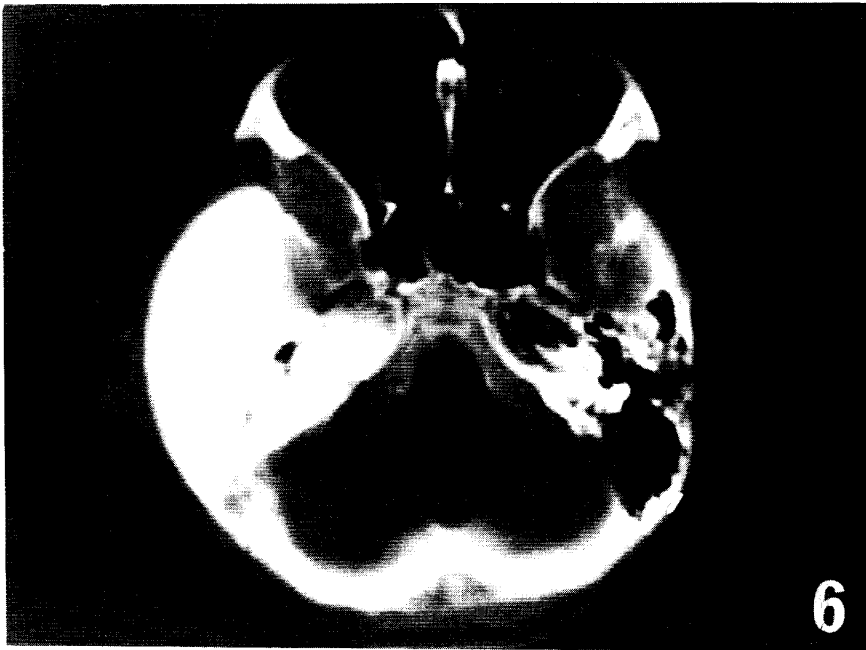


Fig. 6. Computerized tomography showing an abnormal high-density area localized in the left temporal bone.

Fig. 7. Biopsied specimen from the left temporal bone showing irregularly distributed woven bone trabeculae with a dense fibrous component, H.E., $\times 40$.

to either local bone thickening *per se* or to decreased cerebral function caused by brain compression. Focal spikes were noted at the right frontal to central areas; this may be a coincidental finding (Fig. 3).

Roentgenologically, a plain x-ray film, in particular Schüller's view, clearly demonstrated a diffuse shadow in the squama, mastoid process and pyramis; an upward swelling of the pyramidal crest was especially conspicuous (Fig. 4). Tomography showed almost thorough osseous obstruction of the external auditory canal and osseous proliferation of the pars petrosa; this caused deformity of vestibule in the internal ear, obscurity of semicircular canals, high-contrast of osseous shadow of cochlea, and narrowing of internal acoustic meatus (Fig. 5). Computerized tomography presented with an abnormal high-density area which was localized in the left temporal bone and extended towards the middle cranial fossa because of its osseous thickening, although it did not involve the opposite side, *i.e.*, the right cranial fossa (Fig. 6).

A biopsy through the left mastoid process exposed somewhat thinned cortex, and easily-bleeding bone marrow with sherbet-like consistency which was easily curetted. Microscopically, woven bone trabeculae were irregularly distributed throughout the specimen with dense fibrous components; these trabeculae lacked osteoblastic rimming (Fig. 7).

DISCUSSION

The lesion designated as fibrous dysplasia (FD) by Lichtenstein in 1938 (17) had been used under terms variously related; for instance, according to Lichtenstein and Jaffe (18), 33 different kinds of synonyms were listed to express apparently identical disease entities. Although its etiology has not definitely been established, Sussman (5) summarized a few theories hitherto introduced, *i.e.*, congenital anomaly of development, true dystrophy, hormonal disturbance and trauma. Among these, as far as the trauma is concerned, there has been only one case report (3) of trauma four years prior to the occurrence of FD, eight cases denied previous trauma, in their past history, and other reports do not state any clear-cut relationship between trauma and FD.

Monostotic FD localized in the temporal bone manifests variegated disturbances through involvement of surrounding regions because of its anatomical uniqueness. Osseous proliferation involving the external and middle ears results in conductive deafness, which is associated with tinnitus and complicated by cholesteatoma. Progression towards the internal ear will cause gradual destruction of its structure. In our case, roentgenologically, organs of the internal ear and internal acoustic meatus were obviously deformed. Various audiologic examinations also indicate gradual functional disturbance based the affected internal ear.

According to previous reports, the majority of lesions tends to localize in

TABLE 1. MONOSTOTIC FIBROUS DYSPLASIA OF THE TEMPORAL BONE

Informants (Ref. No.)	Year Reported	Age Sex	Affected sites	Period* (yrs)	Loss of hearing (dB)	Cholesteatoma	Treatment	Note
Schlumberger (1)	1946	25, M	Mastoid	12	L.		Curetage	
Sherman & Sternbergh (2)	1948	15, M	Mastoid	"over a period of years"	R. deaf		Curetage	No follow up
Towson (3)	1950	14.5, M	Entire temporal	1	R. 37% loss		Rad. mastoidectomy	1) at 9 y-o, trauma 2) Died of profuse bleeding shortly after operation
Kearney (4)	1959	21, M	Ext. aud. canal	2	R. 30	(+)	Mastoidectomy	Recurrent twice
Sussman (5)	1961	19, F	Ext. aud. canal	3	L. 60		Curetage	
Wong <i>et al.</i> (6)	1965	13, F	Ext. aud. c., squama		R. 35		Biopsy	
Fluur & Söderberg (7)	1966	17, M	Mastoid	1	R. normal		Mastoidectomy	
Basek (8)	1967	40, M	Middle ear	2.5	L. (+)		Operated twice	
Shiffman & Aengst (9)	1967	32, M	Ext. aud. c., mastoid	3	R. 70-80	(+)	Rad. mastoidectomy	
Cohen & Rosenwasser (10)	1969	26, F	Mastoid, squama	18	R. total loss		Rad. mastoidectomy	Recurrent once
<i>ibid.</i>		14, M	Mastoid	5	R. normal		Mastoidectomy	
Tembe (11)	1970	18, M	Ext. aud. canal		R. 65-80		Curetage	
Sharp (12)	1970	27, M	Ext. aud. canal	16	L. 80	(+)	Cleaning of postaural fistula	
<i>ibid.</i>		42, M	Ext. aud. canal	12	L. 50-60	(+)	Mastoidectomy	
Stecker (13)	1971	11, M	Middle ear	2 mos.	R. 60		Curetage	
Mizuno <i>et al.</i> (14)	1972	11, F	Ext. aud. c., mastoid	7	L. 60	(+)	Operated twice	
Chatterji (15)	1974	30, F	Ext. aud. c., mastoid, squama	"many yrs"	L. total loss		Biopsy	
Barrionuevo <i>et al.</i> (16)	1980	11, F	Mastoid	2	R. normal			Dx. based on radiological examination
<i>ibid.</i>		39, M	Mastoid	20	L. 60	(+)	Mastoidectomy	Complicated extradural abscess
<i>ibid.</i>		3, F	Mastoid	2	L.			Associated with Albright's syndrome

* Period before consultation. Dx: Diagnosis.

either the external auditory canal, the mastoid process, or middle ear (Table 1), and even the whole temporal bone is affected in a few reports (13, 15). Fernandez *et al.* (19) reported a case, in which the lesion spread to the entire skull base and caused disturbances related to the cranial nerves. In the present case, upward osseous swelling of the tegmen in addition to deformity of the external auditory canal, middle and internal ears and internal acoustic meatus suggested the disturbance of the central nervous system due to a deformed middle cranial fossa.

Fries (20) referred two cases with FD which were associated with schizophrenia. In these cases, the lesion involved the frontal and sphenoidal bones; the extension might have affected the frontal lobe to complicate the schizophrenia. Our case started developing epilepsy by the time when the patient's mother noticed the left temporal swelling. The epileptic focus was, however, apparently located superficially in the frontal to central lobes of the opposite, *i.e.*, right side. Therefore, the association of FD and epilepsy may be a coincidental finding, although the occurrence of the epilepsy as a complication of FD can not be ruled out. At any rate, we would like to emphasize the rarity of FD associated with epilepsy; in fact, to our knowledge, there have been no such cases reported previously. The possibility of recurrence by stopping anti-epileptic drugs, even though well under control, and changing patterns of electroencephalograms should help clarify the relationship between FD and epilepsy.

Roentgenology contributes largely to the range of extension of FD inside the temporal bone. Based on the characteristics of shadow density, Fries (20) subclassified FD into three types, *i.e.*, pagetoid, sclerotic and cyst-like, and Leeds and Seaman (21) differentiated FD from other lesions, in particular, meningioma. As to computerized tomography scanning, there is only one report by Fernandez *et al.* (19), in which scanning was used to diagnose FD. The scanning will help give more precise information on various otologic disorders and temporal FD.

Serum Ca, P and alkaline and acid phosphatases are said to be elevated in some patients with monostotic FD. However, the majority of patients including our case are within the normal range; therefore, these electrolytes or phosphatases can not be reliable parameters for the monostotic type of FD.

A complication of temporal FD, *i.e.*, formation of cholesteatoma (Table 1), is mainly subsequent to squamous cell proliferation and accumulation due to obstruction of the external auditory canal; the cholesteatoma is formed even after radical surgery. The radical surgery before reaching the age, when FD ceases to grow further, is considered to accelerate recurrences. The cases with the recurrence, however, have been rather scarce, probably because the follow-up period was too short; one case was operated on three times by Kearney (4), and one case each by Basek (8) and Mizno *et al.* (14) who performed operations twice.

The present case may expect cholesteatoma formation because of osseous

obstruction throughout the external auditory canal, and may necessitate surgery in future for prevention of the cholesteatoma formation and for improvement of hearing. It is, however, rather difficult to improve the hearing depending on the degree of infiltration by FD into the internal ear and internal acoustic meatus. Surgical intervention for the purpose of relieving intracranial pressure may have a large risk, and should be scheduled according to the state of patient's epilepsy.

Acknowledgment. Authors are deeply indebted to Dr. Y. Yamatogi, Department of Pediatrics, Okayama University Medical School, for her interpretation and invaluable advice concerning electroencephalography. Our thanks are also due to Prof. Y. Ogura, Head, Department of Otorhinolaryngology, for his constant encouragement throughout the study on the present case.

REFERENCES

- Schlumberger, H.G.: Fibrous dysplasia of single bones (Monostotic fibrous dysplasia). *Milit. Surgeon* **99**, 504-527, 1946.
- Sherman, R.S. and Sternbergh, W.C.A.: The roentgen appearance of ossifying fibroma of bone. *Radiology* **50**, 595-609, 1948.
- Towson, C.E.: Monostotic fibrous dysplasia of the mastoid and the temporal bone. *Arch. Otolaryngol.* **52**, 709-724, 1950.
- Kearney, H.L.: Fibrous dysplasia of the temporal bone. *Laryngoscope* **69**, 571-574, 1959.
- Sussman, H.B.: Monostotic fibrous dysplasia of the temporal bone. Report of a case. *Laryngoscope* **71**, 68-77, 1961.
- Wong, A., Vaughan, C.W. and Strong, M.S.: Fibrous dysplasia of temporal bone. *Arch. Otolaryngol.* **81**, 131-133, 1965.
- Fluur, E. and Söderberg, G.: Monostotic fibrous dysplasia (ossifying fibroma) of the mastoid. *J. Laryngol. Otol.* **80**, 678-685, 1966.
- Basek, M.: Fibrous dysplasia of the middle ear. *Arch. Otolaryngol.* **85**, 4-7, 1967.
- Shiffman, F. and Aengst, F.E.: Fibrous dysplasia of temporal bone. *Arch. Otolaryngol.* **86**, 528-534, 1967.
- Cohen, A. and Rosenwasser, H.: Fibrous dysplasia of the temporal bone. *Arch. Otolaryngol.* **89**, 447-459, 1969.
- Tembe, D.: Fibro-osseous dysplasia of temporal bone. *J. Laryngol. Otol.* **84**, 107-114, 1970.
- Sharp, M.: Monostotic fibrous dysplasia of the temporal bone. *J. Laryngol. Otol.* **84**, 697-708, 1970.
- Stecker, R.H.: Ossifying fibroma of the middle ear. Report of a case. *Arch. Otolaryngol.* **94**, 80-82, 1971.
- Mizuno, M., Funasaka, S., Abe, H. and Kobayashi, T.: Monostotic fibrous dysplasia of the temporal bone. *Jibi-Inko* **44**, 15-20, 1972 (in Japanese).
- Chatterji, P.: Massive fibrous dysplasia of the temporal bone. *J. Laryngol. Otol.* **88**, 179-183, 1974.
- Barrionuevo, C.E., Marçallo, F.A., Coelho, A., Cruz, G.A., Mocellin, M. and Patrocínio, J.A.: Fibrous dysplasia and the temporal bone. *Arch. Otolaryngol.* **106**, 298-301, 1980.
- Lichtenstein, L.: Polyostotic fibrous dysplasia. *Arch. Surg.* **36**, 874-898, 1938.
- Lichtenstein, L. and Jaffe, H.L.: Fibrous dysplasia of bone. *Arch. Pathol.* **33**, 777-816, 1942.

19. Fernandez, E., Colavita, N., Moschini, M. and Fileni, A.: "Fibrous dysplasia" of the skull with complete unilateral cranial nerve involvement. Case report. *J. Neurosurg.* **52**, 404-406, 1980.
20. Fries, J.W.: The roentgen features of fibrous dysplasia of the skull and facial bones. A critical analysis of thirty-nine pathologically proved cases. *Am. J. Roentgenol.* **77**, 71-88, 1957.
21. Leeds, N. and Seaman, Wm.B.: Fibrous dysplasia of the skull and its differential diagnosis. A clinical and roengenographic study of 46 cases. *Radiology* **78**, 570-582, 1962.