

Acta Medica Okayama

Volume 36, Issue 6

1982

Article 6

DECEMBER 1982

Two-Dimensional Echo-cardiographic Estimation of the Size of the Mitral Valve Annulus

Masaharu Shigenobu*

Yoshimasa Senoo†

Shigeru Teramoto‡

*Okayama University,

†Okayama University,

‡Okayama University,

Two-Dimensional Echo-cardiographic Estimation of the Size of the Mitral Valve Annulus*

Masaharu Shigenobu, Yoshimasa Senoo, and Shigeru Teramoto

Abstract

The diameter of the mitral annulus as measured on the long axis by two-dimensional echocardiogram was found to correlate well with the size of the sewing ring used to replace the mitral valve in 35 consecutive patients. The size of the prosthesis which was used could be predicted within 1 mm of error in 83% of the mitral stenosis (MS) patients and in 76% of the mitral regurgitation (MR) patients in the study. Preoperative echocardiographic estimation of the size of the mitral valve annulus and prediction of the sewing ring size of the prosthetic valve used could reduce the incidence of valve prosthesis-patient mismatch.

KEYWORDS: mitral valve replacement, valve prosthesis-patient mismatch, two-dimensional echocardiography, predictin the mitral valve size

TWO-DIMENSIONAL ECHOCARDIOGRAPHIC ESTIMATION OF THE SIZE OF THE MITRAL VALVE ANNULUS

Masaharu SHIGENOBU, Yoshimasa SENOO and Shigeru TERAMOTO

Second Department of Surgery, Okayama University Medical School, Okayama 700, Japan

Received May 11, 1982

Abstract. The diameter of the mitral annulus as measured on the long axis by two-dimensional echocardiogram was found to correlate well with the size of the sewing ring used to replace the mitral valve in 35 consecutive patients. The size of the prosthesis which was used could be predicted within 1 mm of error in 83% of the mitral stenosis (MS) patients and in 76% of the mitral regurgitation (MR) patients in the study. Preoperative echocardiographic estimation of the size of the mitral valve annulus and prediction of the sewing ring size of the prosthetic valve used could reduce the incidence of valve prosthesis-patient mismatch.

Key words: mitral valve replacement, valve prosthesis-patient mismatch, two-dimensional echocardiography, , predicting the mitral valve size.

It is clear that valve replacement has been the most important advance in the last 20 years for the treatment of patients with mitral valve disease and has enabled many patients to lead a more active and useful life (1). It has reached the stage when most patients with mitral valve disease should be considered potential candidates for surgery.

The problem of prosthetic valve-patient mismatch (2-3) has recently been emphasized. This problem is one of the factors influencing the prognosis of patients undergoing mitral valve replacement.

The purpose of the present study is to determine the diameter of the mitral valve annulus by two-dimensional echocardiogram and to predict preoperatively the size of the valve prosthesis to be used to replace the mitral valve.

MATERIALS AND METHODS

This retrospective study was performed in 35 consecutive patients with mitral stenosis (MS) or mitral regurgitation (MR) who underwent mitral valve replacement to determine whether the size of the sewing ring could be predicted within useful limits.

Eighteen patients (average age 43 years old, 10 females and 8 males) had MS, and 17 patients (average age 48 years old, 9 females and 8 males) MR.

Each had satisfactory preoperative echocardiogram. The size of the mitral valve annulus was measured on the long axis projection of the two-dimensional echocardiogram at both endsystolic and enddiastolic phases (Fig. 1).

The valve prostheses used to replace the diseased mitral valve were Björk-Shiley valve in 32 patients, Ionescu-Shiley pericardial valve in 2 patients and Carpentier-Edwards porcine

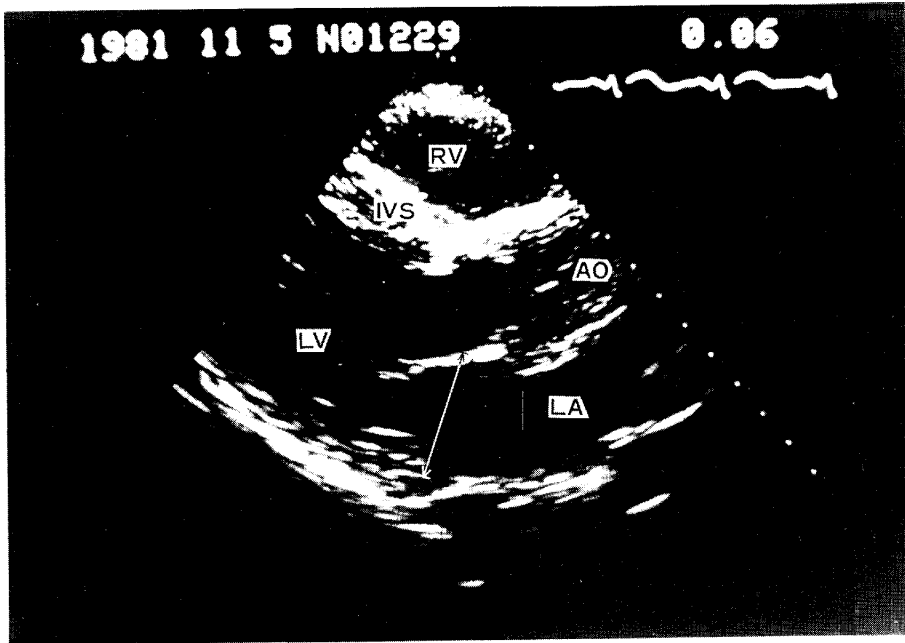


Fig. 1. This figure shows the method used to measure the mitral annulus diameter (The arrow). AO: Aorta, LA: Left atrium, LV: Left ventricle, RV: Right ventricle, IVS: Interventricular septum.

TABLE I. CHARACTERISTICS OF 35 PATIENTS UNDERGOING MITRAL VALVE REPLACEMENT

| | MS | MR |
|----------------------------|----|----|
| Age (mean) | 43 | 48 |
| Sex | | |
| Male | 8 | 8 |
| Female | 10 | 9 |
| Cause of valve disease | | |
| Rheumatic | 18 | 0 |
| Degenerative | 0 | 14 |
| Miscellaneous | 0 | 3 |
| Mitral valve calcification | | |
| None | 0 | 17 |
| Mild | 0 | 0 |
| Moderate | 15 | 0 |
| Severe | 3 | 0 |
| Valve prosthesis used | | |
| Björk-Shiley | 17 | 15 |
| Ionescu-Shiley | 1 | 1 |
| Carpentier-Edwards | 0 | 1 |

MS: Mitral stenosis, MR: Mitral regurgitation

valve in one patient (Table 1). The size of the prosthesis was selected by measuring the mitral annulus diameter during operation.

The comparison of two-dimensional echocardiographic annulus diameter to actual prosthesis diameter was retrospectively performed to find the correlation between the two.

RESULTS

Characteristics of the 35 patients undergoing annulus sizing are shown in Table 1.

The comparison of predicted valve size to actual prosthetic valve size is shown in Fig. 2. The overall correlation coefficient (r value) was 0.81 when the endsystolic frame was used.

The mean value of the actual prosthesis diameter was 27.7 mm in 35 patients. The two-dimensional echocardiographic annulus diameter (mean) was 29.8 mm at the endsystolic frame and 33.6 mm at the enddiastolic frame (Table 2), so that the average discrepancy between the actual prosthesis size and echo-

TABLE 2. TWO-DIMENSIONAL ECHOCARDIOGRAPHIC MITRAL ANNULUS DIAMETER AND THE ACTUAL PROSTHESIS DIAMETER

| | Actual prosthesis diameter (mean) (mm) | Two-dimensional echocardiographic annulus diameter (mean) | |
|-----------------|--|---|-------------------------|
| | | Endsystolic frame (mm) | Enddiastolic frame (mm) |
| Total (35 pts.) | 27.7 ± 1.9 | 29.8 ± 2.2 | 33.6 ± 2.8 |
| MS (18 pts.) | 27.3 ± 1.8 | 29.9 ± 2.4 | 33.1 ± 2.7 |
| MR (17 pts.) | 28.1 ± 1.8 | 30.4 ± 2.2 | 33.6 ± 2.5 |

MS: Mitral stenosis, MR: Mitral regurgitation, pts.: Patients

graphic diameter was 2.1 mm at the endsystolic frame and 5.9 mm at the enddiastolic frame. Therefore, the actual size of the valve prosthesis was predicted by subtracting 2.1 mm or 5.9 mm (at endsystolic or enddiastolic phase respectively) from the echographically determined diameter.

In the MS group, the average actual prosthesis diameter was 27.3 mm. Two-dimensional echocardiographic annulus diameter was 29.9 mm at the endsystolic phase and 33.1 mm at the enddiastolic phase (Table 2). The comparison of the predicted valve size to actual valve size is shown in Fig. 2. In 15 of 18 (83%) patients, the size of the prosthetic valve was predicted within 1 mm of error.

Analysis of predictive accuracy with endsystolic frames, or enddiastolic frames in the MS group disclosed correlation coefficients (r values) of 0.86 and 0.76, respectively.

In the MR group, the mean actual prosthesis diameter was 28.1 mm.

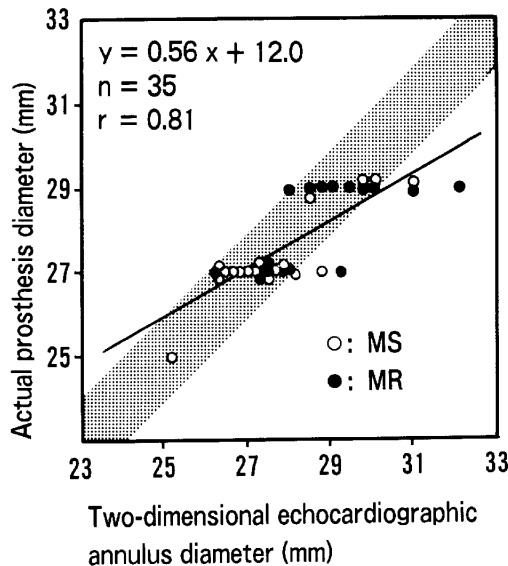


Fig. 2. Comparison of two-dimensional echocardiographic annulus diameter at endsystolic frame to actual prosthesis diameter in all patients. The shaded part shows the area within 1 mm of the error.

(MS: $y = 0.60x + 10.8$, $n = 18$, $r = 0.86$, MR: $y = 0.48x + 14.4$, $n = 17$, $r = 0.71$)

Echographically determined diameter (mean) was 30.4 mm at the endsystolic frame and 33.6 mm at the enddiastolic frame (Table 2). Since respective correlation coefficients at endsystole or enddiastole were 0.71 and 0.64, it appears that the endsystolic phase is better than the enddiastolic phase for predicting the prosthetic mitral valve size before operation.

The comparison of predicted valve size to actual valve size at the endsystolic frame is shown in Fig. 2. In 13 of 17 (76%) patients with MR, the size of the valve prosthesis used could be predicted within 1 mm of error.

DISCUSSION

Several substitute valves are now available to replace the diseased mitral valve, namely the disc valve, leaflet valve and bioprosthetic valve. The variety of prostheses available points to the imperfections of all existing designs. Each current type of prosthesis has advantages and disadvantages.

The problem of valve prosthesis-patient mismatch has recently been emphasized. It is a fact that some patients do not have any improvement in quality of life because of this mismatch and even die after surgery.

Determination of the size of prosthesis to insert, to our knowledge, has always been made in the operating room with the patient on cardiopulmonary bypass and after the insertion of various sizes through the valve orifice after

excision of the native valve. With the patient on cardiopulmonary bypass and with various retractors pulling on the heart, the surgeon may be able to insert a larger sized devices than would be possible when the patient off cardiopulmonary bypass and all retractors withdrawn, when the valve orifice is much smaller. Furthermore, the heart is arrested in the diastolic state during valve replacement by cardioplegic solution which recently is used at almost all institutes to protect the myocardium. The myocardium becomes flaccid by cold cardioplegia, so the native valve orifice will be larger than when the heart is beating.

Too large a prosthetic valve leads to various complications especially in small patients with mitral stenosis. For this reason, the decision regarding the size of prosthesis to insert should be determined preoperatively whenever possible and based on the hemodynamic valve lesions, body weight or body surface area and not entirely on the dimensions in the operating room.

Selection of a mitral valve prosthesis presented few problems when the choice was limited. With the recent development of acceptable new valve prostheses, the heart surgeon has a valid choice of valves for a given patient. However, the ideal substitute valve is still not available today, or if available, not adequately enough tested. The surgeon, therefore, sometimes has difficulties in the selection of the most favorable valve prosthesis for the patient. This has generated recent interest in valve prosthesis-patient mismatch, wherein valve replacement leaves a patient with some troubles in the long-term follow-up period.

This report describes the technique of determining valve size from two-dimensional echocardiogram taken in the long axis projection. The accuracy and clinical application of this method are retrospectively evaluated.

The average discrepancy between the echographically determined annulus diameter and the outer diameter of the sewing ring actually used was 2.1 mm at the endsystolic frame and 5.9 mm at the enddiastolic frame. One of the causes of this discrepancy may rest in the fact that a part of the mitral leaflet is left to protect the annulus when the valve is excised for valve replacement. Another cause is that prosthesis somewhat smaller than the actual annulus diameter has been used to replace the native valve at our institute.

Therefore, when predicting the valve size to be used, this discrepancy was adjusted by subtracting the mean difference as described previously from the echographically determined diameter.

In both groups (MS and MR), plots of actual versus predicted size revealed better concordance when the endsystolic frames were used as compared to the enddiastolic frames.

In 15 of 18 (83%) patients with MS, the size of the prosthetic valve could be predicted within 1 mm of error. However, the remaining 3 patients whose mitral valve was severely calcified, showed significant discrepancy.

The margin of the mitral leaflet becomes obscure on two-dimensional echocardiogram because the intensity of the silhouette is increased by calcification. It was found that the presence of heavy calcification of the leaflet increased the error.

On the contrary, no calcification was detected in the MR group, so that the annular diameter could be more easily measured.

All patients being taken into consideration, the actual prosthetic valve size could be determined in 28 of 35 (80%) patients, when the long-axis measurement was used.

We conclude that two-dimensional echocardiogram is a useful tool to predict the valve size which in turn can facilitate the appropriate preoperative selection of valve type.

REFERENCES

1. Kirklin, J.W. and Pacifico, A.D.: Surgery for acquired valvular heart disease. *N. Engl. J. Med.* **288**, 133-145, 1973.
2. Rahimtoola, S.H.: The problem of valve prosthesis-patient mismatch. *Circulation* **58**, 20, 1978.
3. Rahimtoola, S.H. and Murphy, E.: Valve prosthesis-patient mismatch, A long-term sequela. *Br. Heart J.* **45**, 331, 1981.