

Acta Medica Okayama

Volume 34, Issue 2

1980

Article 6

APRIL 1980

Demonstration of immunoglobulin G in normal human epidermis by peroxidase-labeled antibody.

Mariko Yamada*

Yasuko Hida†

Nozomi Nohara‡

*Okayama University,

†Okayama University,

‡Okayama University,

Demonstration of immunoglobulin G in normal human epidermis by peroxidase-labeled antibody.*

Mariko Yamada, Yasuko Hida, and Nozomi Nohara

Abstract

Cytoplasmic immunoglobulin G (IgG) in normal human epidermis was defined by a peroxidase-labeled antibody method. A correlation between cytoplasmic staining and the serum level of IgG was found. Epidermal cells containing IgG were not present when the serum level of IgG was less than 1000 microgram/ml.

KEYWORDS: immunoglobulin G, peroxidase-labeled antibody method, normal human epidermis.

*PMID: 6450514 [PubMed - indexed for MEDLINE]

Copyright (C) OKAYAMA UNIVERSITY MEDICAL SCHOOL

Acta Med. Okayama **34**, (2), 123—126 (1980)

— BRIEF NOTE —

**DEMONSTRATION OF IMMUNOGLOBULIN G IN
NORMAL HUMAN EPIDERMIS BY PEROXIDASE-
LABELED ANTIBODY**

Mariko YAMADA, Yasuko HIDA and Nozomi NOHARA

*Department of Dermatology, Okayama University Medical School,
Okayama 700, Japan (Director: Prof. N. Nohara)*

Received December 11, 1979

Abstract. Cytoplasmic immunoglobulin G (IgG) in normal human epidermis was defined by a peroxidase-labeled antibody method. A correlation between cytoplasmic staining and the serum level of IgG was found. Epidermal cells containing IgG were not present when the serum level of IgG was less than 1000 $\mu\text{g/ml}$.

Key words: immunoglobulin G, peroxidase-labeled antibody method, normal human epidermis.

The localization of immunoglobulins in pathological skin has been reported in detail (1), Immunoglobulins in normal human skin, however, has not been evaluated finely, although in some papers, immunoglobulins have been demonstrated in the dermis of normal skin but not in the epidermis (2-6). In this paper, we describe the cytoplasmic staining of IgG in normal human epidermis using peroxidase-labeled antibody (7-9) and the correlation between cytoplasmic staining in the epidermis and IgG levels in the serum.

Materials and methods. Normal skin obtained from 17 persons (14 adults and 3 children) were used for this study. The specimens were fixed with a periodate-lysine-paraformaldehyde (PLP) fixative (7) and were embedded in an Ames O. C. T. compound. The frozen sections were washed in PBS, incubated with horseradish peroxidase-labeled anti-human IgG (Fab') (8, 9), washed, reacted with diaminobenzidineperoxide, washed again, dehydrated, then mounted. Controls included staining by the conjugate absorbed with purified IgG and replacement of the conjugate with PBS for the evaluation of endogenous peroxidase activity. Serum immunoglobulin levels were determined by radial immunodiffusion using commercial plates (Hyland).

Results. Characteristic staining of IgG was observed in the epidermis of eleven of seventeen normal skins. Fine granular staining was located in the cytoplasm of some epidermal cells from the prickel layer to granular layer in a scattered or clustered form (Figs. 1, 2, 3a). In the nuclei of these cells, no specific

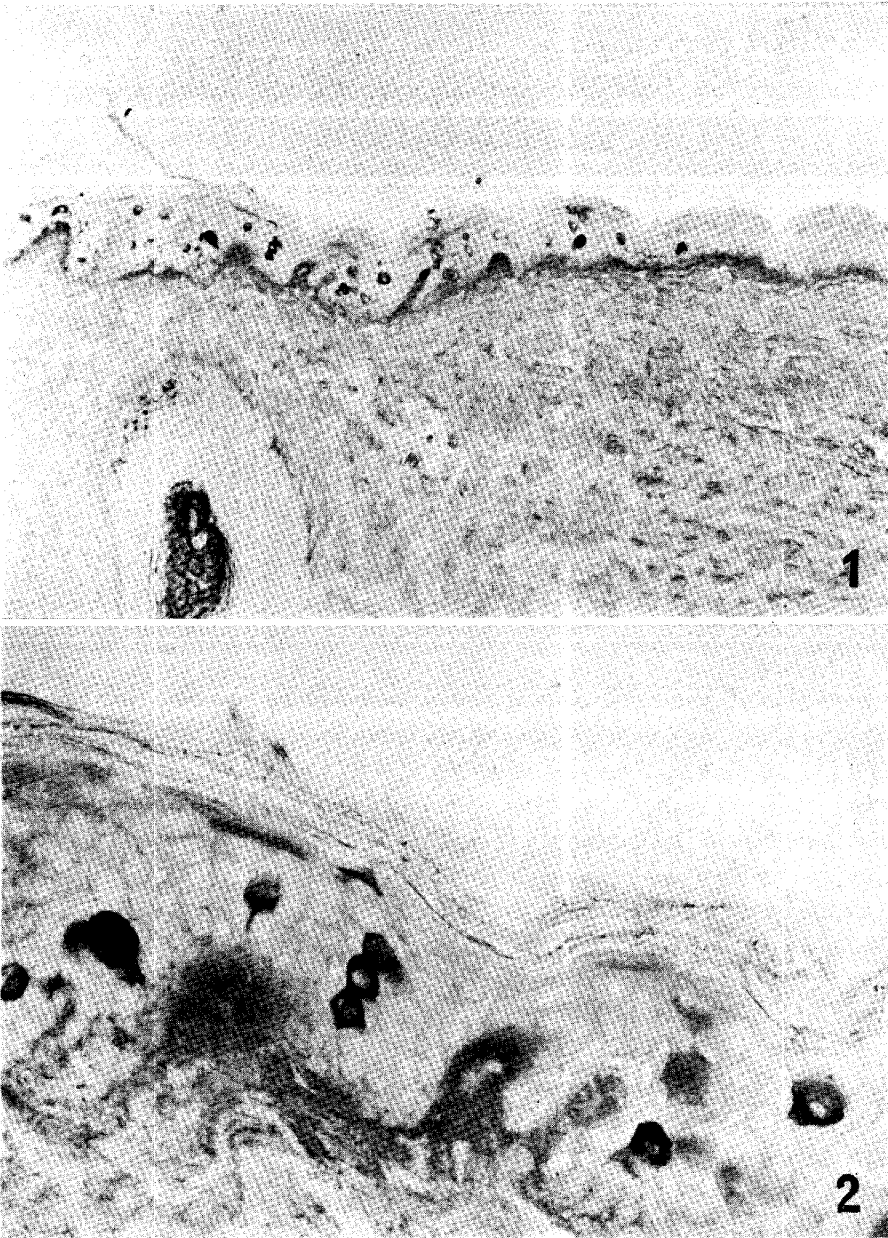


Fig. 1. IgG reaction products in some epidermal cells. Light reaction products are diffusely present in the dermis. $\times 100$.

Fig. 2. Higher magnification of Fig. 1. IgG reaction products in the cytoplasm of several epidermal cells. Nuclei are not stained. $\times 400$.

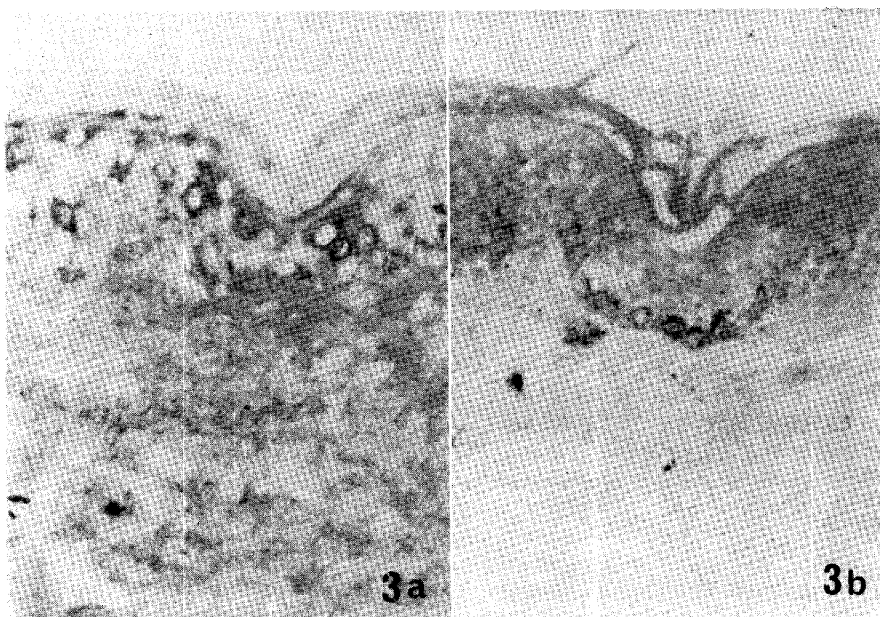


Fig. 3. Localization of IgG in epidermal cells. a, Many epidermal cells containing cytoplasmic IgG in another case. $\times 250$. b, Cytoplasmic IgG in epidermal cells was completely abolished by absorbed conjugates. Staining of basal layer is melanin granules. $\times 250$.

staining was found. Such cytoplasmic staining appeared only in cases with more than $1.00 \mu\text{g/ml}$ of IgG in the serum, and was not found in three adults and three children with hypogammaglobulinemia (below $10.0 \mu\text{g/ml}$). In one case with a high level of gammaglobulin ($280 \mu\text{g/ml}$), linear localization of intercellular IgG was found with epidermal cytoplasmic staining. In the dermis, IgG was diffusely observed in all cases in agreement with other papers (2-6, 10). In controls using absorbed conjugates, specific staining of IgG was completely absent (Fig. 3b).

Discussion. The distribution of immunoglobulins in pathological skin has been well studied by many researchers using immunohistochemical techniques (1). In most of these papers, however, immunoglobulins were not found in the epidermis of normal skin examined as the control (2-6). In a few papers immunoglobulins were observed focally in the epidermis by immunofluorescent methods (10-12), but they were not accurately localized. In our study, IgG was definitely demonstrated in the cytoplasm of epidermal cells. This was probably because of the fixative, which is excellent for preserving immunoglobulins in the tissue, and because of the weak background staining by Nakane's method (8, 9), compared to the previous studies. We also found a correlation between epider-

mal IgG and serum levels. Epidermal IgG may play a role in defence mechanisms of the skin (13, 14). It remains to be evaluated whether the cytoplasmic IgG of epidermal cells is present as a result of synthesis or phagocytosis of IgG (15, 16). Further ultrastructural studies will clarify the precise localization of IgG in the cytoplasm and also give the suggestion for the origin of it.

Acknowledgment. We wish to express profound thanks to Prof. P. K. Nakane of the Department of Pathology, University of Colorado for his guidance and assistance throughout this work.

REFERENCES

1. Cooperative Study: Uses for immunofluorescence tests of skin and sera. Utilization of immunofluorescence in the diagnosis of bullous disease, lupus erythematosus, and certain other dermatoses. *Arch. Dermatol.* **111**, 371-381, 1975.
2. Cormane, R. H., Szabo, E. and Hauge, L. S.: Immunofluorescence of the skin. The interpretation of the staining of blood vessels and connective tissue aided by new techniques. *Br. J. Dermatol., Suppl.* **5**, 26-43, 1970.
3. Ueki, H.: Clinical significance of immunoglobulins in the skin. In *Guideline of Dermatology in Future, Modern Medical Series.* '71-'72, Kanahara Co., Tokyo, pp. 47-69, 1971.
4. Ueki, H., Wolff, H. H. and Braun-Falco, O.: Cutaneous localization of human gamma-globulins in lupus erythematosus. An electronmicroscopical study using peroxidase-labeled antibody technique. *Arch. Dermatol. Forsch.* **248**, 297-314, 1974.
5. Welbourn, E., Champion, R. H. and Parish, W. E.: Hypersensitivity to bacteria in eczema. I. Bacterial culture, skin tests and immunofluorescent detection of immunoglobulins and bacterial antigens. *Br. J. Dermatol.* **94**, 619-632, 1976.
6. Hodgkinson, G. I., Everall, J. D. and Smith, H. V.: Immunofluorescent patterns in the skin in the Besnier's prurigo. The eczema syndrome. *Br. J. Dermatol.* **96**, 357-366, 1977.
7. MacLean, I. W. and Nakane, P. K.: Periodate-lysine-paraformaldehyde fixative, a new method for immunoelectron microscopy. *J. Histochem. Cytochem.* **22**, 1077-1083, 1974.
8. Nakane, P. K.: Localization of hormones with the peroxidase-labeled antibody method. *Methods Enzymol.* **37**, 133-144, 1975.
9. Nakane, P. K. and Kawaoi, A.: Peroxidase-labeled antibody. A new method of conjugation. *J. Histochem. Cytochem.* **22**, 1084-1091, 1974.
10. Allansmith, M., Goham-Yahr, M. and Buell, D. N.: Demonstration of gamma-2 globulin in human skin. *J. Allergy* **35**, 313-321, 1964.
11. Ueki, H.: The application of the fluorescent antibody technique in dermatology. 1. Localization of tissue bound-globulin in the skin lesions. *Jpn. J. Dermatol.* **77**, 45-51, 1967 (in Japanese).
12. Beno, M. and Erlinda, K. S.: *Immunopathology of the Skin. Labeled Antibody Studies.* Dowden, Hutchinson and Ross Inc, Pennsylvania, pp. 182-193, 1973.
13. Page, C. O. Jr. and Remington, J. S.: Immunologic studies in human sweat. *J. Lab. Clin. Med.* **69**, 634-650, 1967.
14. Baba, E. and Yasue, T.: A statistical observation on impetigo in recent 7 years' duration. *Jpn. J. Clin. Dermatol.* **33**, 715-719, 1979 (in Japanese).
15. Lai A Fat, R. F. M., Suurmond, D. and Van Furth, R.: *In vitro* synthesis of immunoglobulins, secretory component and complement in normal and pathological skin and the adjacent mucous membranes. *Clin. Exp. Immunol.* **14**, 377-395, 1973.
16. Lai A Fat, R. F. M., Cormane, R. H. and Van Furth, R.: An immunohistopathological study on the synthesis of immunoglobulins and complement in normal and pathological skin and the adjacent mucous membranes. *Br. J. Dermatol.* **90**, 123-126, 1974.